



UNIVERSITI PUTRA MALAYSIA

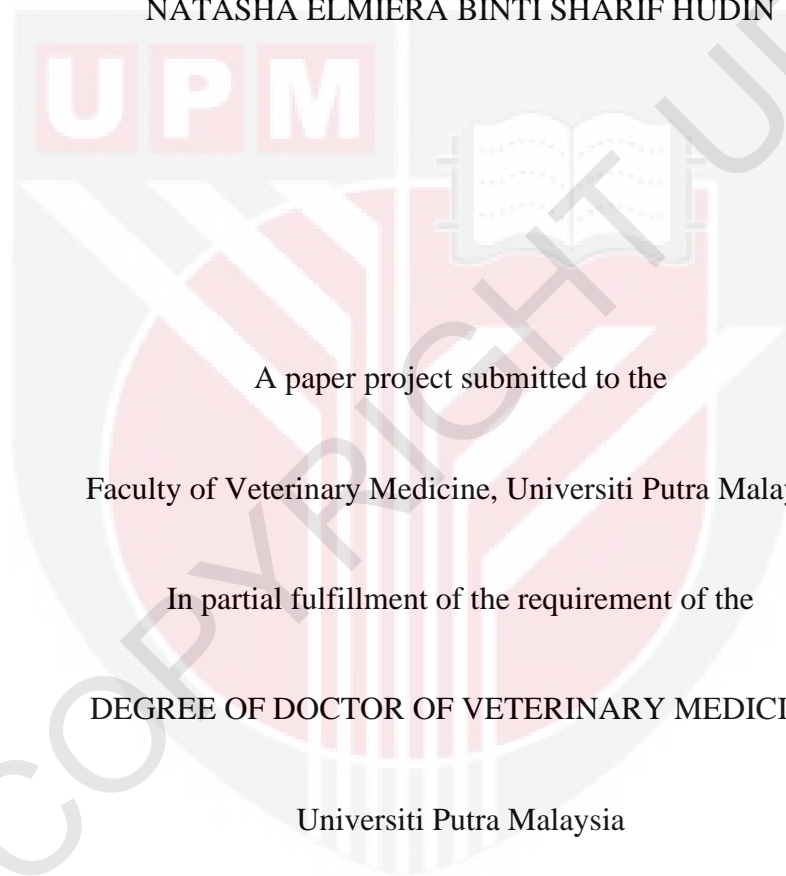
**DETECTION AND IDENTIFICATION OF ECTOPARASITES AND
ENDOPARASITE OF WATERBIRDS IN PUTRAJAYA WETLANDS PARK**

NATASHA ELMIERA BINTI SHARIF HUDIN

**Ip
FPV 2022 60**

**DETECTION AND IDENTIFICATION OF ECTOPARASITES AND
ENDOPARASITE OF WATERBIRDS IN PUTRAJAYA WETLANDS PARK**

NATASHA ELMIERA BINTI SHARIF HUDIN



A paper project submitted to the

Faculty of Veterinary Medicine, Universiti Putra Malaysia

In partial fulfillment of the requirement of the

DEGREE OF DOCTOR OF VETERINARY MEDICINE

Universiti Putra Malaysia

Serdang, Selangor Darul Ehsan

DECEMBER 2022

CERTIFICATION

It is hereby certificate that I have read this project paper entitled “Detection and Identification of Ectoparasites and Endoparasites of Waterbirds in Putrajaya Wetland Park” by Natasha Elmiera Binti Sharif Hudin and in my opinion is satisfactory in terms of scope, quality and presentation as partial fulfilment of the requirement for the course VPD 499 – Final Year Project.

.....
PROF. DR. JALILA BINTI ABU

DVM, MSc, PHD (UPM)

Professor,

Department of Veterinary Clinical Studies

Faculty of Veterinary Medicine

Universiti Putra Malaysia (UPM)

(Supervisor)

.....

DR. NOR AZLINA ABDUL AZIZ

DVM, MSc, PHD (UPM)

Lecturer,

Department of Veterinary Pathology and Microbiology

Faculty of Veterinary Medicine

Universiti Putra Malaysia (UPM)

(Co- Supervisor)

DEDICATION

My humble effort I dedicated to my parents; Sharif Hudin Bin Mohd Nor and Haslina Binti Sahrom, my siblings as well as my friends for their love, motivation and prayers, supporting me endlessly to reach at this level. We have finally made it!



ACKNOWLEDGEMENT

I would like to acknowledge and give my warmest thanks to my supervisor, Prof Dr. Jalila Binti Abu and my co-supervisor, Dr. Azlina Binti Abd Aziz who made this work possible. Their guidance and advice carried me through all the stages of writing my project. I would also like to thank the Putrajaya Wetlands Park committee members for letting my research with the waterbirds to be an enjoyable moment. To Madam Maizatul and Mr. Rashid from the Parasitology Lab, it has been an absolute treat working alongside both of you, discussing the findings, especially during the searching of parasites eggs under the microscopes for hours! Thank you for guiding me.

Well, none of this would have mattered or ever have been possible if it wasn't for my family; my parents and my siblings. From giving me the freedom to dream big and supporting me every step of the way throughout this journey. To put it simply, I would not be here typing an acknowledgment to my FYP thesis if it wasn't for my parents. Your prayer for me was what sustained me this far.

For my batchmates, DVM 2023; we have indeed come a long way, haven't we! You have been instrumental in making me a better and mentally stronger person. Thank you all for being there. And oh! How could I ever forget to thanks to my cats; Donut and Omei for keeping me sane through the horrors' of FYP! And lastly, for Oreo and Oyem; I believed that both of you must be really proud of me from afar (in heaven) and thank you as always.

TABLE OF CONTENTS

TITLE	i
CERTIFICATION	ii
DEDICATION	iii
ACKNOWLEDGEMENT	v
LIST OF TABLES	viii
LIST OF FIGURES	ix
ABSTRAK	x
ABSTRACT	xii
CHAPTER 1	1
INTRODUCTION	1
CHAPTER 2	3
LITERATURE REVIEW	3
2.1 Ectoparasites of waterbirds	3
2.1.1 Arachnida (Mites)	3
2.1.2 Insecta (Lice)	4
2.2 Gastrointestinal parasites of waterbirds	5
2.2.1 Protozoan	5
2.2.2 Helminths	6
2.3 Studies of ectoparasites and endoparasites of waterbirds in Malaysia	7
2.4 The importance of parasites in birds	8
CHAPTER 3	10
METHODOLOGY	10
3.1 Sampling area	10
3.2 Animal	10
3.3 Sampling method	11
3.3.1 Ectoparasite collection	11
3.3.2 Hoyer's Medium mounting technique for mites and lice identification	12
3.3.3 Gastrointestinal parasite collection	12
3.3.4 Direct wet mount and faecal floatation technique	13
3.3.5 Parasite eggs and oocyst identification	14
3.4 Data analysis	14

CHAPTER 4	15
RESULTS	15
4.1 Ectoparasites	15
4.1.1 Feather samples	17
4.1.2 Cotton swabs	18
4.2 Endoparasites	19
CHAPTER 5	22
DISCUSSION	22
5.1 Ectoparasites	22
5.2 Gastrointestinal parasites	23
CHAPTER 6	25
CONCLUSION	25
CHAPTER 7	26
RECOMMENDATION	26
REFERENCES	27

LIST OF TABLES

Table	Caption	Page
1	Species distribution for sample collection	11
2	Overall detection and occurrence of ectoparasites in both water birds' species in Wetland Park, Putrajaya (N=30)	16
3	Overall endoparasite species occurrence in both water birds' species in Wetland Park, Putrajaya (N=30)	20



LIST OF FIGURES

Figures	Caption	Page
1	Quarantine area of the waterbirds	11
2	Egyptian Goose and Mixed Local Ducks in the housing area within the quarantine zone	11
3	Egyptian Goose	12
4	Local Ducks	12
5	Swabbing alcohol cotton at the dorsal part of the neck	13
6	Plucking the feathers under the wing region	13
7	Fresh fecal sample from Egyptian Goose (EG)	14
8	Process of taking the sample	14
9	Overall occurrence of ectoparasites in both waterbird species	15
10	Status of ectoparasitic infection in both species of waterbirds	16
11	The female of <i>Alloptes sp.</i> (x100) from Egyptian Goose	17
12	The anterior part of the <i>Alloptes sp.</i> (x400) from Domestic Duck	17
13	The posterior part of the female <i>Alloptes sp.</i> (x400) from Domestic Duck	17
14	The male of <i>Bdellorhyncus sp.</i> (x100) from Domestic Duck	18
15	<i>Anaticola sp.</i> (x100)	18
16	<i>Holomenopon sp.</i> (x100)	18
17	Overall occurrence of gastrointestinal parasites in both waterbirds species.	19
18	Status of endoparasitic infection in both species of waterbirds	20
19	Egg of <i>Hypoderaeum conoideum</i> (x100) from Egyptian Goose	21
20	Oocyst of <i>Coccidia spp.</i> (x100) from Egyptian Goose	21
21	Sporulated oocyst of <i>Coccidia spp.</i> (x100) from Domestic Duck	21
22	Egg of <i>Ascaridia sp.</i> (x100) from Domestic Duck	21
23	Larvated egg of <i>Strongyloides sp.</i> (x100) from Domestic Duck	21

ABSTRAK

Abstrak daripada kertas projek yang dikemukakan kepada Fakulti Perubatan Veterinar untuk memenuhi sebahagian daripada keperluan kursus VPD 4901 - Projek.

PENGESANAN DAN MENGENAL PASTI EKTOPARASIT DAN ENDOPARASIT DARIPADA BURUNG AIR DI TAMAN WETLAND PUTRAJAYA

Oleh

Natasha Elmiera Binti Sharif Hudin

2022

Penyelia: Prof. Dr. Jalila Binti Abu

Burung air, termasuk itik dan angsa, menjadi perumah kepada kepelbagaian parasit. Jurang pengetahuan mengenai ektoparasit dan endoparasit masih ada pada haiwan ternakan, ayam dan haiwan peliharaan di Malaysia di mana catatan mengenai parasit burung air masih kurang di negara ini. Satu kajian dilakukan untuk menentukan spesies dan kejadian ektoparasit dan endoparasit di burung air dari Taman Wetland Putrajaya. Tiga puluh burung air termasuk Angsa Mesir (*Alopochen aegyptiaca*) dan Itik Domestik (*Anas platyrhynchos domesticus*) ditangkap dan dipegang secara fizikal. Burung-burung air bercampur usia dan jantina. Sampel bulu pelepah dan swab kapas alkohol diambil daripada leher, badan dan sayap diikuti dengan memeriksa kulit dan bulu secara menyeluruh untuk ektoparasit. Bulu pelepah dan swab kapas dilihat di bawah stereomikroskop untuk kehadiran ektoparasit. Jumlah tiga puluh sampel tinja segar dikumpulkan dan diperiksa dengan teknik 'direct wet mount' dan 'fecal floatation' untuk pengasingan telur parasit dan/atau oocyst untuk kehadiran

endoparasit. Spesies ektoparasit yang terdapat dalam kajian ini merangkumi tungau bulu, *Alloptes sp.* dikesan pada 60% (18/30) burung diikuti oleh *Bdellorhyncus sp.*, dengan 26.67% (8/30). Kutu, *Holomenopon sp.* dijumpai pada 30% (9/30) burung yang diikuti oleh *Anticola sp.*, 23.33% (7/30). Kejadian endoparasit tertinggi dari kajian ini adalah 33.33% (10/30) daripada protozoa diikuti oleh 16.67% (5/30) nematoda dan 3.33% (1/30) trematoda. Empat endoparasite spesies yang berbeza diperhatikan. Salah satunya didapati positif protozoa: *Coccidia spp.* dengan kejadian 33.33% (10/30), dua genera adalah Nematoda: *Ascaridia sp.*, 33.33% (4/30), *Strongyloides sp.*, 3.33% (1/30) dan satu genera positif untuk Trematode: *Hypoderaeum conoideum*, 3.33% (1/30). Kajian ini telah menghasilkan maklumat baru mengenai ektoparasit dan endoparasit daripada burung air di Taman Wetland Putrajaya yang mungkin terbukti berharga untuk tujuan pemuliharaan dan pengurusan, dan untuk kesejahteraan burung.

Kata kunci: ektoparasit, endoparasit, burung air, Angsa Mesir (*Alopochen aegyptiaca*), Itik Domestik (*Anas platyrhynchos domesticus*)

ABSTRACT

An abstract of the project paper presented to the Faculty of Veterinary Medicine in partial fulfillment of the course VPD 4901- Project.

DETECTION AND IDENTIFICATION OF ECTOPARASITES AND ENDOPARASITES OF WATERBIRDS IN PUTRAJAYA WETLAND PARK

By

Natasha Elmiera Binti Sharif Hudin

2022

Supervisor: Prof. Dr. Jalila Binti Abu

Waterfowls, including ducks and geese, are hosts to a great diversity of parasites. A gap of knowledge concerning ectoparasites and endoparasites has remained in livestock, poultry and companion animals in Malaysia where records regarding parasites of waterbird are still lacking in this country. A study was carried out to determine the species and the occurrence of ectoparasites and endoparasites in the waterbirds from Putrajaya Wetlands Park. Thirty waterbirds including Egyptian Goose (*Alopochen aegyptiaca*) and Domestic Duck (*Anas platyrhynchos domesticus*) were caught and physically restrained. They were mixed ages and gender. Feather samples and alcohol cotton swabs were taken from the neck, ventral body and wings followed by examining the skin and feathers thoroughly for ectoparasites. Feather plucks and cotton swabs were viewed under stereomicroscope for presence of ectoparasites. A total of thirty fresh faecal samples were collected and examined by direct wet mount and faecal floatation

technique for isolation of parasitic eggs and/or oocysts for presence of endoparasites. The species of ectoparasites found in this study includes feather mites, *Alloptes sp.* detected in 60% (18/30) of the birds followed by *Bdellorhyncus sp.*, with 26.67% (8/30). The lice, *Holomenopon sp.* were found in 30% (9/30) of the birds followed by *Anticola sp.*, 23.33% (7/30). The highest occurrence of endoparasite from this study was 33.33% (10/30) protozoan followed by 16.67% (5/30) nematodes and 3.33% (1/30) trematodes. Four different intestinal parasites were observed. One of them was found to be positive for protozoa: Coccidia with an occurrence of 33.33% (10/30), two genera were Nematodes: *Ascaridia sp.*, 33.33% (4/30), *Strongyloides sp.*, 3.33% (1/30) and one genera was positive for Trematode: *Hypoderaeum conoideum*, 3.33% (1/30). This study has produced new information on the ectoparasites and endoparasites of the waterbirds in Putrajaya Wetlands Park that may prove valuable for conservation and management purposes, and for bird welfare.

Keywords: ectoparasites, endoparasites, waterbirds, Egyptian Goose (*Alopochen aegyptiaca*), Domestic Duck (*Anas platyrhynchos domesticus*)

CHAPTER 1

INTRODUCTION

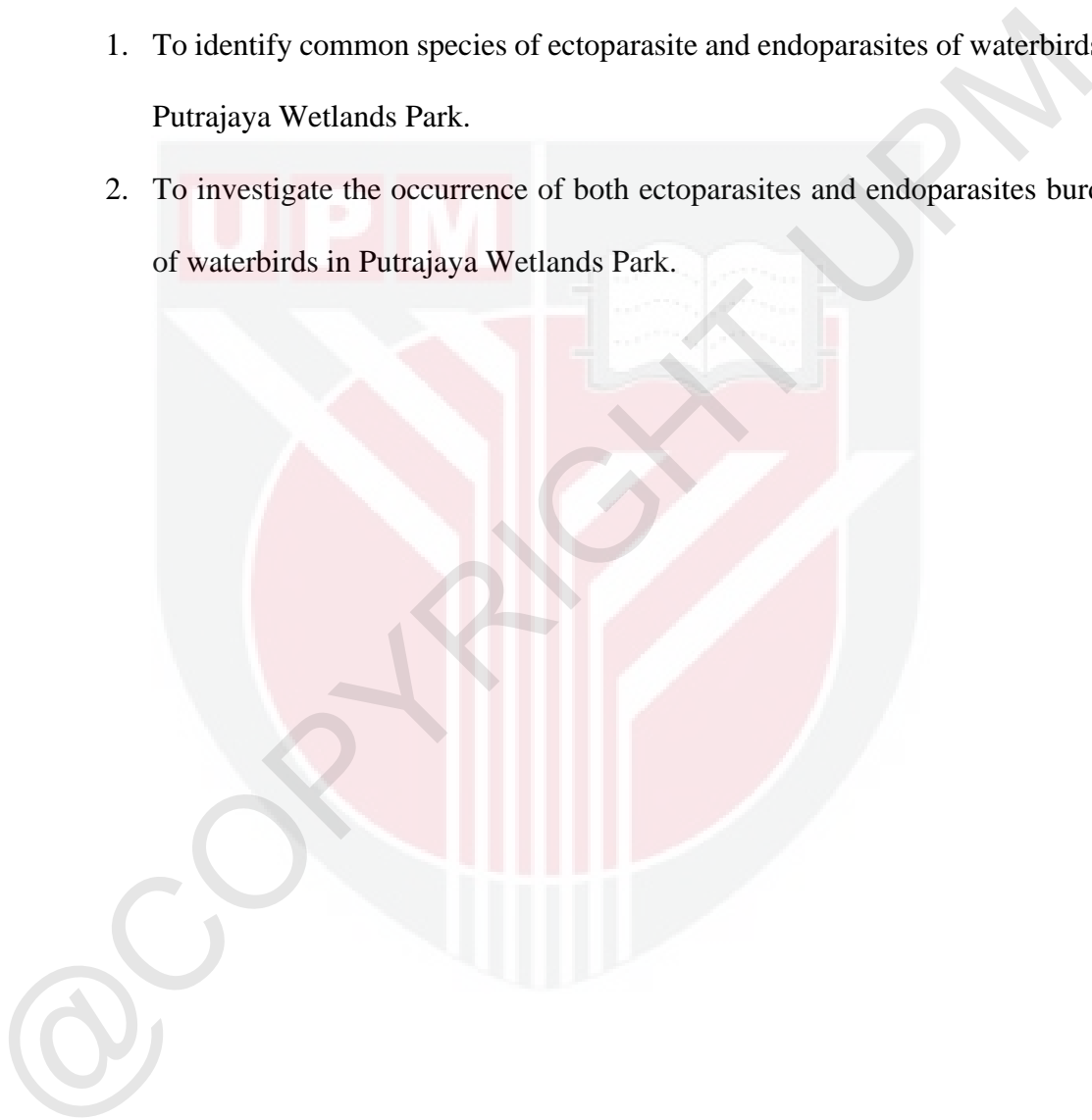
Waterbirds are common in wetland settings and are regarded as the top predators in the wetland ecosystem. Putrajaya Wetlands Park is situated within the quadrant of 2° 57' 43" latitude and 101° 41' 47" longitude. This wetland is a man-made lake that straddles between the two rivers; Chua Rivers and Bisa Rivers. The wetland is also a wildlife sanctuary which attracts a huge variety of animals especially the waterbirds.

In 2017, 22 waterbird species were recorded from Putrajaya wetland habitats (Hassen-Aboushiba, 2017). The Putrajaya wetland is dominated by the Ardeidae family: Javan Pond Heron, Purple Heron, Gray Heron, Great Egret, Yellow Bittern, Cinnamon Bittern and the Rallidae family: Purple Swamphen, White-Breasted Waterhen and Water Cock. Other waterbird species such as the Greater Flamingo, Black Swan, White Goose, Local Duck and Egyptian Goose are also commonly found in Putrajaya wetlands.

Parasites are commonly found in waterbirds in captivity or free-living birds. Ectoparasites are the primary causes of retardation in growth, decreased vitality and poor conditions of the birds (Ruff, 1999). These ectoparasites have direct and indirect effects on wild birds, as debilitated hosts are more prone to infection. Endoparasites are common in wild birds and rarely lead to the death of an individual (Papini *et al.*, 2012). However, when animals are infected with another disease or become stressed, parasites may become more problematic, resulting in the host's death.

Since only few studies on the parasites of waterbirds in Malaysia have been conducted, it is justified to further study the species and the occurrence of the parasites, thus, the objective of this study is to:

1. To identify common species of ectoparasite and endoparasites of waterbirds in Putrajaya Wetlands Park.
2. To investigate the occurrence of both ectoparasites and endoparasites burden of waterbirds in Putrajaya Wetlands Park.



CHAPTER 2

LITERATURE REVIEW

Wetlands always offer diverse habitats for a variety of fauna species especially the waterbirds (Hassen-Aboushiba, 2017). The term 'waterbirds' refers to bird species dependent on aquatic habitats to complete a portion of their life cycles (Rajpar & Zakaria, 2011). There are several exotic birds that are available in Putrajaya Wetland Park such as; Egyptian Goose, Black Swan, Greater Flamingo, White Goose, Pelican and Domestic Ducks.

Parasites are present in both free-living wild waterbirds as well as waterbirds that are kept in captivity. Parasitic disease usually flares up when an animal is immunocompromised due to emaciation, recurrent infectious disease, young age and many other causes (Cooper, 2005).

2.1 Ectoparasites of waterbirds

2.1.1 Arachnida (Mites)

Feather mites from Analgidae, Alloptidae and Pterolichoidea family are a vast group of highly specialized parasites or mutualistic ectosymbionts that spend their entire life cycle on their bird hosts (Gaud & Atyeo, 1996; Proctor, 2003). Mites are known for their close contact with their host for all their lives and transmission occurs via physical contact from one host to another (Taylor *et al.*, 2016). They are extremely small to the naked eye and appear like tiny dirt particles on the birds' body, wings and tail feathers.

These mites feed on blood, lymph fluid, skin debris as well as chewing on the feathers. Infestation by mites is called acariasis and can result in severe dermatitis, known as mange, which may cause significant welfare problems to the birds.

Feather mites are made up of the Analgidae family (*Megninia sp.*), Alloptidae family (*Alloptes sp.*) and Pterolichoidea family (*Grallobia spp.*). All these three genera are common in waterbirds. For example, previous studies from Laura (2013) showed the common feather mites that infest waterbirds are *Megninia spp.* and Alloptidae family. In Jaafar, 2011 found numerous *Megninia spp.* and *Grallobia spp.* (Pterolichoidea) mites from White-Breasted Waterhen (*Amaurornis phoenicurus*).

2.1.2 Insecta (Lice)

All avian lice usually belong to the Philopteridae family and Menoponidae family, which are common on the waterbirds. All species on the birds are chewing lice and therefore are of importance because of the direct damage they cause by chewing the skin or feathers similar to mites (Taylor *et al.*, 2016). Transmission of the lice occurs through physical contact from one bird to another bird. Compared to mites, adult lice and eggs can be seen on the skin and feathers which are commonly observed at the neck, the ventral wings and the vent area (Sia Su *et al.*, 2013). Lice, just like other parasites, often multiply when these birds are debilitated, sick or stressed which led to heavy infestation of lice known as pediculosis (Brown, 1974).

Common avian lice of the Menoponidae family (*Menacanthus sp.*, *Menopon sp.*) and the Philopteridae family (*Goniocotes sp.*, *Lipeurus sp.*) were reported from wild waterbirds in a rescue center in the Philippines (Sia Su *et al.*, 2013). Not only that, but

there are also several studies regarding lice infestation in waterbirds species. Based on a paper on the spatial distribution of chewing lice in both Canada Geese and Mallards from Canada (Grossi & Galloway, 2022), reported that both of these waterbird species are infested with the Philopteridae family; (*Anaticola anseris*, *Anaticola crassicornis* and *Anatoecus spp.*) and the Monoponidae family; *Holomenopon maxbeieri* which are found restricted to the wings and head of the host. Another study from a project paper in Bangkok, Thailand (Songsaeng, 1999) also was able to detect and identify several species of lice such as; *Menacanthus pallidulus*, *M. stramineus*, *Eshiopterus sp.* and *Philopterus sp.* from several species of waterbirds such as the Spot-billed Pelican, Painted Stork, Lesser Adjutant, Greater Adjutant, Purple Swamphen and Sarus Crane.

2.2 Gastrointestinal parasites of waterbirds

There are several parasites adapted to avian species and individual birds may be infected with different parasites at the same time. Therefore, parasite species and their relevance to the host may differ between avian species (Globokar *et al.*, 2017). The most commonly mentioned parasites are *Eimeria sp.*, *Ascaridia galli* and *Heterakis gallinarum* which is mainly due to the fact that many studies are carried out on these parasites (Ahmed, 1969).

2.2.1 Protozoan

2.2.1.1 Coccidian

Coccidian parasites include a variety of lifestyles and means of transmission. Oocyst of most genera are passed unsporulated. They are typically less than 45 µm in length, containing a granular-appearing spherical body and may be round, ellipsoid or ovoid. Coccidiosis due to *Eimeria spp.* may result in mortality in captive waterfowl, although

wild birds apparently carry infections without harm (Wobeser, 1997). Previous studies showed that domestic ducks are exposed to a wide range of gastrointestinal parasites, namely protozoa belonging to the genus *Eimeria sp.*, *Wenyonella sp.*, *Tyzzeria sp.* and *Cryptosporidium sp.* (Lozano *et al.*, 2020).

2.2.2 Helminths

Helminths, such as nematodes and cestodes have been described from waterbirds; most are specific to their host and are not harmful to humans (Woog *et al.*, 2013). The majority of helminths live in the intestinal tract, but some also occur in the respiratory tract as well. Brief overview are the studies regarding helminths in waterfowl, are as follows;

Nematodes or roundworms are frequently reported in waterfowl (Fedynich, 1996). Common helminths in avian from nematodes class are; *Ascaridia sp.*, *Capillaria sp.*, *Syngamus sp.*, *Heterakis sp.* and *Tetrameres sp.* (Taylor *et al.*, 2016). Based on a paper on parasitic nematodes of anseriform birds in Hokkaido, Japan (Yoshino *et al.*, 2009) able to obtain 12 nematodes species in waterbirds belonging to the order Anseriformes such as swan, geese, ducks. From this study, they were able to identify *Amidostomum sp.*, *Epomidiostomum sp.*, *Capillaria sp.* and *Tetrameres sp.* In addition, from Begum (2019) reported that 27 out of 32 domestic ducks (*Anas platyrhynchos domesticus*) were positive (85.71%) for *Ascaridia galli*.

Cestodes or tapeworms are extremely common parasites of birds. Most species infect the intestine, but a few can be found in the ceca or under the gizzard lining. Many cestodes are large enough to detect without magnification in the case of sick and dying birds (Kinsella & Forrester, 1999). Nevertheless, a number of reports have associated

cestode in waterbirds. For example; endoparasites in the annual cycle of feral Greylag Geese (Woog *et al.*, 2013). From this study, they were able to find Cestode: *Cestodea*. However, the level of infestation of this parasite was low and no mortality was caused by parasitic infection.

2.3 Studies of ectoparasites and endoparasites of waterbirds in Malaysia

Detailed research on waterbirds' ectoparasites and endoparasites across Malaysia is still limited. Jaafar (2011), reported regarding parasites in White-Breasted Waterhen but only limited to one species only, the *Amaurornis phoenicurus*. From this study, they were able to find feather mites: *Grallobia spp.*, *Megninia spp.*, lice: *Lipeurus spp.* and Nematoda: *Capillaria spp.*

Another study from Laura (2013) involved detection of blood parasites of waterbirds in the same sampling area, which is the Putrajaya Wetlands Park. Even though Laura focused on blood parasites of waterbirds in her study, she also included her findings of ectoparasites from the waterbirds to see if there is a correlation between the ectoparasites and the blood parasite. From this study, they were able to find feather mites from Analgidae family; *Megninia sp.* and Alloptidae family from the waterbirds.

In contrast, only a few systematic researches had investigated the parasites of waterbird species in Malaysia.

2.4 The importance of parasites in birds

As mentioned earlier, these parasites can have serious pathological effects on birds, inducing high sickness and mortality rates during peaks of infection (Atkinson, Thomas, & Hunter, 2008).

For ectoparasites, causes of mite infestation includes direct epidermal damage that leads to inflammation resulting in reddening of the skin, pruritus, scale and crust formation, cutaneous hypersensitivity, dermatitis or mange on the body, face and feet, and damaging the feather as well (Wall & Shearer, 2001; Atkinson *et al.*, 2008). Feather mites rarely cause harm unless their quantity becomes abundant as they adopt a commensal relationship with their host (Leung & Poulin, 2008).

Clinical importance regarding lice infestation in birds depends on the density of the lice present in a host. Like the mites, chewing and sucking lice feed on skin debris, blood as well as feathers which heavy louse infestation may result in weight loss, lethargy, cutaneous damage, and feather damage. Young and older animals in poor health or birds in unhygienic conditions can also develop rapid heavy infestation (Cooper, 2008; Wall & Shearer 2001). Case report from Dik and Bilal (2016) stated that few White Pelicans showed clinical symptoms of haemorrhagic ulcerative stomatitis due to infestation of Menoponidae family; *Piagetiella titan*. However, bird lice are a little concern to humans because they cannot survive or reproduce off the body of the avian host. Although some bird lice can bite when infested birds are handled, they do not transmit pathogens to human (Atkinson *et al.*, 2008).

Endoparasitic infections are mainly without any symptoms (Sanmartin et al., 2004; Santos *et al.*, 2011). However, in case of stress that accompanies isolation, they can be followed by severe diarrhea, anorexia, loss of body weight and even death of the animals (Santos *et al.*, 2011). Not only that, young or naive birds exposed to high numbers of infective oocysts are most likely to exhibit disease. In 1993, there was an outbreak of intestinal and renal coccidiosis (caused by undescribed *Eimeria sp.* and *Eimeria somateriae*, respectively) resulting in the death of hundreds of Common Eider ducklings (*Somateria molissima*) in Iceland. This outbreak could have been caused by large amounts of mud accumulates into the sea near their nest, which lead to less foraging and undernourishment and stress of the ducklings (Skirnisson, 1997). However, there are no known public health concerns regarding avian species of intestinal *Eimeria spp.* In cestode, adult worms that are found in birds cannot be transmitted directly to humans and do not pose a health threat (Atknison *et al.*, 2008). Human exposure to avian heterakis or ascarid nematodes does not appear to pose a health risk. However, there is potential for transmission between domestic and wild birds. Wild birds may serve as sources of infection for poultry and domestic duck flocks. The only known capillarid that poses a zoonotic threat is *Capillaria philippinensis* which can cause severe enteritis in humans (Cross, 1998) and this species is in zoonosis in parts of Southeast Asia, Egypt, India and Iran.

Thus, knowing the parasite disease can help with water birds' conservation and rehabilitation in Malaysia, and identify potential infectious diseases that may affect them.

CHAPTER 3

METHODOLOGY

3.1 Sampling area

The study was carried out in Tasik Angsa, Putrajaya Wetlands Park (**Figure 1 and Figure 2**). Proper standards of herd health programs such as deworming and ectoparasite prevention were not practiced in this conservation.



Figure 1: Quarantine area of the waterbirds



Figure 2: Egyptian Goose and Mixed Local Ducks in the housing area within the quarantine zone

3.2 Animal

Thirty waterbirds including Egyptian Goose, etc (**Figure 3 and Figure 4**) were sampled in their ground in Putrajaya Wetlands Park. The birds were randomly selected between males and females according to the number agreed with the park management (**Table 1**). The birds were physically restrained using appropriate methods (body grab technique).

Table 1: Species distribution for sample collection

Species	Scientific Name	Number
Egyptian Goose	<i>Alopochen aegyptiacus</i>	15
Domestic Ducks (<i>'itik kampung'</i>)	<i>Anas platyrhynchos domesticus</i>	15
TOTAL		30



Figure 3: Egyptian Goose




Figure 4: Local Ducks

3.3 Sampling method

3.3.1 Ectoparasite collection

Several feathers were plucked from 3 main sites of the body from each bird which are the dorsal neck, the ventral body and under the wing region (avoid cutting/plucking the primary feathers) (**Figure 6**). Then, cotton swabs which contain 70% isopropyl alcohol were used to swab around the same three regions (**Figure 5**) with addition of swabbing around the leg and feet respectively. If arthropods are detected during physical examination, they can be removed from the skin and feathers with forceps. The feathers and the cotton swabs were then placed into a Ziploc bag and brought back

to the laboratory and to be preserved with 75% ethanol. The feathers and the swabs were then examined under stereomicroscope.



Figure 5: Swabbing alcohol cotton at the dorsal part of the neck

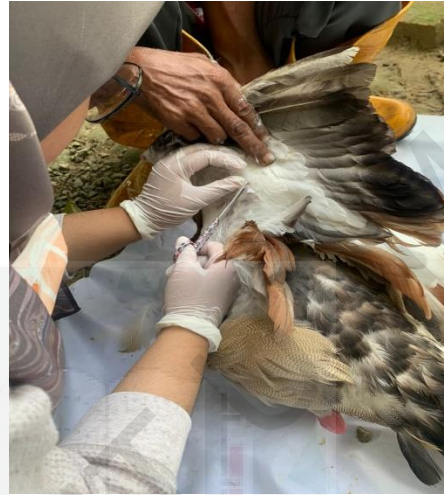

Figure 6: Plucking the feathers under the wing region

3.3.2 Hoyer's Medium mounting technique for mites and lice identification

A drop of Hoyer's medium was placed on a glass slide. The arthropods were transferred onto the drop of Hoyer's medium by using a fine forcep. An 18X18mm coverslip was placed over the specimen. Then, placed the glass slide on a slide warmer to remove any excess air bubbles.

3.3.3 Gastrointestinal parasite collection

A white plastic tablecloth was placed on the ground to monitor the waterbirds to defecate (**Figure 7**). The tablecloth was used to avoid the contamination of fresh faecal samples from touching the ground. Fresh dropping faeces were scooped using a tongue depressor (**Figure 8**). Thus, a total of 30 faecal samples from 2 different species (15

samples from Egyptian Goose (EG), and 15 samples from Local Ducks (LD)) were collected and labeled as EG 1, EG 2... LD 1, LD 2... The samples were kept in a storage box with ices to be transported.

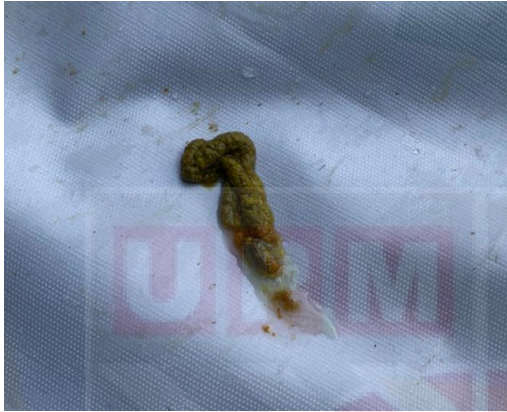

Figure 7: Fresh fecal sample from Egyptian Goose (EG)

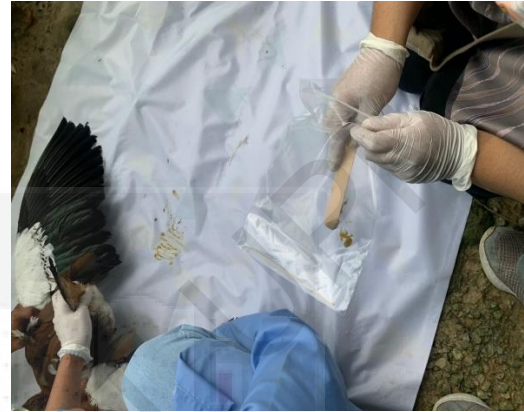

Figure 8: Process of taking the sample

3.3.4 Direct wet mount and faecal floatation technique

Direct wet mount should be performed on fresh faeces. A small amount of stool is placed on the glass slide, mixed with a few drops of normal saline with a wooden applicator stick. Covered the smear with an 18x18mm and examined under a microscope.

Faecal floatation techniques take advantage of the fact that parasite ova and cyst can be separated from other faecal debris due to differences in density. Eggs, oocyst and larvae are usually less dense than floatation solution, and therefore, will rise to the surface. This method of concentrating parasites allows a larger, more representative sample of faeces to be assessed. Faecal floatation to detect endoparasites' eggs by

mixing faeces in a volume of flotation solution and passing the mixture through a double-layer gauze placed on top of a vertical tube. The tube should be filled until a slightly positive meniscus is formed. A coverslip is placed on the tube and allowed to stand for 20 minutes. The coverslip from either method is then examined microscopically using a power magnification of 10X and 40X.

3.3.5 Parasite eggs and oocyst identification

Eggs, and oocyst of parasites were identified on the basis of morphological characteristics (shape and size) by using books of (Taylor *et al.*, 2016) and other published articles from internet sources.

3.4 Data analysis

For this study, the occurrence was measured as the percentage of host individuals infected with a particular parasite. The collected data were coded and entered into Microsoft Excel spreadsheet.

CHAPTER 4

RESULTS

4.1 Ectoparasites

Among 30 samples of cotton swab and feather samples from the waterbirds, 22 samples were found to be positive with one or more than one ectoparasite species. Hence, the positive percentage was 73.33% (**Figure 9**). 56.67% (17/30) of the waterbird's samples were infested with a single species of ectoparasite. 13.33% (4/30) of the waterbirds were infested with double ectoparasite species, and the remaining; 3.33% (1/30) of the waterbirds were infested with three different species of ectoparasites (**Figure 10**).

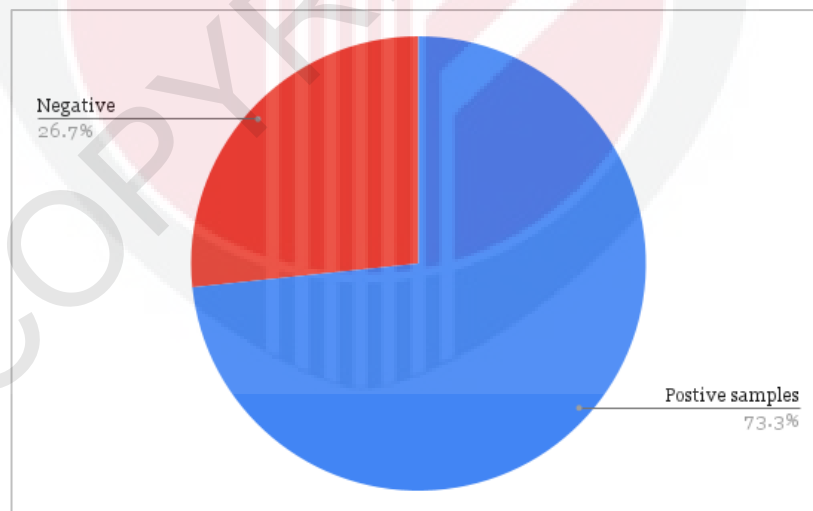


Figure 9: Overall occurrence of ectoparasites in both waterbird species

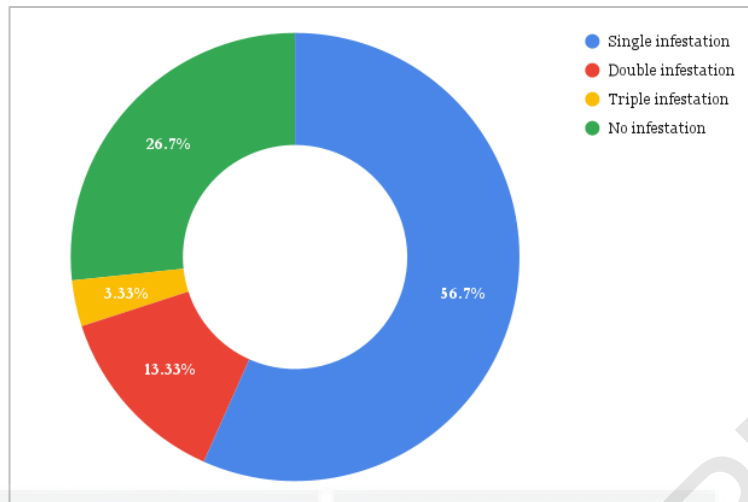


Figure 10: Status of ectoparasitic infection in both species of waterbirds

The overall detection of ectoparasites from the lowest to the highest occurrence were *Anaticola sp.* (23.33%), *Bdellorhyncus sp.* (26.67%), *Holomenopon sp.* (30%) and *Alloptes sp.* (60%). More detailed findings are outlined below.

Table 2: Overall detection and occurrence of ectoparasites in both water birds' species in Wetland Park, Putrajaya (N=30)

Egyptian Goose and Domestic Duck		
Species	Positive sample (N=30)	Occurrence (%)
<i>Alloptes sp.</i>	18	60%
<i>Holomenopon sp.</i>	9	30%
<i>Bdellorhyncus sp.</i>	8	26.67%
<i>Anaticola sp.</i>	7	23.33%

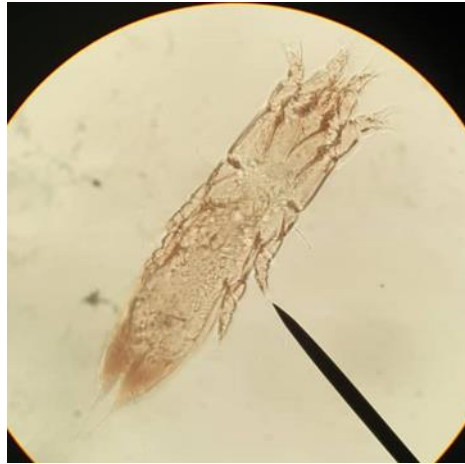

Figure 11: The female of *AlLOPTES sp.* (x100) from Egyptian Goose

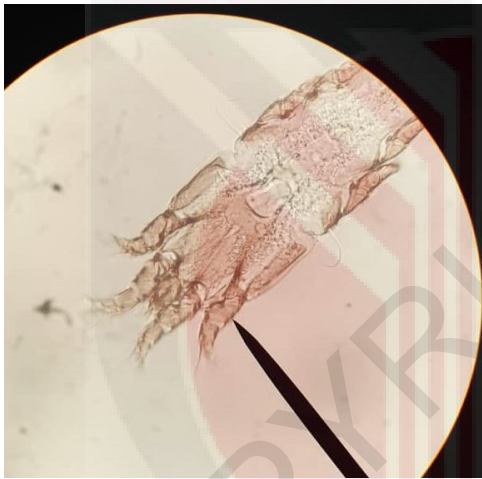


Figure 12: The anterior part of the *AlLOPTES sp.* (x400) from Domestic Duck




Figure 13: The posterior part of the female *AlLOPTES sp.* (x400) from Domestic Duck

4.1.1 Feather samples

Among 30 samples of feathers from waterbirds were taken, 18 were found to harbor feather mites, *AlLOPTES sp.* (**Figure 11 & 12**) and *Bdellorhyncus sp.* (**Figure 14**). *Anaticola sp.* (**Figure 15**) and *Holomenopon sp.* (**Figure 16**) were found from 4 sample feathers from the neck and the vent region of the waterbirds.

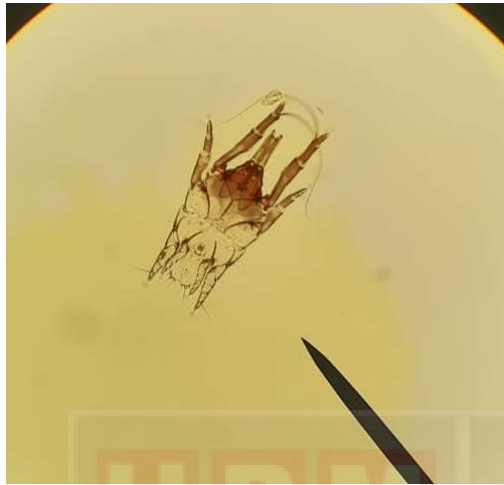


Figure 14: The male of *Bdellorhyncus* sp. (x100) from Domestic Duck

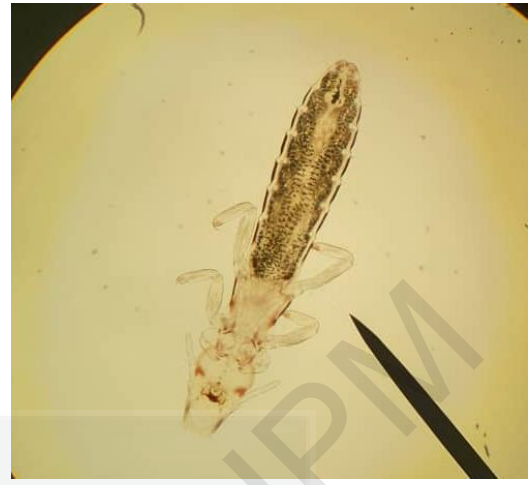

Figure 15: *Anaticola* sp. (x100)



Figure 16: *Holomenopon* sp. (x100)

4.1.2 Cotton swabs

From the cotton swipes, only *Alloptes* sp. (**Figure 11**), *Anaticola* sp. (**Figure 15**) and *Holomenopon* sp. (**Figure 16**) infestation was seen from 5 waterbirds. The rest of the cotton swabs were negative or absent of ectoparasites.

4.2 Endoparasites

Among 30 faecal samples collected from the field, 12 samples were found to be positive with one or more gastrointestinal parasites. Hence, the positive percentage was 43.33% (**Figure 17**).

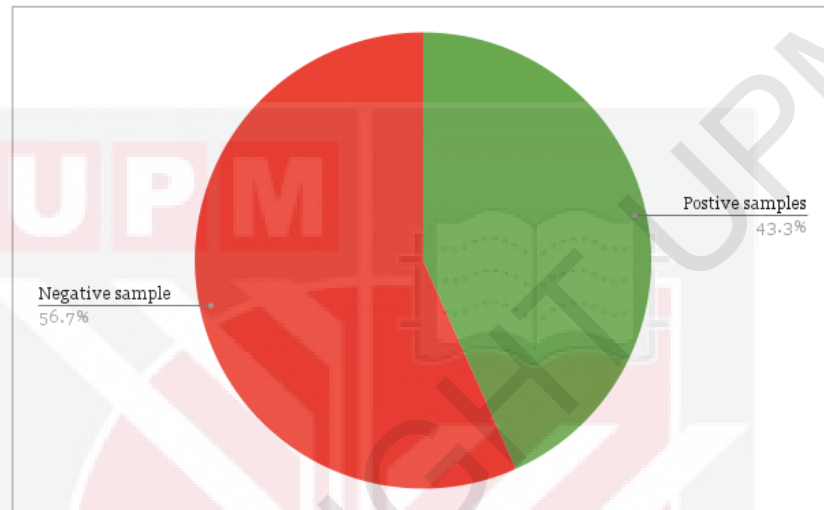


Figure 17: Overall occurrence of gastrointestinal parasites in both Egyptian Goose and Domestic Duck in Wetland Park, Putrajaya

Among the 12 positive samples; about 23.33% (7/30) of the waterbird's samples were single infection or monoparasitic and the remaining 16% (5/30) are mixed infection of endoparasite (**Figure 18**).

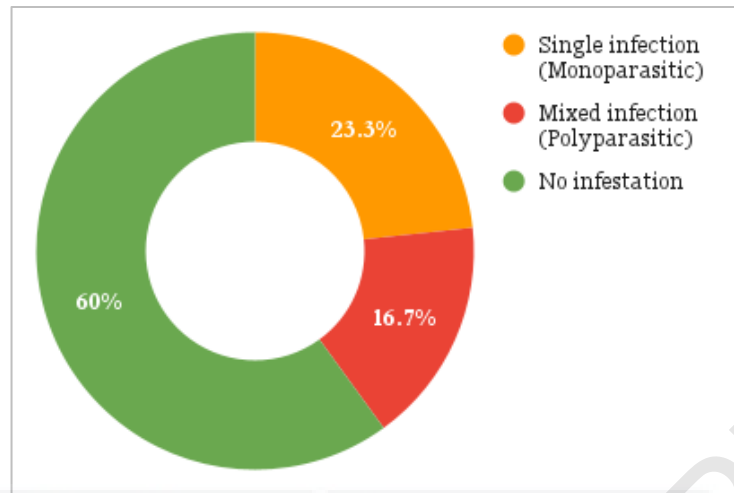


Figure 18: Status of endoparasitic infection in both species of waterbirds

The overall detection of gastrointestinal parasite species from the highest to the lowest occurrence were *Coccidia spp.* with (33.33%) followed by *Ascaridia sp.* (13.33%) and lastly the *Strongyloides sp.* and *Hypoderaeum conoideum* with (3.33%). More detailed findings are outlined below.

Table 3: Overall endoparasite species occurrence in both water birds' species in Wetland Park, Putrajaya (N=30)

Species	Egyptian Goose and Domestic Duck	
	Positive sample (N=30)	Occurrence (%)
Protozoa		
<i>Coccidia sp.</i>	10	33.33%
Nematode		
<i>Ascaridia sp.</i>	4	16.67%
<i>Strongyloides sp.</i>	1	3.33%
Trematodes		
<i>Hypoderaeum conoideum</i>	1	3.33%

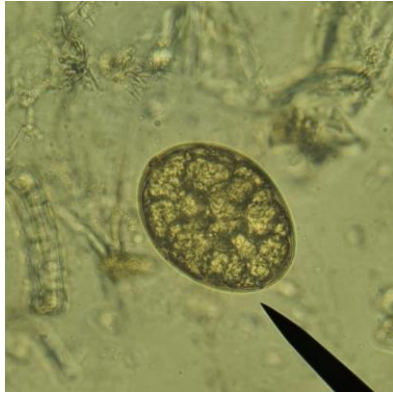

Figure 19: Egg of *Hypoderaeum conoideum* (x100) from Egyptian Goose

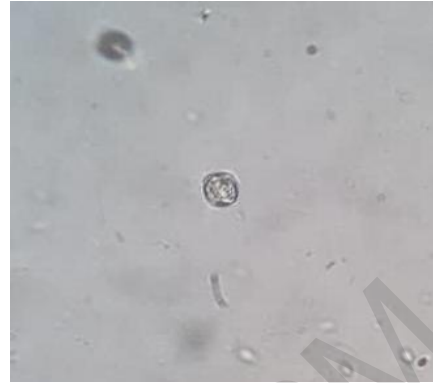

Figure 20: Oocyst of *Coccidia* sp. (x100) from Egyptian Goose

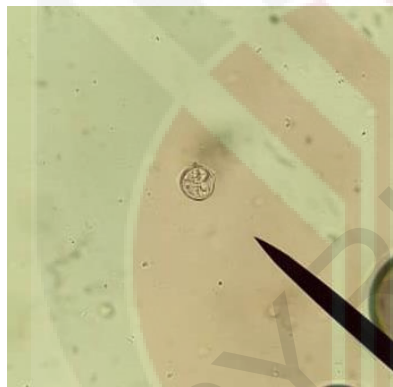


Figure 21: Sporulated oocyst of *Coccidia* sp. (x100) from Domestic Duck

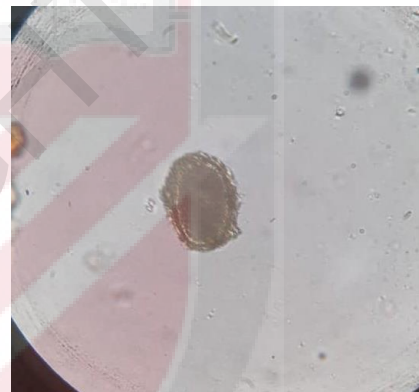


Figure 22: Egg of *Ascaridia* sp. (x100) from Domestic Duck



Figure 23: Larvated egg of *Strongyloides* sp. (x100) from Domestic Duck

CHAPTER 5

DISCUSSION

5.1 Ectoparasites

Most ectoparasites found from both waterbird species were the feather mites from the Alloptidae family; *Alloptes sp.* These mites were found mostly on the feathers collected; especially under the wing region and some on the cotton swabs from a few birds. From the findings, it is supported by a project paper from Laura (2013), where they were able to detect feather mites of the Alloptidae family from the waterbirds in Putrajaya Wetland Park. Compared to this study, genus identification of the feather mites from the Alloptidae family was further identified based on the morphology of the mites from journals and published article (Forrester *et al.*, 1994). In addition, the presence of mites from the *Alloptes sp.* in the waterbirds was reported in many countries as well (Pedroso & Hernandez, 2016; Hernandez & Brito, 2022).

Another feather mite's species, which is from the Avenzoariide Family; *Bdellorhyncus sp.* was only found on the feathers of both waterbird species. The present of findings are in agreement with Forrester *et al.* (1994) and Borah *et al.* (2018) stated that *Bdellorhyncus sp.* are commonly found in the Anatidae family which include ducks and geese. However, this genus of *Bdellorhyncus sp.* is poorly understood due to limited report regarding this species.

Next, lice from the Menoponidae family; *Holomenopon sp.* were found in 3 body regions: neck, wings, and the tail. These lice were found during handling of birds. This proves that the method used in this study did not apply for all ectoparasites species

from the waterbirds as these lice can be seen by naked eye. The presence of lice of *Holomenopon sp.* was concurred from several studies (Forrester *et al.*, 1994; Begum *et al.*, 2019; Grossi & Galloway, 2022) regarding *Holomenopon sp.* in ducks. Another chewing louse that was found during handlings of birds and from the cotton swab was from the Philopteridae family; *Anaticola sp.* which was seen at the neck and the wings feathers. The present of findings of *Anaticola sp.* are in agreement with Grossi & Galloway (2022), regarding predilection site of this species which restricted to wings and neck region.

5.2 Gastrointestinal parasites

During the study, four different intestinal parasites (Nematoda: *Ascaridia sp.*, *Strongyloides sp.*, Protozoa: *Coccidia spp.*, Trematodes: *Hypoderaeum conoidaeum*) were found from both Egyptian Goose and Domestic Ducks. Among identified parasites, *Coccidia spp.* showed the highest occurrence with 33.33% and trematodes showed the lowest occurrence with 3.33%.

However, the burden of the endoparasites were relatively low in this study as every positive sample only showed '1+' which indicated 1 ova present in some field when observed under the light microscope.

Further identification for *Coccidia spp.* was not done during the study, as these protozoa need to undergo sporulation tests (Amer *et al.*, 2010). However, no appreciable clinical signs such as diarrhea were observed in the birds that tested positive for oocyst of *Coccidia* species due to low burden of protozoa and possibility of the birds infected with non-pathogenic *Coccidia* species (Rosa & Edgar, 2015).

For the nematodes, the occurrence of *Ascarids sp.* along with other endoparasites observed in this study were in accordance with the report furnished by Begum *et al.* (2019), who stated that ascarid infection can be found in ducks and geese. Encountering *Strongyloides sp.* in the waterbirds in this study was further supported by the studies of Shresta *et al.* (2018), which demonstrated that *Strongyloides sp.* Are usually found with the lowest occurrence from samples of ducks which may support the result from this study as there was only one positive sample with *Strongyloides sp.*

Trematode egg species that were found during the study were most likely *Hypoderaeum conoideum* from direct wet mount. Lower burden of trematodes might be due to the molluscan intermediate host which are not available during the sample collection. This study is in an agreement with Shresta *et al.* (2018), regarding low occurrence of trematode due to absence of molluscan which act as an intermediate host.

Overall, all 30 waterbirds do not show any serious of clinical signs such as diarrhea, anorexia and damaged feathers. The body condition score of all the birds were well conditioned (3/5) and their feathers were still intact and absent of scruffy feathers (0/6); based on the feather score from Mahboub *et al.*, (2005). Hence, the parasite does not give impact on the well-being and productivity of the waterbirds.

CHAPTER 6

CONCLUSION

The purpose of this study was to determine the species and the occurrence of both ectoparasites and endoparasites of waterbirds in Wetlands Park, Putrajaya. For ectoparasites, the Alloptidae family; *Alloptes sp.* is the most common ectoparasites found in both Egyptian Goose and Domestic Ducks with 60% followed by *Holomenopon sp.*; 30% from Menoponidae family, the Avenzoariide Family; *Bdellorhyncus sp.* mites with 26.67% and *Anaticola sp.*; 23.33% from the Philopteridae family. For endoparasite, four different intestinal parasites were observed. Among them, two genera were found to be positive for Nematodes: *Ascaridia sp.* (13.33%) and *Strongyloides sp.* (3.33%), one genera were Trematode: *Hypoderaeum conoideum* with 3.33% and one genera were found to be positive for protozoa, *Coccidia spp.* with 33.33% which is the most common endoparasite found in both species of waterbirds. Nevertheless, both ectoparasite and endoparasite burden are relatively low in this study.

This study has produced new information on the ectoparasites and endoparasites of the waterbirds in Putrajaya Wetlands Park that may prove valuable for conservation and management purposes, and for the birds' welfare.

CHAPTER 7

RECOMMENDATION

Future studies should include further identification of the parasite by using genetic sequencing as the species of both ectoparasites and endoparasites can only be identified until genus level in this study. Therefore, PCR assay should be used for further identification of both ectoparasites and endoparasites in the waterbirds as certain parasite species can cause harm not only to the birds but also can be zoonotic to humans as well. Other recommendation for future study includes involvement of more waterbird's species from sampling area as there were limited waterbirds species provided in the sampling area. Therefore, sampling area can be done in other places as well such as other wetland areas and zoos which can include more variety of waterbird species.

REFERENCES

- Ahmed, S. (1969). Survey on type of helminths commonly found in country ducks. *Pakistan Journal of Veterinary Science*, 3:110-112.
- Amer, M., El-Khateeb, R., Abu-Elezz, N., Abdelgayed, S., Ghetas, M. M. & Kutkat, M. (2010). Isolation and Identification of Eimeria from Field Coccidiosis in Chickens. *Journal of American Science*, pp. 1107-1114.
- Atkinson, C., Thomas, N. & Hunter, D. (2008). *Parasitic diseases of wild birds*. (Vol 1) New York: Wiley-Blackwell.
- Begum, A., Mukutmoni, M. & Akter, M. (2019). *Parasite diversity in Domestic Duck On Anas Platyrhynchos Domesticus*. Munshiganj, Dhaka.
- Brown, N. (1974). The effect of louse infestation, wet feathers, and relative humidity on the grooming behavior of the domestic chicken. *Poultry Science*, 53(1): 717-719.
- Cooper, J. (2005). Birds of prey: Health and Disease. *The Canadian Veterinary Journal*, 44(10): 827.
- Cross, J. (1998). Capillariasis. In *Zoonoses: Biology, Clinical Practice, and Public Health Control*, pp. 20-129.
- Dik, B. (2016). Erosive Stomatitis in a White Pelican (*Pelecanus onocrotalus*) Caused by *Piagetiella titan* (Mallophaga: Menoponidae). *Journal of veterinary medicine. B, Infectious diseases and veterinary public health*, 53(3): 153-154.
- Fedynich, A. M. (1996). Helminth community structure and pattern in a migratory host (*Anas platyrhynchos*). *Can. J. Zool* (72): 496-505.
- Forrester, D., Kinsella, M., Mertins, J., Price, R. & Turnbull, R. (1994). Parasitic Helminths and Arthropods of Fulvous Whistling-ducks (*Dendrocygna bicolor*)

in Southern Florida. *Journal of the Helminthological Society of Washington*, pp. 80-84.

Gaud J., Atyeo, W. (1996). Feather mites of the world (Acarina, Astigmata): The supraspecific taxa. *Sciences Zoologiques*, 1(227): 193.

Globokar, M., Fischer, D. & Pantchev, N. (2017). Occurrence of endoparasites in captive birds between 2005 to 2011 as determined by faecal flotation and review of literature. *Berliner und Münchener tierärztliche Wochenschrift*, doi:10.2376/0005-9366-16094.

Grossi, A. & Galloway, T. (2022). Spatial distribution of chewing lice (Phthiraptera: Menoponidae, Philopteridae) infesting Canada geese and mallards (Aves: Anatidae), in Manitoba, Canada. *The Canadian Entomologist*, 154(1), doi:10.4039/tce.2022.27.

Hassen-Aboushiba, A. B. (2017). Comparison of waterbird species composition and habitat characteristics of two different wetlands of Malaysia. *Journal of Ecology and The Natural Environment*, 9(7): 124-131.

Hernandes, F. & Brito, R. R. (2022). Feather mites (Acariformes: Astigmata) of the brown noddy, *Anous stolidus* (Charadriiformes: Laridae), with description of two new species from Brazil. *Acarologia*, (62): 317-331.

Jaafar, N. (2011). Parasites of the White-Breasted Waterhen (*Amaurornis phoenicurus*). In: 6th Seminar on Veterinary Sciences, Faculty of Veterinary Medicine, Universiti Putra Malaysia, *Serdang*, pp. 133.

Kinsella. J. M. & Forrester, A. D. (1999). Parasitic helminths of the common loon *Gavia immer* on its wintering grounds in Florida. *Helminthological Society of Washington* (66):1-6.

- Laura, B. (2013). Detection of blood parasites in waterbirds. In: 8th Seminar on Veterinary Sciences, Faculty of Veterinary Medicine, Universiti Putra Malaysia, Serdang, p. 135.
- Leung, T. & Poulin, R. (2008). Parasitism, commensalism, and mutualism: Exploring the many shades of symbioses. *Vie et Milieu*, pp. 107-115.
- Lozano, J., Oliveira, M., Paz-Silva, A., & Luis, M. D. (2020). Gastrointestinal Parasitism in Domestic Ducks., pp. 4-12.
- Mahboub, H. M., Müller, J. & Eberhard, B. (2005). Outdoor Use, Tonic Immobility, Heterophil/lymphocyte Ratio and Feather Condition in Free-range Laying Hens of Different Genotype. *British poultry science*, (45): 738-744.
- Papini, R., Girivetto, M., Marangi, M., Mancianti, F., & Giangaspero, A. (2012). Endoparasite infections in pet and zoo birds in Italy. *Scientific World*. doi: 10.1100/2012/253127.
- Pedroso, L. & Hernandez, F. (2016). New records of feather mites (Acariformes: Astigmata) from non-passerine birds (Aves) in Brazil. *Check List: The Journal of Biodiversity Data*, 12(6): 1-25. doi:10.15560/12.6.2000.
- Proctor, H. C. (2003). Feather mites (Acari: Astigmata): cology, behavior and evolution. *Annual Review of Entomology* (48): 185-209. doi: 10.1146/annurev.ento.48.091801.112725.
- Rajpar, M. & Zakaria, M. (2011). Density and diversity of waterbirds and terrestrial birds at Paya Indah Wetland Reserve, Selangor Peninsular Malaysia. *Journal of Biological Sciences*, 10(7): 658-666.
- Roberts, L. S. & Janovy, J. J. (2005). *Foundations of Parasitology*. 7th ed, McGraw Hill, Boston MA.

- Rosa, Q. C. & Edgar, D. (2015). Review Article Control of Avian Coccidiosis: Future and Present Natural Alternatives. *BioMed Research International*, pp. 1-11. doi:10.1155/2015/430610.
- Ruff. (1999). Important parasites in poultry production systems. *Veterinary parasitology*, 84(3-4): 337–347. doi: 10.1016/s0304-4017(99)00076-x.
- Sanmartín M. L., Álvarez F., Barreiro G. & Leiro J. (2004). Helminth fauna of Falconiform and Strigiform birds of prey in Galicia, Northwest Spain. *Parasitology Research*, (92): 255-263.
- Santos T., Oliveira J. B., Vaughann C. & Santiago H. (2011). Health of an ex situ population of raptors (Falconiformes and Strigiformes) in Mexico: Diagnosis of internal parasites. *Revista de Biología Tropical*, pp. 1265-1274. doi:10.15517/rbt.v0i0.3397.
- Shrestha, D., Chhetri, B. & Subedi, J. (2020). Gastrointestinal parasites of domesticated duck (*Anas Platyrhynchos Linnaeus, 1758*) In Chandragiri Municipality, Kathmandu, Nepal. *Ife Journal of Science* (22): 13-15.
- Sia Su, G. I., Amil, C. J. A., San Juan, J. A. P., Sia Su, M. L., Maguad, G. S., Salinas, R. A., Ragraio, E.M., Santiago, A. A. & Ramos, G. B. (2013). Ectoparasite Survey of Quarantined Animals in a Wildlife Rescue Center in Quezon City, Philippines. *World Journal of Agricultural Research*, 1(3): 44-47.
- Skirnisson, K. (1997). Mortality associated with renal and intestinal coccidiosis in juvenile eiders in Iceland. *Parasitologia*, 39(4): 325-330.
- Songsang, P. (1999). Study on ectoparasites of some water birds. *Kasetart University*. Bangkok, Thailand.
- Taylor, M., Coop, R. L. & Wall, R. (2016). *Veterinary Parasitology 4th Edition*. Wiley-Blackwell.

Wall, R., & Sherear, D. (2001). *Veterinary ectoparasites: biology, pathology and control*. 2nd ed, Blackwell Sciences Ltd, Oxford, London.

Wobeser, G. A. (1997). *Diseases of wild waterfowl*. *Plenum Press*. 2nd ed, Springer, New York, United State of America.

Woog, F., Maierhofer, J., & Haag, H. (2013). Endoparasites in the annual cycle of feral Greylag Geese. (61): 166-181. Retrieved from <https://wildfowl.wwt.org.uk/index.php/wildfowl/article/view/1242>.

Yoshino, T., Uemura, J., Endoh, D., Kaneko, M., Osa, Y., & Asakawa, M. (2009). Parasitic nematodes of anseriform birds in Hokkaido, Japan. *Helminthologia* (46): 117-122. doi: 10.2478/s11687-009-0023-x.