



UNIVERSITI PUTRA MALAYSIA

**DETECTION AND IDENTIFICATION OF GASTROINTESTINAL
PARASITES IN CAPTIVE PSITTACINE IN KLANG VALLEY REGION,
MALAYSIA**

NIK RAHIL HANNAH BINTI NIK SHEHAR

**Ip
FPV 2023 10**

**DETECTION AND IDENTIFICATION OF GASTROINTESTINAL PARASITES IN
CAPTIVE PSITTACINE IN KLANG VALLEY REGION, MALAYSIA**

NIK RAHIL HANNAH BINTI NIK SHEHAR

A project paper submitted to the
Faculty of Veterinary Medicine, Universiti Putra Malaysia

In partial fulfilment of the requirement for the
DEGREE OF DOCTOR OF VETERINARY MEDICINE

Universiti Putra Malaysia

Serdang, Selangor Darul Ehsan.

DECEMBER 2023

CERTIFICATION


It is hereby certified that we have read this project paper entitled “Detection and Identification of Gastrointestinal Parasites in Captive Psittacine in Klang Valley region, Malaysia”, by Nik Rahil Hannah Binti Nik Shehar and in our opinion it is satisfactory in terms of scope, quality, and presentation as partial fulfilment of the requirement for the course VPD 4999 – Final Year Project.

**PROFESSOR DR. JALILA ABU
DVM (UPM), MSc, PHD (MINNESOTA),
Lecturer,
Faculty of Veterinary Medicine
Universiti Putra Malaysia
(Supervisor)**

**DR. NOR AZLINA ABDUL AZIZ
DVM (UPM), MSc, PHD (BRISTOL)
Lecturer,
Faculty of Veterinary Medicine
Universiti Putra Malaysia
(Co-Supervisor)**

DEDICATION

This humble project is dedicated to my beloved parents, Norainon Binti Mohamed Nor and Nik Shehar Bin Nik Wan, my supportive siblings and my hardworking friends for their love, prayers, support and encouragement throughout my pursuit of education.



ACKNOWLEDGEMENT

Saying thank you is not enough to express my gratitude to these individuals as this project would be impossible without their help. First and foremost, I would like to send my deepest thanks to my fellow supervisor and co-supervisor, Professor Dr. Jalila Abu and Dr. Nor Azlina Abdul Aziz for the knowledge and guidance that was always given to me with grace and kindness.

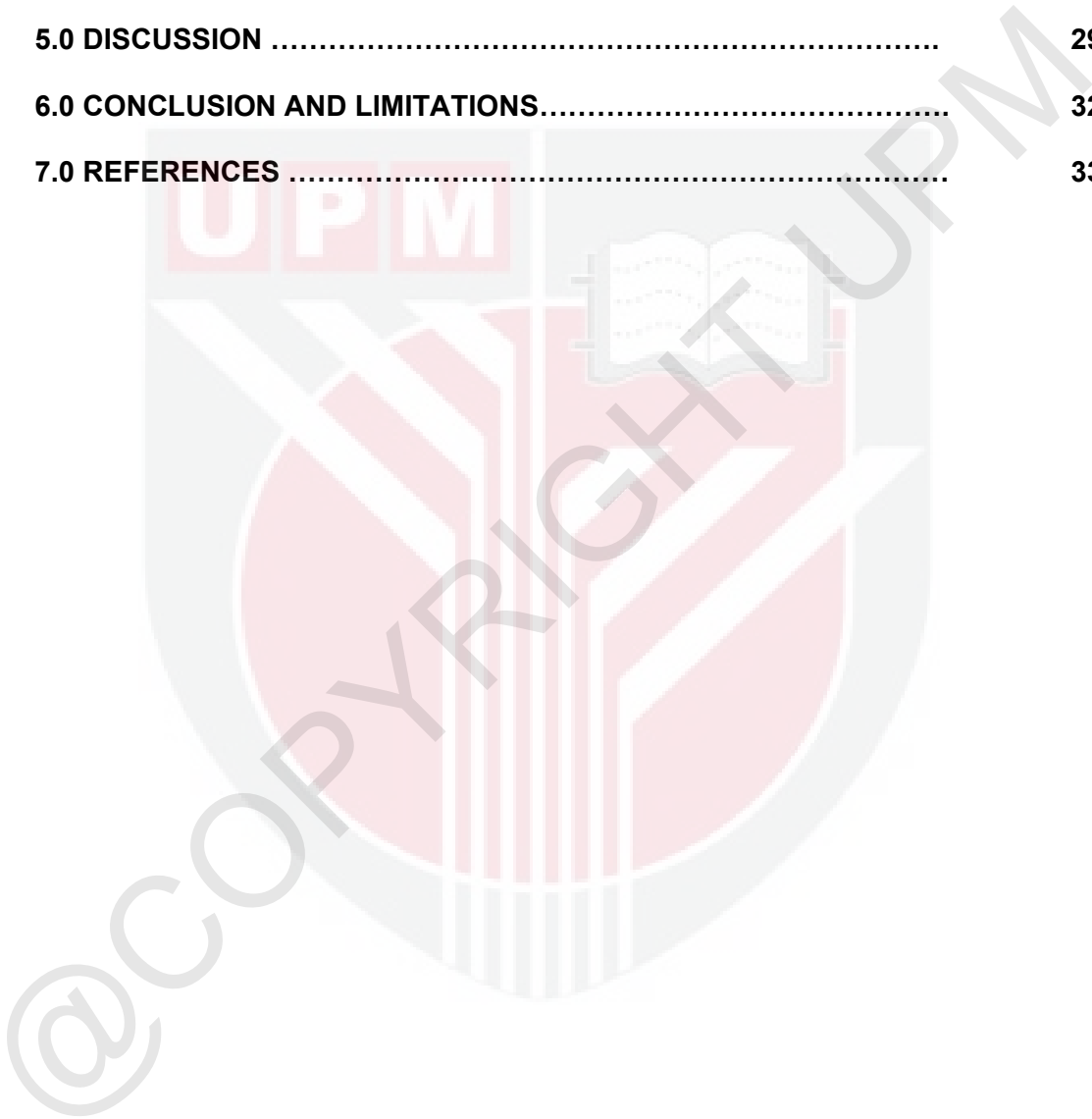
I am also eternally grateful to my parents, Norainon Binti Mohamed Nor and Nik Shehar Bin Nik Wan, for the unconditional support and love provided to me all my life. Special thanks to my brother, Nik Ahmad Imran Bin Nik Shehar and aunt, Nik Ramas Binti Nik Wan, for being the best brother and aunt, for assisting me during sampling and for always going along with all my whims. Thank you to Puan Maizatul, Encik Rashid and Puan Ain from the Parasitology Laboratory, Faculty of Veterinary Medicine, UPM for patiently teaching and guiding me with kindness throughout this project. I would also like to thank the owners and staff of the pet shops, zoos and bird parks that have given me permission to obtain samples at their location. The immense cooperation is greatly appreciated.

Finally, yet importantly, I would like to express my gratitude to my diligent friends who have helped ease this journey with their presence and humour. I am proud of all of us and hope that all our efforts are greeted with success.

TABLE OF CONTENTS

	Page
TITLE	i
CERTIFICATION	ii
DEDICATION.....	iii
ACKNOWLEDGEMENTS	iv
TABLE OF CONTENTS	v
LIST OF TABLES	vii
LIST OF CHARTS.....	vii
LIST OF FIGURES.....	vii
ABSTRAK	viii
ABSTRACT	ix
1.0 INTRODUCTION	10
2.0 LITERATURE REVIEW	13
2.1 Nematode	13
2.2 Cestode.....	15
2.3 Trematode.....	16
2.4 Protozoa.....	16
3.0 MATERIALS AND METHODS	19
3.1 Sample collection	19
3.2 Transportation of samples	20
3.3 Faecal examination.....	21
3.3.1 Direct Wet Mount Technique.....	21

3.3.2 Faecal Flotation Technique	21
3.3.3 Modified Ziehl-Neelsen Staining Technique	22
4.0 RESULTS	24
5.0 DISCUSSION	29
6.0 CONCLUSION AND LIMITATIONS.....	32
7.0 REFERENCES	33



LIST OF TABLES	Page
Table 1: Species distribution for sample collection.....	20
Table 2: Parasitic burden of gastrointestinal parasites in captive psittacines in the Klang Valley area, Malaysia.....	27
Table 3: Reference for parasitic burden scoring by Parasitology Laboratory, Faculty of Veterinary Medicine, UPM.....	28
LIST OF FIGURES	Page
Figure 1: Faecal flotation in vials with coverslip on the surface.....	22
Figure 2: Stains used in Modified Ziehl-neelsen staining procedure.....	23
Figure 3: <i>Ascaridia</i> sp. ova (400x).....	26
Figure 4: <i>Ascaridia</i> sp. ova (100x).....	26
Figure 5: Trematode egg (400x).....	26
Figure 6: Trematode egg (left) and <i>Ascaridia</i> sp. ova (right) (400x).....	26
Figure 7: <i>Heterakis</i> sp. ova (400x).....	26
Figure 8: <i>Giardia</i> sp. trophozoite (1000x).....	26
LIST OF CHARTS	Page
Chart 1: Overall occurrence of gastrointestinal parasite in captive psittacine in the Klang Valley area, Malaysia.....	24
Table 2: Positive samples of gastrointestinal parasites in captive psittacines in the Klang Valley area, Malaysia.....	25

ABSTRAK

Abstrak daripada kertas projek yang dikemukakan kepada Fakulti Perubatan Veterinar untuk memenuhi sebahagian daripada keperluan kursus VPD 4999 – Projek Akhir Tahun.

PENGESANAN DAN PENGENALAN PARASIT GASTROUSUS DALAM PSITTACINE TAWANAN DALAM KAWASAN LEMBAH KLANG, MALAYSIA

Oleh

Nik Rahil Hannah Binti Nik Shehar

2023

Penyelia: Professor Dr. Jalila Abu**Penyelia Bersama: Dr. Nor Azlina Abdul Aziz**

Peningkatan dalam minat membela burung psittacin sebagai haiwan peliharaan di Malaysia meningkatkan kepentingan tentang pengetahuan asas dalam pemeliharaan burung sebagai haiwan peliharaan untuk mencegah penyakit-penyakit seperti jangkitan parasit gastrousus yang dapat menyebabkan burung peliharaan tidak sihat dan mempunyai potensi zoonotik. Projek ini bertujuan untuk mengenalpasti jenis-jenis parasit gastro usus di dalam burung peliharaan psittacin dan mempelajari kejadian beban parasit gastro usus dalam pelbagai spesies burung peliharaan psittacin. Sampel najis telah berjaya dikumpul dari 50 burung peliharaan psittacin dari empat (4) kedai haiwan, dua (2) zoo dan satu (1) taman burung dalam kawasan Lembah Klang, Malaysia. Sampel yang diperoleh termasuk sampel najis dari pelbagai saiz burung peliharaan psittacin yang dikategorikan kepada tiga (3) kumpulan, iaitu kumpulan saiz kecil, kumpulan saiz sederhana dan kumpulan saiz besar. Lima belas (15) sampel adalah daripada burung dari kumpulan bersaiz kecil, 20 sampel daripada burung dari kumpulan bersaiz

sederhana dan 15 sampel daripada burung dari kumpulan bersaiz besar. Sampel-sampel najis yang berjaya dikumpulkan telah disimpan dalam peti sejuk pada suhu 4°C dan diperiksa melalui teknik *Direct Wet Mount*, teknik *Direct Fecal Flotation* dan *Modified Ziehl-Neelsen staining*. Keputusan menunjukkan 9 (18%) dari 50 sampel adalah positif, dengan satu (1) atau lebih parasit gastrousus, dengan jangkitan tertinggi daripada tujuh (14%) sampel positif dengan jangkitan dari *Ascaridia* sp. Seterusnya, jangkitan kedua tertinggi iaitu 2 (4%) sampel dijangkiti dengan Trematode. Sampel positif yang lain adalah 1 (2%) sampel dijangkiti oleh *Heterakis* sp. dan 1 (2%) sampel dijangkiti oleh *Giardia* sp. Keputusan menunjukkan 7 (14%) daripada 9 sampel positif ialah jangkitan tunggal dan 2 (4%) sampel adalah jangkitan pelbagai. Beban parasit tertinggi yang diperoleh dari keputusan ialah sampel dijangkiti oleh *Ascaridia* sp., iaitu 3 sampel dengan beban parasit 3+, 2 sampel dengan beban parasit 2+ dan 2 sampel dengan beban parasit 1+. *Ascaridia* sp., *Heterakis* sp. dan Trematode diperoleh melalui teknik *Direct Wet Mount* dan teknik Faecal Flotation. Walaubagaimanapun, *Giardia* sp. berjaya diperoleh melalui teknik *Modified Ziehl-Neelsen staining*, tetapi tiada yang diperoleh melalui teknik *Direct Wet Mount*. Cryptosporidium tidak berjaya diperoleh melalui teknik *Modified Ziehl-Neelsen staining*. Kesimpulannya, pelbagai jenis parasit gastrousus yang dapat dikenalpasti mempunyai beban parasit yang berbeza dan membantu memberi maklumat tentang kepentingan rutin penggunaan nyah-cacing dan amalan disinfeksi terhadap burung peliharaan psittacin.

Kata kunci: *burung psittacin, parasit gastrousus, beban parasit*

ABSTRACT

An abstract of the project paper presented to the Faculty of Veterinary Medicine in partial fulfilment of the course VPD 4999 – Final Year Project.

DETECTION AND IDENTIFICATION OF GASTROINTESTINAL PARASITES IN CAPTIVE PSITTACINE IN KLANG VALLEY REGION, MALAYSIA

by

Nik Rahil Hannah Binti Nik Shehar

2023

Supervisor : Professor Dr. Jalila Abu

Co-supervisor: Dr. Nor Azlina Abdul Aziz

The increasing interest in keeping psittacine birds as pets in Malaysia has resulted in the rising importance of basic management knowledge of pet birds to prevent common diseases such as gastrointestinal parasitic infection as it may lead to poor animal health and a potential zoonotic risk. Thus, the purpose of this study is to identify the different types of gastrointestinal parasites and to study the occurrence of gastrointestinal parasites and its burden in multiple species of captive psittacine birds. Faecal samples were collected from 50 captive psittacines at four (4) pet shops, two (2) zoos and one (1) bird park around Klang Valley, Malaysia. The samples included faeces collected from different sized captive psittacine, categorised into groups of small, medium and large-sized psittacine birds. Fifteen (15) faecal samples were collected from small birds, 20 samples taken from medium-sized birds and 15 samples were sampled from large-sized birds. The faecal samples collected were kept in a 4°C freezer and examined

through Direct Wet Mount technique, Direct Faecal Flotation technique and Modified Ziehl-Neelsen staining. In total, 9 (18%) samples were positive for at least one of the gastrointestinal parasites found, with the highest case of infestation of 7 (14%) samples infested by *Ascaridia* sp., followed by 2 (4%) samples infested with Trematode egg, becoming the second highest infestation. Other positive samples consist of 1 (2%) sample with *Heterakis* sp. and 1 (2%) sample with *Giardia* sp. infestation. Results showed that 7 (14%) of the samples were single infections, while 2 (4%) samples had multiple infections. As for the parasitic burden, *Ascaridia* sp. infestation had the highest weightage, which among the 7 samples, 3 samples had a parasitic burden of 3+, 2 samples had a parasitic burden of 2+ and another 2 samples had a parasitic burden of 1+. *Ascaridia* sp., *Heterakis* sp., and Trematode eggs were identified using Direct Wet Mount technique and Faecal Flotation technique. However, *Giardia* sp. was identified using Modified Ziehl-Neelsen staining technique, but none was found through Direct Wet Mount technique. No *Cryptosporidium* was found in any of the Modified Ziehl-Neelsen staining of the samples. In conclusion, the identification of various types of gastrointestinal parasites with different levels of parasitic burden provides some information on the importance of routine deworming and disinfection practice for captive psittacine bird.

Keywords: *psittacine birds, gastrointestinal parasites, parasitic burden*

1.0 INTRODUCTION

Psittacine birds or psittacidae, is a frequently referred blanket term for birds under the order of Psittaciformes, which are popular as pet birds, either caged or kept in an aviary. It consists of 350 various species that are primarily found in tropical and subtropical regions of the Southern Hemisphere, with the most diverse species found especially in New Zealand and Australia (Heatley and Cornejo, 2015). These birds exhibit broad range of sizes, ranging from as small as the Pygmy parrots, measuring less than 10 cm and weighing 11g to the largest known psittacine bird, the Hyacinth Macaw (*Anodorhynchus hyacinthinus*) at 100 cm and weighing 1500g (Harcourt-Brown, 2009). According to Clements (2000), birds in the order of Psittaciformes are categorised into 2 families, which are the Cacatuidae with 21 species and the Psittacidae with 331 species, including the cockatoos, cockatiels, corellas, lorries, lorikeets, parrots, parakeets, macaws, parrotlets, rosellas and lovebirds. These species are found largely in tropical and subtropical environments, and temperate climates in Southern Australia and New Zealand (Koutsos *et al.*, 2001).

Doneley (2009) stated that captive psittacines carry more severe loads of parasites compared to wild psittacines as captivity contributes to increased exposure to both direct and indirect life cycles of parasites. Captive psittacines are also more prone to parasitic infestations due to the likelihood of poor and inefficient management practice (Ombugadu *et al.*, 2018). Parasites, including the ones that are sub-lethal, are known to be able to harm the host morphology, behaviour, fitness, reproduction and long-term survival (Ombugadu *et al.*, 2018) further contributing to ecological and evolutionary pressures on them. The ecological and evolutionary effects on the host and ecosystem can be understood through calculating the prevalence of the parasites (Loye and Carroll, 1995).

Furthermore, psittacine birds' parasites are known to be host specific, however, some are known to be zoonotic and are harmful to humans (Tsai *et al.*, 1992). For instance, some bird *Cryptosporidium* species are known to have zoonotic potential affecting the human gastrointestinal system, leading to mortality (Makino *et al.*, 2010). Incidence of parasitic infection in psittacines has reduced over the years, as the husbandry and nutrition provided for these animals improved. However, this does not reduce the harm of parasitic infection that may cause health and management issues in psittacines, whether in flocks or individuals (Doneley, 2009).

There are several common gastrointestinal parasites of psittacine birds, such as Coccidia (*Eimeria* spp. and *Neospora* spp.), Protozoa (*Giardia psittaci*, *Trichomonas gallinae* and *Cryptosporidium*), Cestodes (*Raillietina*, *Choanataenia*, *Gastronemia*, *Idiogenes*, and *Amoebotaenia*), Trematode (Doneley, 2009) and with the most frequently found being Nematodes (*Ascarids*, *Capillarids* and *Strongyloides*) according to Gonzalez-Hein *et al.* (2012). These parasites have no symbiotic relationship with the parrots and may be either a primary or an opportunistic pathogen, causing different levels of illnesses to the parrots.

Captive psittacine are chosen for this project as there are increasing interests in keeping psittacine as pets and limited amount of study done on gastrointestinal parasites of psittacine birds in Malaysia. This study will be able to help owners to gain knowledge on the common psittacine's gastrointestinal parasites that can be found in their pet birds, with hopes to improve their management and husbandry practice. This study will also provide beneficial information for veterinarians in decision making for the application of anthelmintics. Klang Valley is chosen as the location to carry out this project as there are

various birds' aviaries, pet owners and pet shops with captive psittacine around the area. Understanding the risk of gastrointestinal parasite infection in captive psittacine has become increasingly important, therefore, the objectives of this study are

1. To identify the different types of gastrointestinal parasites in multiple species of captive psittacines.
2. To study the occurrence of gastrointestinal parasites' burden in captive psittacines.

2.0 LITERATURE REVIEW

2.1 Nematode

Some of the common gastrointestinal nematodes that can be found in psittacine birds are *Ascaridia* sp., *Capillaria* sp., *Heterakis* sp., *Spiruroids* and *Syngamus* sp. (Lee *et al.*, 2005). *Ascaridia* sp. is a roundworm in the family of Ascarididae. It is known as one of the most commonly found gastrointestinal nematodes in birds. According to Doneley (2009), Ascarids are particularly common in budgerigars, cockatiels and Princess parrots. In Malaysia, Lee *et al.* (2005) has recorded a finding of *Ascaridia* sp. ova in hanging parrots and macaws. *Ascaridia hermaphrodita*, *Ascaridia galli*, *Ascaridia platycerci* and *Ascaridia collumbae* are species of Ascarids that have been identified in parrots in publications such as a study by Bernardi *et al.* in 2014 on captive psittacines in Italy and a study by Prathipa *et al.* (2013) in captive psittacines in Chennai, India. In the adult stage, ascarid worms are large, stout and white, with females reaching the size of 12 cm in length (Taylor *et al.*, 2015). *Ascaridia* ova is an ellipsoidal egg with a thick, smooth and colourless shell that allows them to survive in the environment for several months in wet conditions (Lee *et al.*, 2005). *Ascaridia* infection can cause clinical signs such as lethargy, diarrhoea, poor condition and eventually death (Doneley, 2009). It can also lead to intestinal lesions and hepatic lesions (Kajerova *et al.*, 2004) and as well as leading to major and fatal diseases (Greiner and Ritchie, 1994).

Heterakis sp. is another common nematode in the family of Ascarididae. However, cases of *Heterakis* sp. infestation in psittacine birds is not as common as in other birds. Atkinson *et al.* (2009) stated only one *Heterakis gallinarum* infestation was found in a Pink cockatoo (*Cacatua leadbeateri*). It was also obtained in another study on captive

psittacines in Italy, by Bernardi *et al.* in 2014. An adult *Heterakis* sp. is a whitish, small to medium sized worm with an elongated pointed tail that can grow to a maximum size of 1.5 cm long (Taylor *et al.*, 2015), where males are somewhat smaller than females (Atkinson *et al.*, 2009). *Heterakis* sp. infestation in wild birds causes clinical signs such as weakness, diarrhoea, emaciation, dyspnea, and gasping.

Capillaria sp., also known as hairworm or threadworm (Harcourt-Brown, 2009), is one of the most common gastrointestinal parasites in psittacine birds, alongside *Ascaridia* sp. (Gonzalez-Hein *et al.*, 2012). The species that commonly exist in psittacine birds are *Capillaria annulata* and *Capillaria obsignata*. Capillariasis is more common in lovebirds, budgerigars and ring-necked parakeets among psittacine birds (Atkinson *et al.*, 2009). In Malaysia, capillarid ova was previously recorded in hanging parrots according to Lee *et al.* (2005). Capillarid ova possesses bipolar plugs, with thick brown-coloured shells (Atkinson *et al.*, 2009), and having close resemblance with *Trichuris* eggs, while its adult stage can be observed as a whitish filamentous worm with a narrow stichosome oesophagus throughout half of its body length (Taylor *et al.*, 2015). Doneley (2009) stated that clinical signs such as dysphagia, diarrhoea, anorexia, weight loss and oral lesion (Atkinson *et al.*, 2009) can occur due to Capillariasis in psittacine birds. Studies by Prathipa *et al.* in Chennai, India and Bernardi *et al.* in Italy stated findings of *Capillaria* sp. ova in captive psittacines in 2013 and 2014 respectively.

Parasites under the family Strongyloididae are commonly found in small intestines of young mammals, which includes psittacine birds. These colourless and hair-like thin parasites are less pathogenic, but may lead to severe enteritis in immunosuppressed individuals (Taylor *et al.*, 2016). Other clinical signs that may occur in infected birds are

anaemia, inappetence, emaciation and general weakness (Papini *et al.*, 2012). As stated by Rodrigues and Oliviera (2023), strongyloidiasis has reportedly occurred in multiple species of psittacine birds, including Cockatiel (*Nymphicus hollandicus*), Blue and Yellow macaw (*Ara ararauna*), Blue-fronted amazon (*Amazon aestiva*), Rosy-faced lovebirds (*Agapornis roseicollis*), Orange-winged amazon (*Amazon amazonica*) and Rose-ringed parakeet (*Psittacula krameri*). In Malaysia, Lee *et al.* in 2005 found strongyloides through formal-ether sedimentation technique in African Grey parrots, Amazon parrots, cockatoos and macaws. In a study by Papini *et al.* (2012) and Bernardi *et al.* (2013) on captive psittacines in Italy, strongyloides was found in Red lorikeet and Scarlet macaws, and in Peach-faced lovebirds respectively. Another study done by Bayzid *et al.* (2023) on captive psittacines in Chattogram, Bangladesh, obtained strongyloides in budgerigars and White cockatoos.

2.2 Cestode

Cestodes, which are also commonly known as tapeworms, can be found in small intestines of various avian species (Taylor *et al.*, 2015), nonetheless, cestodes are not as common in psittacines as compared to other bird species. One of the most common cestodes in birds is *Raillietina*, which commonly presents mild parasitism and is commonly asymptomatic in parrots (Sciabarassi, 2022). However, clinical signs such as anaemia, weight loss and diarrhoea may occur in infected birds. According to Sciabarassi (2022), *Raillietina* has zoonotic tendencies and can lead to clinical signs in humans. In acute infections, it can cause diarrhoea, while in chronic infections, it may lead to anaemia, cachexia and emaciation. A study by Melo *et al.* in Brazil recorded a finding of *Raillietina* in a captive Blue-fronted amazon (*Amazona aestiva*) in 2013. Another study

by Bayzid *et al.* also stated a discovery of *Raillietina* in Chattogram, Bangladesh in a recent publication in 2023.

2.3 Trematode

Trematodes are parasitic helminths that are flat and shaped like a leaf (Huffman, 2009). It can cause clinical signs that vary depending on species of trematode, parasitic burden and organs affected. Some of the clinical signs are watery and bloody diarrhoea, weakness, emaciation, inability to fly, unsteady gait and disorientation. Huffman (2009) stated that this parasite is divided into two classes, which includes monogenetic trematodes; that are mainly ectoparasites that exist in fish, and digenetic trematodes; that exist in a wide range in wild birds. However, most of the species are not associated with any diseases. According to Taylor *et al.* (2015), species that can be found in wild birds include *Echinostoma*, *Echinoparyphium*, *Hypoderaeum* and *Platynosomum*. Trematode infection in birds depends on its feeding habits and existence of a secondary host, such as molluscs, water snails and insects (Coles, 2007). A study in Malaysia by Lee *et al.* in 2005 stated a finding of trematodes in a group of budgerigars that was identified through the Direct Wet Mount technique.

2.4 Protozoa

According to Doneley (2009), *Coccidia* sp. such as *Eimeria* spp. and *Isospora* spp. can be identified in gastrointestinal mucosa of most psittacine species. These protozoa are host-specific and non-motile. Clinical signs are only obvious in infected birds when stressed, immunosuppressed or when infected with very large numbers of coccidial schizonts. This makes mild infections go unnoticed; however, large infections may cause

severe lesions and eventually lead to death (Ombugadu *et al.*, 2018). *Coccidia* sp. is transmitted from infected birds into the environment through the spread of unsporulated coccidial oocysts shed into faeces. The oocysts will then sporulate in preferably a warm and moist environment. According to Coles (2007), common clinical signs shown in psittacine birds infected with *Eimeria* spp. can range from asymptomatic to mucoid to sanguineous diarrhoea. It can also lead to sudden death. *Isospora* spp. on the other hand is not as pathogenic and not as host specific as *Eimeria* spp. In Malaysia, a study by Lee *et al.* in 2005 shows results of *Eimeria* spp. obtained from faecal samples of budgerigar, cockatoos, lorries and lovebirds through Direct Smear technique and Formalin Ether Sedimentation technique. Moreover, a study done by Prathipa *et al.* in 2013 found *Eimeria* spp. in captive psittacines in pet shops from Chennai, India.

Giardia is a motile intestinal protozoa (Doneley, 2009) that not only affects the gastrointestinal system, but also can lead to abnormal functions of other organs in its host (Presley *et al.*, 2008). Some of the clinical signs shown in a *Giardia* infested bird are enteritis, weight loss, chronic diarrhoea, depression and ruffled feathers, as stated by Doneley (2009). According to Taylor *et al.* (2015), *Giardia* trophozoites have bilaterally symmetrical bodies, pyriform to ellipsoidal shape at a size between 12 to 15 micrometre long. *Giardia psittaci* is a species of *Giardia* that appears in psittacine birds, more commonly in cockatiels, budgerigars (Presley *et al.*, 2008), lovebirds, macaws, parrots and cockatoos (Fudge *et al.*, 1986). In a study done by Lee *et al.* (2005), *Giardia psittaci* was found in budgerigars and parakeets in Malaysia. Other than that, a study done on companion birds in Iran by KazemiLifshagerd in 2023 shows a finding of *Giardia* sp. in psittacine birds.

Cryptosporidium sp. is a protozoa that can infect many vertebrate hosts and is the most common cause of non-viral diarrhoea in humans (Coles, 2007). Coles (2007) also stated that *Cryptosporidium* can cause zoonotic infection specially to immunosuppressed individuals, making it an opportunistic pathogen. According to Atkinson *et al.* (2009), *Cryptosporidium* is able to infect the whole body particularly Bursa of Fabricius, kidney and upper respiratory tract causing respiratory signs, such as rales, coughing, wheezing and dyspnea and gastrointestinal signs, such as enteritis and non - bloody diarrhoea in infected birds. Wild birds can become infected with multiple species of *Cryptosporidium* such as *Cryptosporidium baileyi* and *Cryptosporidium meleagridis* (Atkinson *et al.*, 2009). *Cryptosporidium hominis* and *Cryptosporidium parvum* are the only species that have zoonotic tendencies (Hijawi *et al.*, 2004) and can lead to persistent diarrhoea, abdominal pain and vomiting in humans (Coles, 2007). In a study by Bernardi *et al.* in 2014 in Italy, they were able to find *Cryptosporidium* in captive psittacines.

3.0 MATERIALS AND METHODS

3.1 Sample collection

A total of 50 faecal samples of psittacine birds, consists of 15 samples from small sized psittacine, 20 samples from medium sized psittacine and 15 samples from large sized psittacine were collected from four (4) pet shops, two (2) zoos and a bird park in the area of Klang Valley. Only one sample was collected in each cage and aviary, where cages and aviary with more than one bird were taken as a pooled sample.

Samples are obtained from different sizes of psittacine birds that are categorised into 3 groups, which are small-sized birds, medium-sized birds and large-sized birds. Small-sized group consists of psittacine birds sized between 10 to 33 centimetres, which involves four (4) pooled samples of multiple budgerigars (*Melopsittacus undulatus*), three (3) pooled samples of several cockatiels (*Nymphicus hollandicus*), three (3) conures (*Aratinga* spp.), four (4) parakeets (*Psittacula* spp.) and one (1) lorikeet (*Lorius garrulus*). Medium-sized group consists of psittacine birds sized between 33 to 50 centimetres, which includes six (6) African Grey parrots (*Psittacus erithacus*), three (3) Eclectus parrots (*Eclectus roratus*), two (2) Hahn's macaws (*Diopsittaca nobilis*), two (2) Jardine's parrots (*Poicephalus gularis*), four (4) Amazon parrots (*Amazona* sp.), one (1) White Bellied parrot (*Pionites leucogaster*), one (1) Hawkheaded parrot (*Deroptryus accipitrinus*), and one (1) Black Headed parrot (*Pionites melanocephalus*). Large-sized group consists of psittacine birds sized between 55 to 100 centimetres, such as 10 macaws (*Ara* spp.) and five (5) cockatoos (*Cacatua* spp.).

Table 1 : Species distribution for sample collection

Species	Scientific name	Number of samples
Budgerigar	<i>Melopsittacus undulatus</i>	4
Cockatiel	<i>Nymphicus hollandicus</i>	3
Conure	<i>Aratinga</i> spp.	3
Parakeet	<i>Psittacula</i> spp.	4
Lorikeet	<i>Lorius garrulus</i>	1
African grey parrot	<i>Psittacicus erithacus</i>	6
Eclectus parrot	<i>Eclectus roratus</i>	3
Hahn's macaw	<i>Diopsittaca nobilis</i>	2
Jardine's parrot	<i>Poicephalus gularis</i>	2
Amazon parrot	<i>Amazona</i> sp.	4
White bellied parrot	<i>Pionites leucogaster</i>	1
Hawkheaded parrot	<i>Deroptryus accipitrinus</i>	1
Black headed parrot	<i>Pionites melanocephalus</i>	1
Macaw	<i>Ara</i> spp.	10
Cockatoo	<i>Cacatua</i> spp.	5
Total		50

3.2 Transportation of samples

Samples were collected from droppings in cage trays or aviaries using plastic spoons.

The samples were then put into plastic bags labelled with the location, species and size of birds for ease of identification and put into an ice box to keep the freshness of the samples while being transported by car to the Parasitology Laboratory at Faculty of

Veterinary Medicine. Samples were kept in the refrigerator in the Parasitology Laboratory at 4°C. All samples were collected from superficially healthy birds.

3.3 Faecal examination

All samples were processed through three (3) diagnostic techniques, which are Direct Wet Mount Technique, Faecal flotation Technique and Modified Ziehl Neelsen staining to identify the numerous gastrointestinal parasites present in the faecal samples.


3.3.1 Direct Wet Mount Technique

Direct wet mount technique was done by putting 2 drops of normal saline using a dropper onto a clean glass slide. Then, faecal samples were smeared onto the glass slide using wood sticks. A drop of Lugol's iodine solution was added to stain the smear. Then, a coverslip was put onto the faecal smear. The glass slide was observed under 10x and 40x objective lenses. This technique was used for the identification of helminths ova, oocysts and larvae as well as protozoa and its cyst.

3.3.2 Faecal Flotation Technique

Faecal flotation technique was done by putting 1g of faecal sample into a beaker. The samples were then emulsified with a small amount of water and spatula. Then, sodium nitrate solution with specific gravity of 1.35 was added into the beaker until it reaches 40 ml. The mixture was then strained through a sieve into an empty beaker and poured into a vial until a meniscus is formed at the mouth of the vial. A coverslip was placed over the meniscus. After 20 to 30 minutes, the coverslip covering the vial was lifted and placed over a glass slide. The glass slide was observed under 10x and 40x objective lenses. This technique was used for the identification of helminths ova, oocysts and larvae.

Figure 1: Faecal flotation done using vials with cover slips on the surface



3.3.3 Modified Ziehl-Neelsen Staining

Modified Ziehl-Neelsen staining was done for the identification of acid-fast microorganisms, such as *Cryptosporidium*. Firstly, faecal samples were smeared onto a clean glass slide and let dry for 5 minutes. Then, the samples were fixed with Methanol solution for 3 minutes. The samples were then stained with carbol fuchsin solution for 15 minutes, and rinsed with tap water. Next, the samples were decolourised in acid alcohol for 20 seconds, then rinsed with tap water. The faecal smears were left until completely dry. Then, the smears were counterstained with 1% Methylene Blue solution for 1 minute, and rinsed with tap water and let dry. The stained faecal smears were observed under 40x and 100x objective.

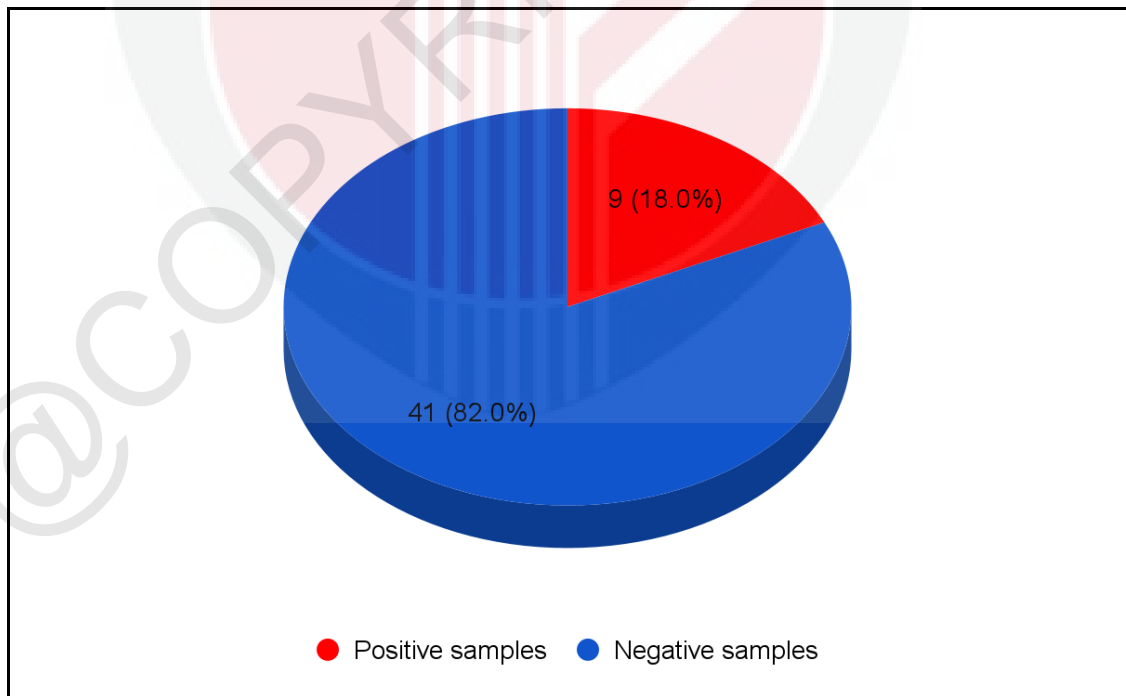
Figure 2: Stainings used for Modified Ziehl-Nielsen staining procedure



4.0 RESULTS

In this study, the results showed an overall positive case of nine (9) samples out of 50 samples, with detection of one (1) or more gastrointestinal parasites. Hence, the percentage for positive samples is 18% (9/50), making the percentage for negative samples at 82% (41/50). The nine (9) positive samples consist of seven (7) single infections and two (2) multiple infections, with a percentage of 14% (7/50) and 4% (2/50) respectively. The two (2) multiple infections both consist of *Ascaridia* sp. and Trematode infestation. It also consists of four (4) positive samples from pet shops and five (5) positive samples from zoos, with a percentage of 44.4% (4/9) and 55.6% (5/9) respectively.

Chart 1: Overall occurrence of gastrointestinal parasites in captive psittacines in Klang Valley area, Malaysia.



The nine (9) positive samples consist largely of seven (7) samples positive with *Ascaridia* sp. infestation (Figure 1 and 2), which is 77.7%, followed by two (2) samples positive with Trematode infestation (Figure 3), which is 22.2%, one (1) sample positive with *Heterakis* sp. infestation (Figure 5) and one (1) sample positive with *Giardia* sp. (Figure 6), both having a percentage of 11.1% each. *Ascaridia* sp., Trematode and *Heterakis* sp. were identified through Direct Wet Mount Technique and Direct Faecal Flotation Technique. *Giardia* sp. was not identified through Direct Wet Mount, however, was found in Modified Ziehl-Neelsen staining. *Cryptosporidium* was not found through the Modified Ziehl-Neelsen staining done.

Chart 2 : Positive samples of gastrointestinal parasites in captive psittacines in Klang Valley area, Malaysia

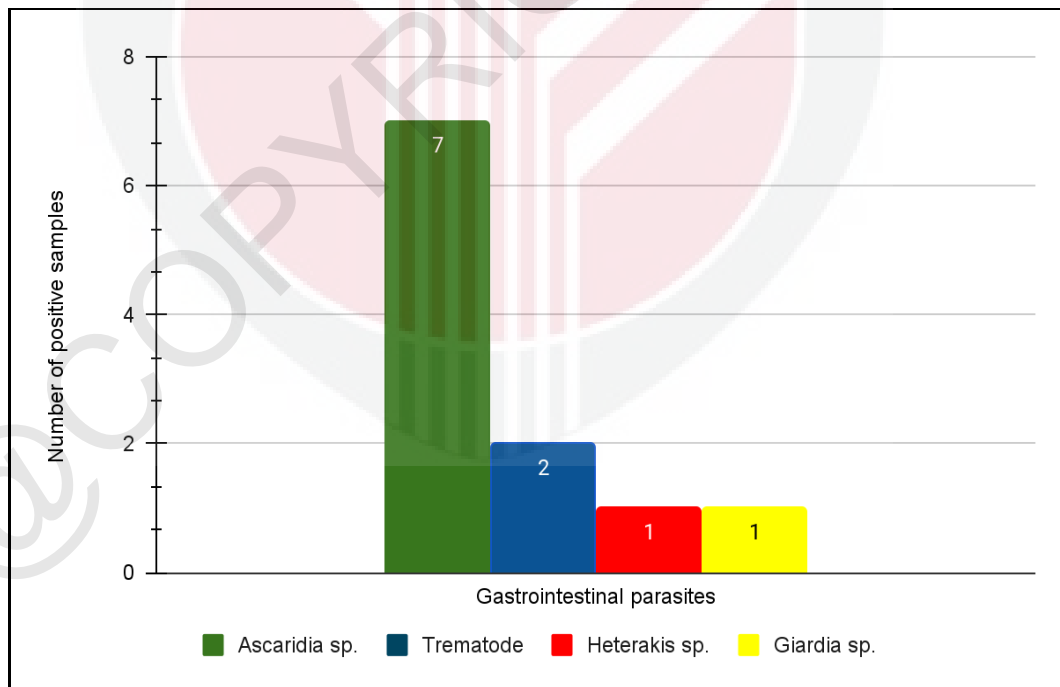

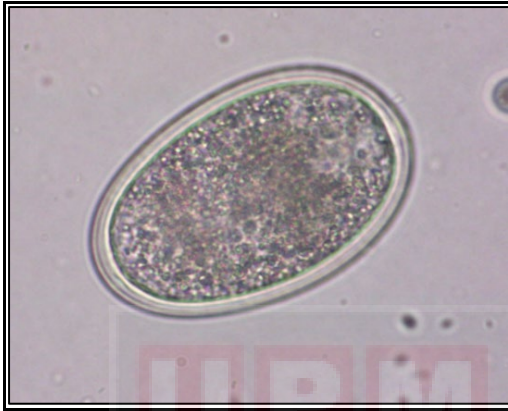


Figure 3: *Ascaridia* sp. ova (400x)

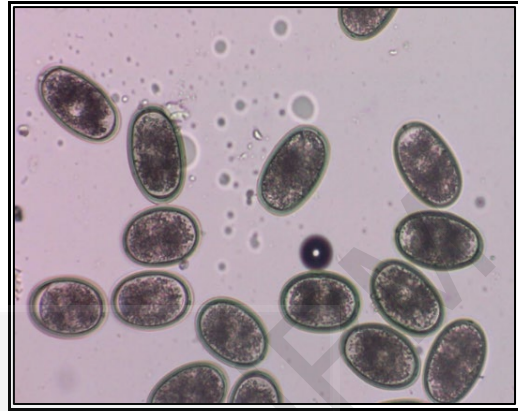


Figure 4: *Ascaridia* sp. ova (100x)

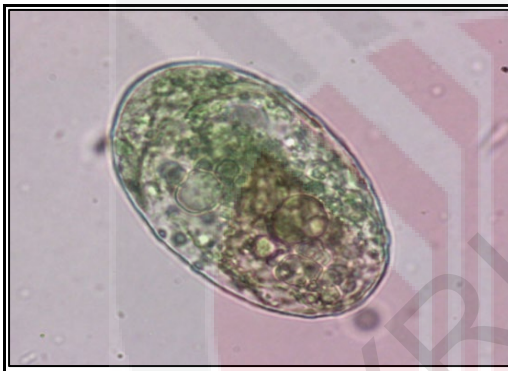

Figure 5: Trematode egg (400x)

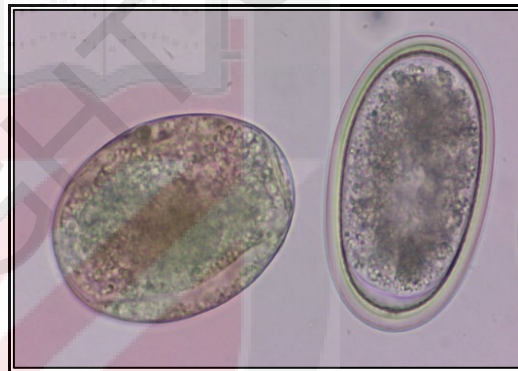


Figure 6: Trematode egg (left) and *Ascaridia* sp. ova (right) (400x)

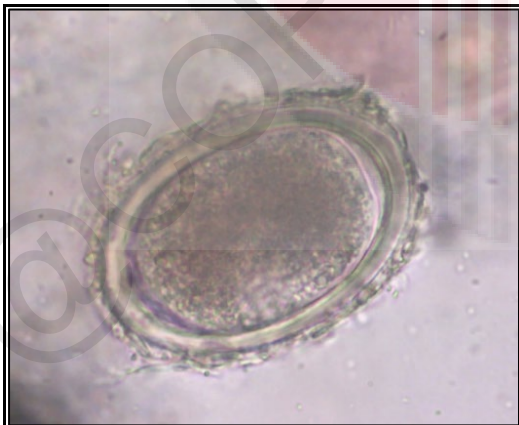


Figure 7: *Heterakis* sp. ova (400x)

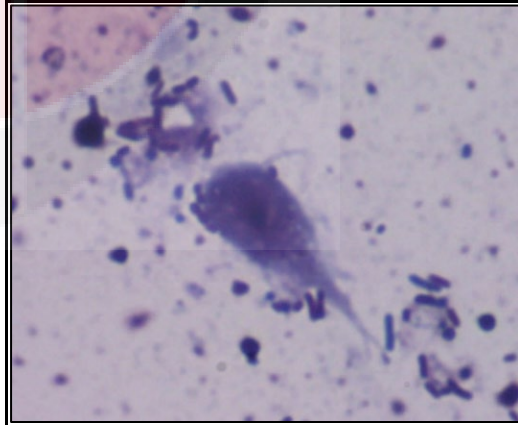


Figure 8: *Giardia* sp. trophozoite (x1000)

As for the parasitic burden, samples positive with *Ascaridia* sp. displayed the highest parasitic burden, where three (3) samples have a parasitic burden of 3+, two (2) samples have a parasitic burden of 2+ and another two (2) samples have a parasitic burden of 1+. Both samples positive for Trematode display a parasitic burden of 1+. Sample positive for *Heterakis* sp. and *Giardia* sp. also displays a parasitic burden of 1+ respectively. Parasitic burden is determined by following the practice done by the Parasitology Laboratory in Faculty of Veterinary Medicine, Universiti Putra Malaysia, where one (1) ova present in some field is labelled as +1, one (1) ova present in almost all fields is labelled as +2, more than one (1) ova present in almost all fields is labelled as 3+ and when the ova is too many to count, it is labelled as 4+.

Table 2: Parasitic burden of gastrointestinal parasites in captive psittacine in Klang Valley area, Malaysia.

Parasitic burden	Number of samples			
	<i>Ascaridia</i> sp.	Trematode	<i>Heterakis</i> sp.	<i>Giardia</i> sp.
+	2	2	1	1
++	2	None	None	None
+++	3	None	None	None
Total	7	2	1	1

Table 3: Reference for parasitic burden scoring provided by Parasitology Laboratory, Faculty of Veterinary Medicine, UPM

Parasitic Burden	Ova/Field
+	1 ova present in some field
++	1 ova present in almost all fields
+++	>1 ova present in almost all fields
++++	Too many ova to count

5.0 DISCUSSION

Gastrointestinal parasites found in this study are *Ascaridia* sp., Trematode, *Heterakis* sp. and *Giardia* sp. The overall occurrence of gastrointestinal parasite in this study, which is 18%, is almost similar to the percentage obtained in a study by Bayzid *et al.* in 2023 from Chattogram, Bangladesh, at a percentage of 19.13% and a study Tsai *et al.* in 1992, from Japan with an overall prevalence of 22.5%. However, this result is higher than the overall positive result obtained from another study done in Malaysia by Lee *et al.* in 2005.

The highest infestation obtained in this study is by *Ascaridia* sp. with a percentage of 77.7%. This is almost equal to the result obtained by a study on captive psittacine in Salvador, Bahia by Ayres *et al.* in 2016, which obtained an occurrence of parasites at a percentage of 65.62%, which is 21 samples out of 32 positive samples. This result is also concurrent with other studies that also obtained *Ascaridia* sp. as the highest infection, which includes a study by Lima *et al.* in 2016 on captive exotic birds in Brazil, with a percentage of 36.5%. However, the result obtained in this study is much higher in comparison to the results obtained by Lee *et al.* in 2005, Bernardi *et al.* in 2014 and Bayzid *et al.* in 2023 at a percentage of 1.5%, 2.44% and 3.46% respectively. The major difference in results may be due to the difference in presence of contaminated food, water, and soil exposed to the birds as gastrointestinal parasites are transmitted through the faecal oral route. It can also be caused by improper antihelminthic practice or antihelminthic resistance occurring at the sampling locations.

Among the common gastrointestinal parasites of psittacine, *Capillaria* sp., *Coccidia* sp., *Cryptosporidium*, *Trichomonas* sp. and Cestodes were among the common gastrointestinal parasites that were not obtained from this study. According to Lima *et al.*

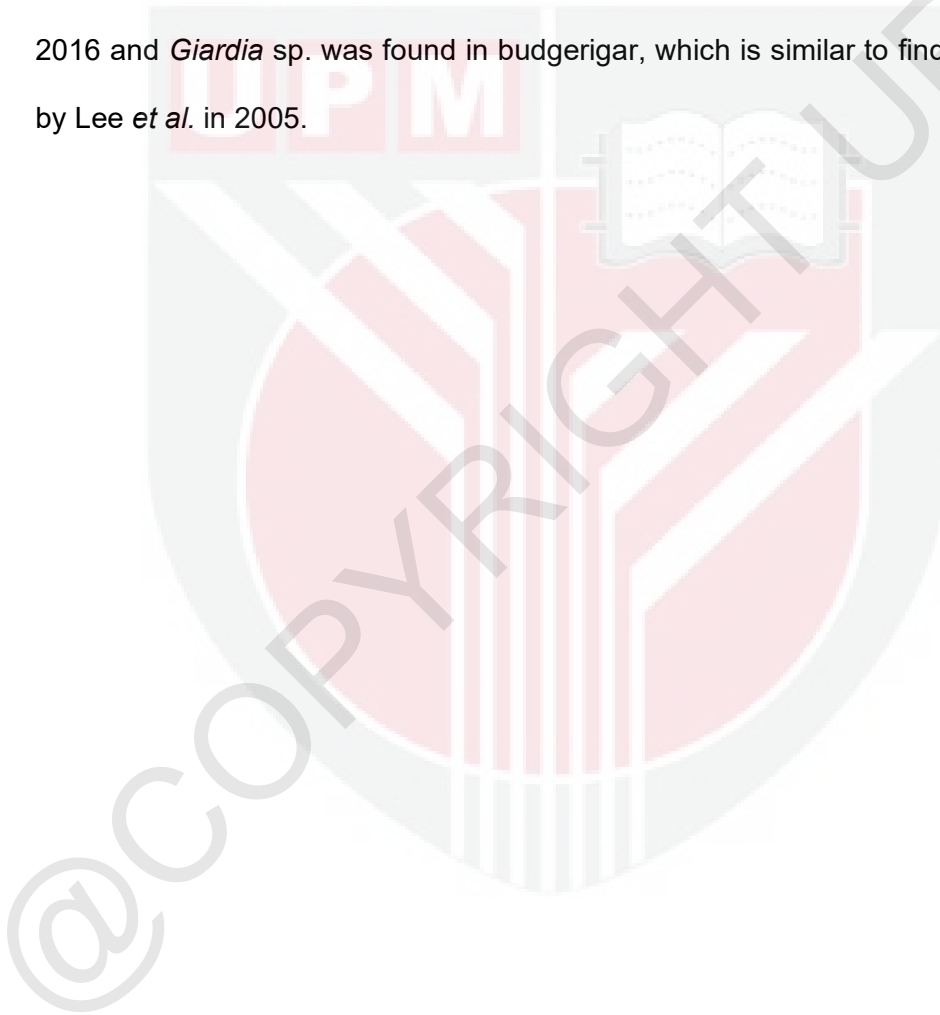
(2016) and Dewir *et al.* (2017), the lack of findings could be due to differences in diagnostic techniques used to identify the parasite, stocking density in the cages, and hygienic measures practised by the owners.

Among the common parasites of psittacine birds, *Capillaria* sp., Cestode such as *Raellitina*, *Giardia intestinalis* and *Cryptosporidium* are the only ones known to have zoonotic tendencies, according to Krautwald-Junghanns *et al.* in a study from 2008. Based on the results obtained in this study, only one sample has a possibility of zoonosis, as it is positive with *Giardia* sp. infestation. However, the species of the *Giardia* sp. can only be identified through further species identification using Polymerase Chain Reaction (PCR) or DNA identification, which is required to confirm its zoonotic risk.

Out of the nine (9) positive samples acquired, only two (2) samples positive with *Ascaridia* sp. were obtained from birds that showed clinical signs of parasitic infestation, where both were observed with watery diarrhoea. Upon faecal examination, both samples were found to have a parasitic burden of 3+. However, another *Ascaridia* sp. positive sample with a parasitic burden of 3+ did not show any clinical signs upon sampling. This could be explained further by Papini *et al.* in 2011, which stated that intestinal parasitic infections are often asymptomatic and will only proceed to show clinical signs, such as anorexia and diarrhoea, when the birds have heavy parasite burden. However, infection does not always lead to severe disease and a full-blown disease may occur in cases where the infected birds are immunocompromised or stressed (Krautwald-Junghanns *et al.*, 2008).

Several gastrointestinal parasites are more prone in specific species of psittacine birds. In this study, *Ascaridia* sp. was found in parakeet, cockatiels and macaw, which is

concurrent with results obtained in studies like Bayzid *et al.* in 2023, Bernardi *et al.* in 2014, and Lee *et al.* in 2005. Trematode was found in cockatiel and macaws in this study. This result can be supported by a similar result that was obtained in a study done by Dewir *et al.* in 2017, who also found Trematode in cockatiels. As for *Heterakis* sp., a positive sample was found in cockatiel, which coincides with a study by Lima *et al.* in 2016 and *Giardia* sp. was found in budgerigar, which is similar to findings from a study by Lee *et al.* in 2005.



6.0 CONCLUSION AND LIMITATIONS

The gastrointestinal parasites found in this study are *Ascaridia* sp., Trematode, *Heterakis* sp. and *Giardia* sp. with an overall occurrence of 18%. As for the parasitic burden, *Ascaridia* sp. shows the highest parasitic burden with three (3) samples having a parasitic burden of 3+, two (2) samples with a parasitic burden of 2+ and two (2) samples with a parasitic burden of 1+. The purpose of this study is to obtain knowledge on the occurrence of gastrointestinal parasites in captive psittacine in Klang Valley area, Malaysia, which may pose as guidance for clinicians and bird owners on the common gastrointestinal parasites available in psittacine birds and the importance of antihelminthic practice and routine disinfection to ensure the holistic wellness of the birds.

The limitations faced in this project are the gastrointestinal parasites found in this study is only identified until its genus and the study was done in a small scope involving the Klang Valley area only. The recommendations that can be suggested for future related projects are further identification of the parasites found using PCR or DNA identification, a procedure that can be done to identify the parasites at species level. Another recommendation is to increase the scope of future studies by including a wider range of sampling location. Furthermore, studies on the association of parasitic infection with antihelminthics used should be considered in the future to obtain more knowledge on occurrence of antihelminthic resistance among psittacine birds in Malaysia.

7.0 REFERENCES

- Atkinson, C. T., Thomas, N. J., & Hunter, D. B. (Eds.). (2009). Parasitic diseases of wild birds. John Wiley & Sons.
- Ayres, M. C. C., Peixoto, M. S. R., da Silva, W. B., Gomes, D. M., Nunes, O. C., Borges, K. B. & de Almeida, M. A. O. (2016). Occurrence of gastrointestinal parasites in psittacines, kept in Ecological Parks in the metropolitan area of Salvador, Bahia. *Revista Brasileira de Medicina Veterinária*, 38(2): 133-136.
- Bayzid, M., Yasir Hasib, F. M., Hasan, T., Hassan, M. M., Masduzzaman, M., Hossain, M. A., & Alim, M. A. (2023): Prevalence of helminth and protozoan infections in pet birds of Chattogram, Bangladesh. *Veterinary Medicine and Science*. 9(1): 548-556.
- Bernardi, B., Fichi, G., Finotello, R., & Perrucci, S. (2014). Internal and external parasitic infections in captive psittacine birds. *Vet Rec*. 174(3): 69.
- Clements, J. F. (2000). *Birds of the World. A Checklist*, (5th Edition). Pica, Mountfield, Sussex.
- Coles B (2007). *Essentials of avian medicine and surgery* (3rd Edition), Wiley.
- de Melo, C. M. F., Oliveira, J. B., Feitosa, T. F., Vilela, V. L. R., Athayde, A. C. R., Dantas, A. F. M., & Febrônio, A. B. (2013). Parasites of Psittaciformes and Accipitriformes in Paraíba state, northeastern Brazil. *Revista Brasileira de Parasitologia Veterinária*. 22: 314-317.

- Dewir, A. W., & Elshanat, S. K. (2017). Preliminary coproscopic examination of ornamental birds in Alexandria Province, Egypt. *Egyptian Veterinary Medical Society of Parasitology Journal (EVMSPJ)*. 13(1): 99-107.
- Doneley, R. J. (2009). Bacterial and parasitic diseases of parrots. *Veterinary Clinics: Exotic Animal Practice*. 12(3): 417-432.
- Fudge, A. M., & McEntee, L. (1986). Avian giardiasis: Syndromes, diagnosis and therapy. In *Proc Assoc Avian Vet*. pp. 155-164.
- Fayer, R. (2010). Taxonomy and species delimitation in *Cryptosporidium*. *Experimental parasitology*. 124(1): 90-97.
- Greiner, E. C., & Ritchie, B. W. (1994). Parasites. *Avian medicine: principles and application*. pp. 1007-29.
- González Hein, G. A., Fredes Martínez, F., Kinsella, M., Larenas, J., & González Acuña, D. (2012). New reports of helminthes in captive exotic psittacine birds in Chile. *University of Chile, Santiago, Chile*.
- Harcourt-Brown, N. H. (2009). *Handbook of Avian Medicine. Psittacine Birds*, 2: 138-168.
- Heatley, J. J., & Cornejo, J. (2015). Psittaciformes. In *Fowler's Zoo and Wild Animal Medicine, Volume 8*. WB Saunders. pp. 172-186.
- Hijawi, N. S., Meloni, B. P., Ng'Anzo, M., Ryan, U. M., Olson, M. E., Cox, P. T., Monis, P. T. & Thompson, R. C. A. (2004). Complete development of *Cryptosporidium parvum* in host cell-free culture. *International journal for parasitology*. 34(7): 769-777.

Huffman, J. E., Klockars, J., Keeler, S. P., & Fried, B. (2009). Histopathological effects of the intramolluscan stages of *Zygocotyle lunata*, *Echinostoma trivolvis*, and *Ribeiroia ondatrae* on *Helisoma trivolvis* and observations on keratin in the trematode larvae. *Parasitology research*. 105: 1385-1389.

Ilić, T., Becskei, Z., Gajić, B., Özvegy, J., Stepanović, P., Nenadović, K., & Dimitrijević, S. (2018). Prevalence of endoparasitic infections of birds in zoo gardens in Serbia. *Acta parasitologica*. 63(1): 134-146.

Kajerova, V., Barus, V., & Literak, I. (2004). Nematodes from the genus *Ascaridia* parasitizing psittaciform birds: a review and determination key. *Veterinárni medicína*. 49(6): 217.

KazemiLifshagerd, F., BehrouziNasab, O., Koochakzadeh, A., & Kazemnezhad, M. (2023). Evaluation of Giardiasis in Companion Birds in Mashhad, Iran. *Journal of World's Poultry Science*. 2(3): 20-23.

Krautwald-Junghanns, M., Orosz, S. E., & Tully Jr, T. (2008). *Essentials of avian medicine and surgery*. John Wiley & Sons.

Koutsos, E. A., Matson, K. D., & Klasing, K. C. (2001). Nutrition of birds in the order Psittaciformes: a review. *Journal of Avian Medicine and Surgery*. 15(4): 257-275.

Lee, N. Y. P., Jalila, A., Amin-Babjee, S. M., Lee, C. C., & Maizatul, A. M. (2005).

Prevalence study of gastrointestinal parasites in psittacine birds in the Klang Valley. In Harmonising HALAL practices and food safety from farm to table.

Proceedings of the 17th Veterinary Association Malaysia Congress in conjunction with Malaysia International Halal Showcase (MIHAS) 2005; 27-30 July 2005.

Universiti Putra Malaysia Press. pp. 77-79.

Lima, V. F. S., Bezerra, T. L., Andrade, A. F. D., Ramos, R. A. N., Faustino, M. A. D. G.,

Alves, L. C., & Meira-Santos, P. O. (2016). Gastrointestinal parasites of exotic birds living in captivity in the state of Sergipe, Northeastern Brazil. *Revista Brasileira de Parasitologia Veterinária*. 26: 96-99.

Loye, J., & Carroll, S. (1995). Birds, bugs and blood: avian parasitism and conservation.

Trends in Ecology & Evolution. 10(6): 232-235.

Makino, I., Abe, N., & Reavill, D. R. (2010). *Cryptosporidium* avian genotype III as a

possible causative agent of chronic vomiting in peach-faced lovebirds (*Agapornis roseicollis*). *Avian Diseases*. 54(3): 1102-1107.

Ombugadu, A., Echor, B., Jibril, A., Angbalaga, G., Lapang, M., Micah, E., Njila, H., Isah,

L., Nkup, C., Dogo, K., & Anzaku, A. (2018). Impact of parasites in captive birds: a review. *Curr Res Environ Biodivers*. 2019(04): 1-12.

Papini, R., Girivetto, M., Marangi, M., Mancianti, F., & Giangaspero, A. (2012).

Endoparasite infections in pet and zoo birds in Italy. *The scientific world journal*, 2012.

- Prathipa, A., Jayathangaraj, M. G., Gomathinayagam, S., & Thangavelu, A. (2013). Prevalence of endoparasites in captive psittacine birds belonging to pet shops and private residences in and around Chennai. *International Journal of Veterinary Science*. 2(2): 58-60.
- Presley, S. J., & Willig, M. R. (2008). Intraspecific patterns of ectoparasite abundances on Paraguayan bats: effects of host sex and body size. *Journal of Tropical Ecology*. 24(1): 75-83.
- Rodrigues, H. L. D. S., & Oliveira, V. J. D. (2023). Parasitic infections in wild birds of the family psittacidae: the relationship between zoonosis and the one health. Faculdade de Medicina Veterinária, Universidade Federal de Uberlândia, Brasil.
- Sciabarrasi, A. (2022). Raillietiniasis in cacique parrot (*Deroytyus accipitrinus fuscifrons*) and its importance as a zoonotic disease. *Amazonia Investiga*. 11(55): 220-225.
- Taylor, M. A., Coop, R. L., & Wall, R. L. (2015). *Veterinary parasitology*. John Wiley & Sons.
- Tsai, S. S., Hirai, K., & Itakura, C. (1992). Histopathological survey of protozoa, helminths and acarids of imported and local psittacine and passerine birds in Japan. *Japanese Journal of Veterinary Research*. 40(4): 161-174.