



UNIVERSITI PUTRA MALAYSIA

**OCCURRENCE OF ECTOPARASITIC INFECTIONS AND ITS
HISTOLOGICAL CHANGES IN SPOTTED GREEN PUFFERFISH,
Dichotomyctere nigroviridis (Marion de Procé, 1822)
IN BAGAN LALANG, SELANGOR.**

NUR AINAA HUSNA BINTI ZULKEPLI

**Ip
FPV 2023 1516**

**OCCURRENCE OF ECTOPARASITIC INFECTIONS AND ITS
HISTOLOGICAL CHANGES IN SPOTTED GREEN PUFFERFISH,
Dichotomyctere nigroviridis (Marion de Procé, 1822)
IN BAGAN LALANG, SELANGOR**

NUR AINAA HUSNA BINTI ZULKEPLI

A project paper submitted to the
Faculty of Veterinary Medicine, Universiti Putra Malaysia
In partial fulfilment of the requirement for the
DEGREE OF DOCTOR OF VETERINARY MEDICINE
FACULTY OF VETERINARY MEDICINE
Universiti Putra Malaysia Serdang,
Selangor Darul Ehsan.

DECEMBER 2023

CERTIFICATIONS

It is hereby certified that we have read this project paper entitled “Occurrence of ectoparasites in pufferfish, *Dichotomyctere nigroviridis*. In Bagan Lalang, Selangor” by Nur Ainaa Husna Binti Zulkepli and in our opinion it is satisfactory in terms of scope, quality, and presentation as partial fulfill of the requirement for the course VPD 4999 – Project.

DR NUR DIYANA MOHAMAD TAHIR
DVM (UPM), PhD (UPM)
Senior Lecturer
Faculty of Veterinary Medicine
Universiti Putra Malaysia
(Supervisor)

DR NOR AZLINA ABDUL AZIZ
DVM (UPM), PhD (BRISTOL)

Senior lecturer
Faculty of Veterinary Medicine
Universiti Putra Malaysia
(Co-supervisor)

DR MOHD FUAD BIN MATORI
DVM (UPM)

Veterinary Officer
Faculty of Veterinary Medicine
Universiti Putra Malaysia
(Co-supervisor)

ACKNOWLEDGEMENTS

First of all, I would like to thank Allah S.W.T. The Entirely Merciful and The Bestower of Mercy for providing me the strength and health to complete my final year project.

These six weeks of FYP were very challenging for me. Thus, I would like to express my gratitude to my magnificent supervisor, Dr. Diyana, and my co-supervisors; Dr. Azlina and Dr. Fuad for all of their amazing support and guidance throughout this project. I am honored to be supervised by them and I wish them the happiness and success in their life. Thank you for providing me with the opportunity and courage to finish this project. My journey throughout the project would not have been easy without my helpful partner, Faiz Fikri.

Most importantly, I would express my biggest appreciation to both of my parents, Zulkepli and Hazura for being the greatest gift in my life. May Allah bless both of you with health and a peaceful heart. Not to forget, thank you to my two brothers for their endless support and trust.

To my close friends who were there since the first day of my degree; Adlina, Farra, Aimi, Nurien, and Hanis, thank you for the endless support and encouragement we give to each other, I am super proud of us. To my best friend, Rania, thank you for being a safe space for me. To friends who supported me from afar, Zulhelmi, and Farah, thank you for trusting me.

I would also like to thank all the staff who helped me endlessly, especially En Azmi from AAHU and Puan Latiffah and Puan Aishah from the histopathology lab; your bright personality and kindness helped me throughout the project. To my friends who spent days in Pantai Bagan Lalang to help collect samples, thank you for making the days there more bearable.

TABLE OF CONTENT

| | |
|--|-------------|
| TITLE..... | I |
| CERTIFICATIONS..... | II |
| ACKNOWLEDGEMENTS..... | IV |
| LIST OF TABLES..... | VII |
| LIST OF FIGURES..... | VIII |
| ABSTRAK | IX |
| ABSTRACT | XI |
| 1.0 INTRODUCTION..... | 1 |
| 1.1 BACKGROUND | 1 |
| 1.2 HYPOTHESIS | 2 |
| 1.3 OBJECTIVES | 2 |
| 2.0 LITERATURE REVIEW | 3 |
| 2.1 SPOTTED GREEN PUFFERFISH | 3 |
| 2.2 BAGAN LALANG, SELANGOR | 3 |
| 2.3 ECTOPARASITES OF BRACKISHWATER AND FRESHWATER FISHES | 4 |
| 3.0 MATERIALS AND METHODS | 5 |
| 3.1 FISH SAMPLE | 5 |
| 3.2 EXAMINATION OF THE SPECIMENS | 5 |
| 3.3 IDENTIFICATION, PREVALENCE AND INTENSITY OF ECTOPARASITES | 6 |
| 3.4 HISTOPATHOLOGICAL ANALYSIS | 6 |

| | |
|---|-----------|
| 3.5 DATA ANALYSIS..... | 8 |
| 4.0 RESULTS..... | 8 |
| 4.1 WATER QUALITY TEST | 8 |
| 4.2 PREVALENCE AND INTENSITY OF ECTOPARASITES | 9 |
| 4.3 HISTOPATHOLOGY ANALYSIS..... | 11 |
| 4.3.1 HISTOPATHOLOGY RESULT OF GILLS IN JUVENILE FISH | 11 |
| 4.3.2 HISTOPATHOLOGY RESULTS OF GILLS IN ADULT FISH | 12 |
| 4.3.3 HISTOPATHOLOGY RESULTS OF GILLS IN ADULT AND JUVENILE FISH | 14 |
| 4.3.4 HISTOPATHOLOGY RESULTS OF SKIN..... | 16 |
| 5.0 DISCUSSION | 18 |
| 6.0 CONCLUSION..... | 23 |
| 7.0 RECOMMENDATIONS..... | 24 |
| 8.0 REFERENCES..... | 25 |

LIST OF TABLES

| | | |
|-----------|---|----|
| Table 1.0 | Water quality parameters of water sample from sampling location | 8 |
| Table 2.0 | Prevalence and intensity of ectoparasites in gills for juvenile and adult <i>Dichotomyctere nigroviridis</i> | 10 |
| Table 3.0 | Histopathology scoring in gills of juvenile <i>Dichotomyctere nigroviridis</i> | 11 |
| Table 4.0 | Histopathology scoring in gills of adult <i>Dichotomyctere nigroviridis</i> | 12 |
| Table 5.0 | Histopathology evaluation on skin of juvenile <i>Dichotomyctere nigroviridis</i> | 16 |
| Table 6.0 | Histopathology evaluation on skin of adult <i>Dichotomyctere nigroviridis</i> | 17 |

LIST OF FIGURES

| | | |
|------------|--|----|
| Figure 1.0 | Criteria of histopathology scoring of gills | 7 |
| Figure 2.0 | <i>Dactylogyrus spp.</i> in gills of <i>Dichotomyctere nigroviridis</i> | 9 |
| Figure 2.1 | <i>Dactylogyrus spp.</i> in gills of <i>Dichotomyctere nigroviridis</i> | 10 |
| Figure 3.0 | Bar chart of histopathological scoring of gills in juvenile <i>Dichotomyctere nigroviridis</i> | 12 |
| Figure 4.0 | Bar chart of histopathological scoring of gills in adult <i>Dichotomyctere nigroviridis</i> | 14 |
| Figure 5.0 | Bar chart of histopathological scoring of gills in juvenile and adult <i>Dichotomyctere nigroviridis</i> | 14 |
| Figure 6.0 | <i>Dactylogyrus spp.</i> in gills of <i>Dichotomyctere nigroviridis</i> | 15 |
| Figure 6.1 | <i>Dactylogyrus spp.</i> in gills of <i>Dichotomyctere nigroviridis</i> | 15 |
| Figure 6.2 | Presence of cellular anomalies, lamellar fusion and lamellar edema in gills of <i>Dichotomyctere nigroviridis</i> | 16 |
| Figure 7.0 | Inflammatory cells in skin of <i>Dichotomyctere nigroviridis</i> | 17 |
| Figure 8.0 | Pie chart of skin inflammation in <i>Dichotomyctere nigroviridis</i> | 18 |

ABSTRAK

Abstrak daripada kertas projek yang dikemukakan kepada Fakulti Perubatan Veterinar untuk memenuhi sebahagian daripada keperluan VPD 4999 – Projek Ilmiah Tahun Akhir.

KEJADIAN JANGKITAN EKTOPARASIT DAN PERUBAHAN HISTOLOGI DALAM IKAN BUNTAL GIGI KUPANG, *Dichotomyctere nigroviridis* (Marion de Procé, 1822) DI BAGAN LALANG, SELANGOR.

Oleh

Nur Ainaa Husna Binti Zulkepli

2023

Penyelia: Dr Nur Diyana Binti Mohamad Tahir

Penyelia bersama: Dr Nor Azlina Binti Abdul Aziz & Dr Mohd Fuad Bin Matori

Ikan buntal gigi kupang, *Dichotomyctere nigroviridis* mampu hidup di kedua-dua air tawar dan air masin, dan ia boleh didapati dengan mudah di muara sungai Malaysia.

Fauna parasit dalam ikan buntal boleh memberikan maklumat lanjut mengenai interaksi perumah haiwan-parasit yang mungkin mempunyai kesan buruk terhadapnya atau tidak sama sekali. Tujuan kajian ini adalah untuk mengesan kehadiran ektoparasit yang menetap pada kulit, sirip, dan insang dari *Dichotomyctere nigroviridis* dan kesan pada perubahan histopatologi. Sebanyak 16 ikan buntal yang terdiri daripada 3 ikan juvenil dan 13 ikan dewasa telah dikumpulkan dari tempat pengambilan sampel di Bagan Lalang, Selangor melalui kaedah memancing dan

pengumpulan ikan dari nelayan. Sampel-sampel kulit, pengikisan sirip dan pengambilan insang dikumpulkan untuk 'direct wet mount' dan pengenalpastian ektoparasit. Sampel kulit dan insang diambil dan diawet di dalam larutan Davidson untuk proses penilaian histopatologi. Bilangan parasit antara ikan muda dan ikan dewasa digunakan untuk analisis statistik menggunakan 'T-test' dalam GraphPad Prism versi 10. Penilaian histopatologi dilakukan dengan membahagikan luka mengikut 5 kriteria yang berbeza iaitu hiperplasia lamelar, penggabungan lamelar, anomali selular, dan edema lamelar dengan skor dari 0 hingga 3, dan kriteria tambahan bagi kehadiran dan ketiadaan ektoparasit. Untuk analisis histopatologi, 'T-test' yang sama juga digunakan untuk membandingkan skor histopatologi bagi setiap kriteria antara ikan muda dan ikan dewasa, antara bilangan parasit pada ikan dewasa dan ikan muda dengan skor histopatologi, dan juga untuk skor histologi kulit antara ikan muda dan ikan dewasa. Ektoparasit yang ditemui dalam kajian ini ialah *Dactylogyrus* spp. terutamanya ditemui pada insang. Kajian ini juga mendedahkan bahawa tiada perbezaan yang signifikan bagi parasit antara ikan muda dan ikan dewasa. Walau bagaimanapun, terdapat perbezaan yang signifikan antara bilangan parasit pada ikan dewasa dengan perubahan histopatologi. Antara pelbagai jenis penilaian histopatologi, anomali selular mencatat skor tertinggi dengan kiraan 90% daripada sampel mempunyai degenerasi sel dan diikuti oleh kriteria tambahan dengan sekitar 80% sampel ikan yang diperhatikan. Semua pencarian daripada *Dichotomyctere nigroviridis* boleh digunakan sebagai penyelidikan preliminar ektoparasit pada ikan buntal dan untuk kajian masa depan spesies ini.

Kata kunci: *Dichotomyctere nigroviridis*; Ikan buntal gigi kupang; Bagan Lalang; kezaliman; ektoparasit

ABSTRACT

An abstract of the project paper presented to the Faculty of Veterinary Medicine in partial fulfillment of the course VPD4999 – Final Year Project.

**OCCURRENCE OF ECTOPARASITIC INFECTION AND ITS
HISTOLOGICAL CHANGES IN SPOTTED GREEN PUFFERFISH,
Dichotomyctere nigroviridis (Marion de Procé, 1822)
IN BAGAN LALANG, SELANGOR.**

by

Nur Ainaa Husna Binti Zulkepli**2023****Supervisor:** Dr Nur Diyana Binti Mohamad Tahir**Co-supervisors:** Dr Nor Azlina Binti Abdul Aziz & Dr Mohd Fuad Bin Matori

The spotted green pufferfish, *Dichotomyctere nigroviridis* was able to live in both freshwater and brackish water, and it can be easily found in the estuaries of Malaysia. The parasitic fauna in the pufferfish may provide further information on the host-parasite interaction that may either have a detrimental effect on it or none at all. The purpose of this study was to detect the presence of ectoparasites harboring the skins, fins, and gills of the *Dichotomyctere nigroviridis* and the effects on histopathological changes. A total of 16 pufferfish comprising 3 juveniles and 13 adults were collected from the sampling site in Bagan Lalang, Selangor through fishing and collection from the fishermen. The skin scraping, fin scraping and gills samples were collected for direct wet mount to identify the ectoparasites. The skin and gills samples were taken

and preserved in Davidson's solution histopathological evaluation process. The number of parasites between juveniles and adults was used for statistical analysis using a t-test in GraphPad Prism version 10. The histopathological evaluation was done by dividing the lesions based on 5 different criteria which were lamellar hyperplasia, lamellar fusion, cellular anomalies, and lamellar edema with scores from 0 to 3, and ancillary criteria for the presence and absence of ectoparasites. For histopathological analysis, the same t-test was also used to compare the histopathological score for each criterion between juveniles and adults, between the number of parasites in adults and juveniles with the histopathological score, and also for the skin histopathological score between juveniles and adults. The ectoparasites found in this study was *Dactylogyrus* spp. mainly found in the gills. This study also revealed that there was no significant difference in parasites between adults and juveniles. However, there was a significant difference between the number of parasites in adults with histopathological changes. Among the different kinds of histopathological scoring, cellular anomalies recorded the highest score with about 90% of the sample having degeneration of cells followed by ancillary criteria with about 80% of fish samples observed. All the findings from the *Dichotomyctere nigroviridis* can be used as preliminary ectoparasite investigation in pufferfish and for future studies of the species.

Keywords: *Dichotomyctere nigroviridis*; Spotted Green pufferfish; Bagan Lalang; prevalence; ectoparasite

1.0 INTRODUCTION

1.1 BACKGROUND

Spotted Green Pufferfish, *Dichotomyctere nigroviridis* can be found in the coastal freshwater around the South and Southeast Asia region, especially in seaside creeks, rivers, or marshes. However, the habitat varies depending on the species which can be in brackish water or from brackish water to freshwater (Zhu et al., 2021). This fish is a balloon-shaped fish that can inflate itself enormously (Ahmed Chowdhury et al., 2019). The average size of this pufferfish is about 14 to 17 cm in length. The upper body part is greenish yellow with an abundant amount of black spots layering on it and the abdomen is white. This fish has been locally harvested for food and medicine for centuries (Kawata, 2012), and also used as an ornamental fish due to its unique appearance of skin colour and patterns.. Knowing parasite occurrence in this species is important in understanding the ecosystem's responses to environmental stressors (Bennett et al. 2022). Changes in the number of parasitic species or individual parasites indicate environmental impact (Sures et al., 2017; Vidal-Martínez et al., 2019, 2022)

Information on ectoparasites in *Dichotomyctere nigroviridis* is not well known due to the limited research on this fish species. Therefore, the study objective was made. It can be expected that this fish species may carry multiple ectoparasites. The findings in Bagan Lalang, Selangor may help to better understand the effects of parasite infection on wild fish population and further expand as a disease monitoring tool in surrounding farms to increase our knowledge on the impacts of aquaculture. Furthermore, increased interest in aquaculture will increase awareness of parasites that may affect fish health, growth, and survival (Morsy et al., 2012).

1.2 HYPOTHESIS

Null Hypothesis 1: There are no detectable ectoparasites residing in the skin, fins, and gills of the *Dichotomyctere nigroviridis*

Alternative Hypothesis 1: There are detectable ectoparasites residing in the skin, fins, and gills of the *Dichotomyctere nigroviridis*

Null Hypothesis 2: Ectoparasites infection is not associated with histopathological changes in the skin, gills, and fins of the *Dichotomyctere nigroviridis*.

Alternative Hypothesis 2: Ectoparasites infection is significantly associated with histopathological changes in the skin, gills, and fins of the *Dichotomyctere nigroviridis*

1.3 OBJECTIVES

Objective 1: To detect the presence of ectoparasites on the skin, gills, and fins of the *Dichotomyctere nigroviridis* in Bagan Lalang, Selangor.

Objective 2: To evaluate the histopathological changes on the skin, gills and fins in the *Dichotomyctere nigroviridis* in Bagan Lalang, Selangor.

2.0 LITERATURE REVIEW

2.1 SPOTTED GREEN PUFFERFISH

Spotted Green Pufferfish, *Dichotomyctere nigroviridis* is a locally known pufferfish due to its attractive olive green color with black blotches pattern covering the upper part of its body and white color on its sides and lower part (Ahmed Chowdhury et al., 2019). The broad head and back together with the presence of 4 teeth make it even more unique and interesting to explore. It can be found widely in South and Southeast Asia with a variety of habitats for different species with some residing in brackish water and others inhabiting brackish water to freshwater (Zhu et al., 2021). Due to that, this fish can be located in the estuaries and rivers (Santini et al., 2013). This fish can expand itself like a balloon once it is triggered. The body size may reach up to 17 cm in length once it reaches maturity. Considering pufferfish threats a poisonous effect due to the presence of potent neurotoxins which is tetrodotoxin (TTX) and its analogs (Islam et al., 2018), it limits the amount of research done on it. Since TTX has become one of the deadliest toxins (Melnikova et al., 2022), the study on ectoparasites residing on it may help obtain more information on whether the toxins could influence the symbiotic life of this fish.

2.2 BAGAN LALANG, SELANGOR

Bagan Lalang is a coastal beach located in the district of Sepang, in the southwest region of Selangor. The term "Bagan" signifies the existence of a pier, distinguishing the locality as a community with jetties. Over the last ten years, there has been swift growth in both housing and tourism in this coastal region, primarily attributed to its proximity to the Kuala Lumpur International Airport and the Sepang

International Circuit (Dada et al., 2013). According to a publication, this region has gained recognition as a fishing village within the district (Zin Mohamed & Hassan, 2017).

2.3 ECTOPARASITES OF BRACKISH AND FRESHWATER FISHES

All living things are susceptible to the infections of parasites including fishes. Indahsari et al. (2019) mentioned that parasites are organisms that can take advantage of other hosts by living on or inside of them to obtain food. It also specified that parasites are divided into ectoparasites and endoparasites based on the organ affected. It also stated that the immune system of fish may decrease due to the parasites' attack, hence it exposes the fish to susceptible to disease transmission. Ectoparasites are organisms that live on the outer surface of the fish's body such as skin, fins, and gills. The ectoparasites infecting fish are grouped into three different groups; the protozoan group, the monogenean group, and the crustacean group. Based on Klinger & Floyd (2013), protozoans are single-celled organisms that live freely in the aquatic environment without the need for an intermediate host to reproduce, similar to the monogenean trematode which has a direct life cycle that commonly invades skins, fins, and gills making it host and site-specific. It also mentioned that crustaceans can be seen easily with the naked eye and pose as threatening problem in the wild population.

3.0 MATERIALS AND METHODS

3.1 FISH SAMPLE

A total of 16 pufferfishes, *Dichotomyctere nigroviridis* were collected for this study and obtained from the estuary sites in Pantai Bagan Lalang, Selangor. The collection methods are from local fishermen and catching with fishing poles. All the fishes were kept alive in an aerated container until it was dissected in the laboratory under IACUC approval (UPM/IACUC/AUP-U008/2023). The water quality test was done using ProQuatro Portable Multiparameter Water Quality Meter (YSI Inc., USA) probe at the sampling site by taking a small portion of the water as a sample.

3.2 EXAMINATION OF THE SPECIMENS

The pufferfish were examined and dissected one by one by placing them on a damp cloth. Skin scrapping and fin scrapping were first done using a blade to obtain the mucus sample and placed on a glass slide. A drop of methylene blue was used and covered with the cover slip. Both sides of the gills were collected and placed onto a petri dish with multiple drops of normal saline to prevent it from drying out. The length and width of the gills were recorded. A quarter portion of the gills was taken to be examined under the light microscope. The gill arch was cut away and only left with the gills lamellar. It was then placed on a glass slide with a drop of methylene blue and covered with a cover slip. The gills sample was then examined under the light microscope. The other portion of the gills are kept in a Davidson's solution for fixation for histological analysis. Next, the skin was obtained by cutting onto the pectoral and caudal region which then be placed inside the Davidson's solution for fixation.

3.3 IDENTIFICATION, PREVALENCE, AND INTENSITY OF ECTOPARASITES

The microscopic observation of the parasite was done using the light microscope through the pictorial guide by (Klimpel et al., 2019). Once the parasites are identified, the data will be tabulated and the prevalence and intensity of the parasites will be calculated with the formula adapted from (Muchlisin et al., 2014)

The prevalence of parasites:

$$\text{Prevalence (\%)} = (\sum \text{infected fish} / \sum \text{examined fish}) \times 100\%$$

The intensity of parasites:

$$\text{Intensity} = \sum \text{parasites found} / \sum \text{infected fish}$$

3.4 HISTOPATHOLOGICAL ANALYSIS

The skin and gill samples were fixed in Davidson's solution before being used for the histological process. The samples were left overnight before further action. Once the samples were left overnight, they were trimmed into the desired shape and then placed into cassettes which were soaked in the Davidson's solution again before being sent to the Histopathological laboratory for further process. After being left overnight, the samples will then be arranged for embedded in the paraffin wax. Once the wax becomes hardened, it will then be sliced using the microtome and placed on the glass slides. The slides were all left for drying overnight and only then it further go through the staining and mounting process.

The histopathology scoring of the gills was done based on five criteria which are lamellar hyperplasia, lamellar fusion, cellular anomalies, lamellar edema, and

ancillary criteria. This method of scoring was adapted from Mitchell et al., (2012) as stated in the table below (Figure 1.0).

Figure 1.0 Criteria of histopathology scoring of gills adapted from Mitchell *et al.* (2012)

| Pathology (score) | Lamellar hyperplasia | Lamellar fusion | Cellular anomalies | Lamellar oedema |
|---|---|---|--|--|
| Index criteria | | | | |
| None (0) | Not significant – none or very minor | Not significant- none or very minor | none | none |
| Mild (1) | Mild increase in epithelial cells – low-level of focal or widespread hyperplasia, affecting <10% of gill tissue | Occasional focal fusion of filaments – <10% of gill tissue affected | Scattered occasional degenerating or necrotic cells or focal areas of sloughing | Epithelio-capillary separation with proteinaceous fluid in the epithelia-capillary space: <10% of gill tissue affected |
| Moderate (2) | Moderate widespread or multifocal hyperplasia, affecting 10-50% of the tissue | Multifocal areas of fusion (moderate widespread hyperplasia affecting 10-50% of gill tissue) interspersed with normal gill tissue | Degenerating cells, necrotic cells and/or cell sloughing in multifocal areas throughout the tissue | 10-50% of gill tissue affected |
| Severe (3) | Extensive lamellar hyperplasia, >50% of gill tissue affected | Extensive fusion and loss of normal architecture, >50% if gill tissue affected | Widespread necrosis, degeneration and/or sloughing visible throughout section | >50% of gill tissue affected |
| Ancillary criteria— presence or absence of parasites | | | | |
| Presence (1) | | | | |
| Absence (0) | | | | |

3.5 DATA ANALYSIS

All the data was tabulated by using Microsoft Excel and statistical analysis was done by using GraphPad Prism version 10. Shapiro-Wilk test was used to test the normality of the number of parasites between juvenile and adult fish. Since the data did not pass normal distribution, the Mann-Whitney test was selected as a non-parametric analysis.

As for the histopathology scoring analysis, the data tabulation was done using Microsoft Excel, and statistical analysis was done using GraphPad Prism version 10. Once again, Shapiro-Wilk test was selected to test the normality of each histopathological criteria between juvenile and adult fish, the correlation between adult and juvenile with their histopathological scoring, and also the histopathological scoring of skin between the two groups of fish. The percentage of fish for each histopathological scoring was calculated and presented in pie-chart form using Microsoft Excel.

4.0 RESULTS

4.1 WATER QUALITY TEST

Table 1.0: Water quality parameters of water sample at the sampling location of Bagan Lalang, Selangor

| Parameter | Value |
|-------------|-----------|
| Temperature | 28.8°C |
| pH | 7.35 |
| DO | 4.35 mg/L |
| Ammonia | 3.34 mg/L |
| Salinity | 25.12 ppt |

The water quality test presented in Table 1 below concluded the normal pH range for brackish fishes is 7.8 to 8.4 and the result shows 7.35 which is slightly lower than the normal. But since this pufferfish can live in both brackish and freshwater conditions, it can still be considered within range since the normal range for freshwater pH is 7.0 to 7.6. The other parameters are also within the normal range. Thus, it does not pose any threats.

4.2 PREVALENCE AND INTENSITY OF ECTOPARASITES

The parasite found in this study is *Dactylogyrus* spp. which was only seen in the gills. However, the skin scraping and fins scraping have no record of parasites observed. *Dactylogyrus* spp. was classified in the monogenean class with the obvious characteristic of four eyes spotted on the anterior part. There is also the presence of an opisthaptor at the posterior-ventral part. The marginal hooklets and median hooks were also found. The picture below shows the *Dactylogyrus* spp. latching on the gills lamellar.

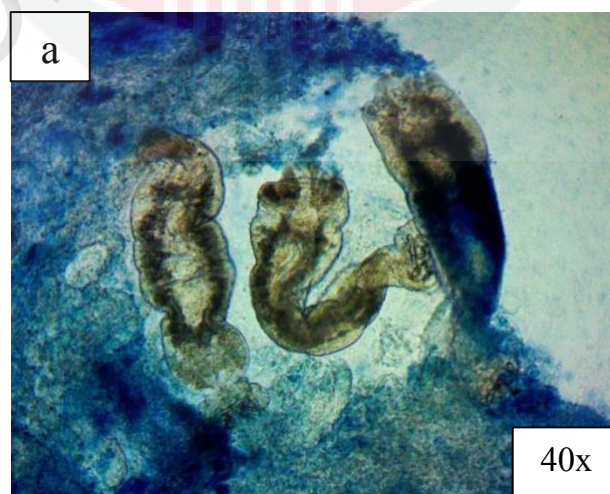



Figure 2.0 *Dactylogyrus* spp found in the gills of *Dichotomyctere nigroviridis*



**Figure 2.1 (a) The opisthaptor of *Dactylogyrus* spp. was observed in the gills of the *Dichotomyctere nigroviridis* (yellow circle)
(b) Four eye-spot can be distinguished in the *Dactylogyrus* spp (red circle)**

Based on Table 2.0 below, a higher prevalence of total parasites was found in the gills of juvenile fish compared to the adult fish with a prevalence of 100% for juveniles and 84.62% for adults. Meanwhile, the adult fishes recorded higher intensity which is 128.73 in comparison to the juveniles which was 48.

Table 2.0: Prevalence and intensity of ectoparasites found in gills for Juvenile and Adult *Dichotomyctere nigroviridis* sample

| | Total infected fish | Total parasites | Prevalence (%) | Intensity |
|-----------------|------------------------|--------------------|-------------------|-----------|
| Adult | 11 | 1416 | 84.62 | 128.73 |
| Juvenile | 3 | 144 | 100 | 48 |

Statistical analysis was done using the Mann-Whitney test to compare the total of parasites between juvenile fish and adult fish but there is no significant difference found with a p-value > 0.05 (0.4625).

4.3 HISTOPATHOLOGY ANALYSIS

The histopathology observation was performed using a light microscope under the magnification of 10x, 40x, and 100x. Every histology slide was evaluated and scored following the guideline of gill histopathology scoring as mentioned in Figure 1.0. The ancillary criteria were evaluated based on the presence or absence of ectoparasites, whereby score 1 indicates presence and score 0 indicates absence. As for the skin histopathological evaluation, it was done by examining the presence of inflammatory cells; lymphocytes, and macrophages. Score 1 means presence and score 0 means absence.

4.3.1 HISTOPATHOLOGY RESULT OF GILLS IN JUVENILE FISH

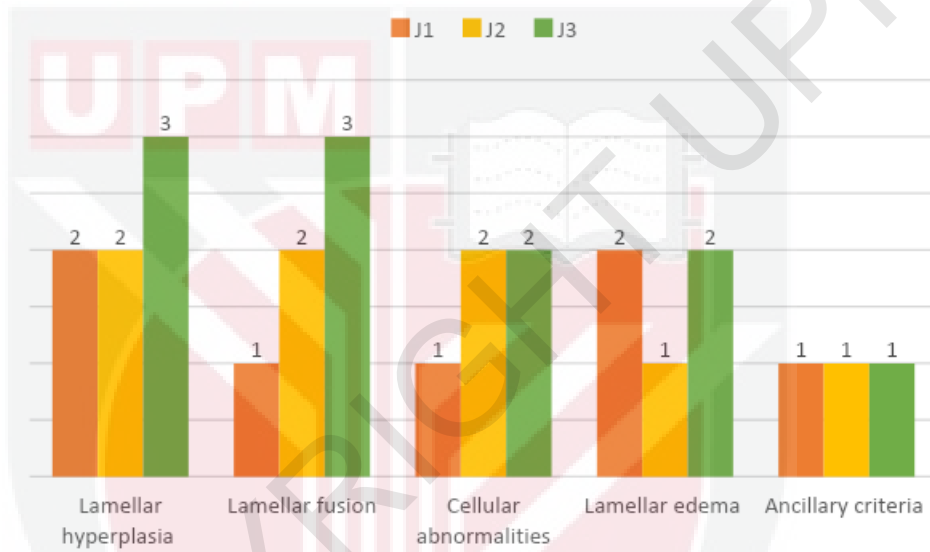
Table 3.0: Histopathology scoring of gills in juvenile *Dichotomyctere nigroviridis* sample

| Fish | Lamellar hyperplasia | Lamellar fusion | Cellular anomalies | Lamellar edema | Ancillary criteria |
|-------------|-----------------------------|------------------------|---------------------------|-----------------------|---------------------------|
| J1 | 2 | 1 | 1 | 2 | 1 |
| J2 | 2 | 2 | 2 | 1 | 1 |
| J3 | 3 | 3 | 2 | 2 | 1 |

Based on Table 3.0 above, all juvenile fish score 1 for ancillary criteria which indicates there is the presence of ectoparasites in all gill samples. One of the fish scored 3 for both lamellar hyperplasia and lamellar fusion, indicating extensive lesions affecting more than 50% of the gills tissue. But, in cellular anomalies, the highest score for this lesion is 2 which means there are multifocal areas of degenerating cells sloughing off throughout the tissue with about 10-50% affected. It is similar to lamellar edema, the highest score is also 2 indicating 10-50% of gills tissue is affected. The data also indicates that one of the fish exhibits gill lesions ranging from moderate

to severe, with a score ranging from 2 to 3. The remaining two fish show lesions of mild to moderate severity. For a clearer representation, the bar chart in Figure 3.0 can be referred.

Figure 3.0: Bar chart showing the histopathology scoring of gills in juvenile *Dichotomycytere nigroviridis* sample in Bagan Lalang, Selangor



Statistical analysis was performed through the Mann-Whitney test to compare the number of parasites present in the gills of juvenile fish with each of the histopathological criteria, and the result shows no significant difference with a p-value > 0.05 (0.4325).

4.3.2 HISTOPATHOLOGY RESULTS OF GILLS IN ADULT FISH

Table 4.0: Histopathology scoring of gills in adult *Dichotomycytere nigroviridis* sample

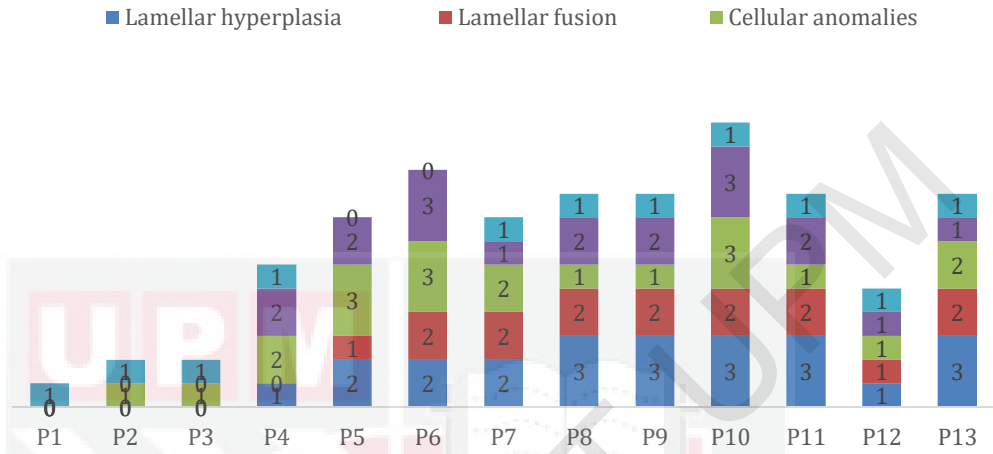
| Fish | Lamellar hyperplasia | Lamellar fusion | Cellular anomalies | Lamellar edema | Ancillary criteria |
|------|----------------------|-----------------|--------------------|----------------|--------------------|
| P1 | 0 | 0 | 0 | 0 | 1 |
| P2 | 0 | 0 | 1 | 0 | 1 |

| | | | | | |
|------------|---|---|---|---|---|
| P3 | 0 | 0 | 1 | 0 | 1 |
| P4 | 1 | 0 | 2 | 2 | 1 |
| P5 | 2 | 1 | 3 | 2 | 0 |
| P6 | 2 | 2 | 3 | 3 | 0 |
| P7 | 2 | 2 | 2 | 1 | 1 |
| P8 | 3 | 2 | 1 | 2 | 1 |
| P9 | 3 | 2 | 1 | 2 | 1 |
| P10 | 3 | 2 | 3 | 3 | 1 |
| P11 | 3 | 2 | 1 | 2 | 1 |
| P12 | 1 | 1 | 1 | 1 | 1 |
| P13 | 3 | 2 | 2 | 1 | 1 |

As stated in the table above, all histopathological criteria were found on the adult fish with a variety of scores ranging from 0 to 3 which is mild to severe. Among all 13 fishes, only two adult fishes scored 0 for ancillary criteria which indicates the ectoparasites are absent in the gill samples. As for the lamellar hyperplasia, 10 out of 13 fish have the lesion with the highest score of 3. Meanwhile, for lamellar fusion, the score is mild (1) to moderate (2) among the 9 fishes that have the lesion. For cellular anomalies, 12 out of 13 has the lesion which remark as the highest number of fishes with score 2 as the most prominent one.

One of the fish has no histopathological lesions despite it having ectoparasites residing in it. About 90% of the adult fish have cellular anomalies lesion with 3 fishes severely affected as they score 3 and only one fish not affected by it. Better visualization can be seen in the figure below (Figure 4.0).

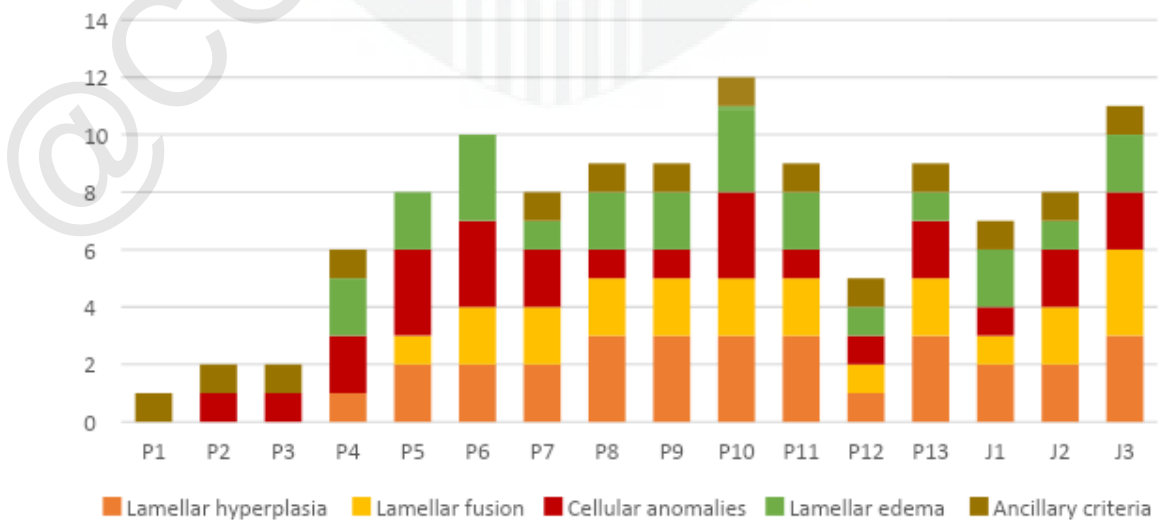
Figure 4.0: Bar chart showing the histopathology scoring of gills in adult *Dichotomyctere nigroviridis* sample



Statistical analysis was performed to compare the number of parasites present in the gills of adult fish with each histopathological criterion using the Mann-Whitney test. The result shows a significant difference with p-value < 0.05 (0.0005).

4.3.3 HISTOPATHOLOGY RESULTS OF GILLS IN ADULT AND JUVENILE FISH

Figure 5.0: Bar chart showing the histopathology scoring of gills in adult and juvenile *Dichotomyctere nigroviridis* sample



In Figure 5.0 above, it can be seen that cellular anomalies were the most prominent histopathological lesion in both juvenile and adult fish with 15 out of 16 fish samples affected with a total percentage of 92.3%. As for the ancillary criteria, only two adult fish have an absence of parasites in the sample during evaluation.

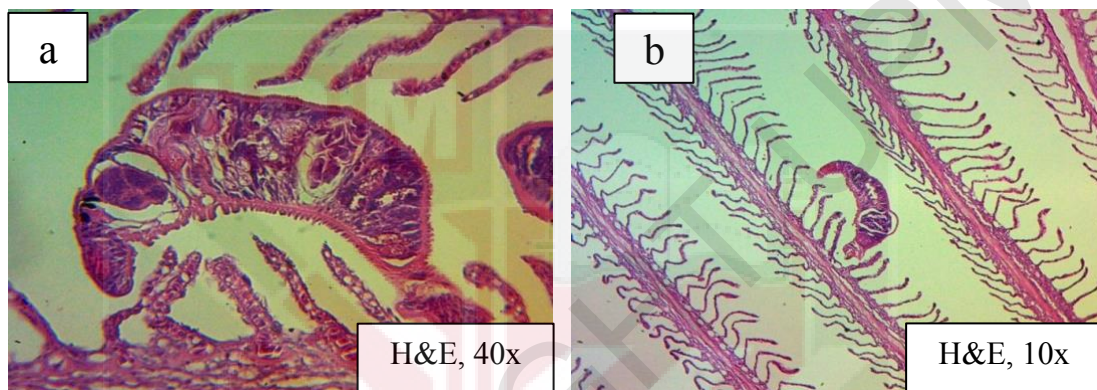


Figure 6.0 (a) & (b) Presence of *Dactylogyrus* spp. attaching on the lamellar of the *Dichotomyctere nigroviridis*

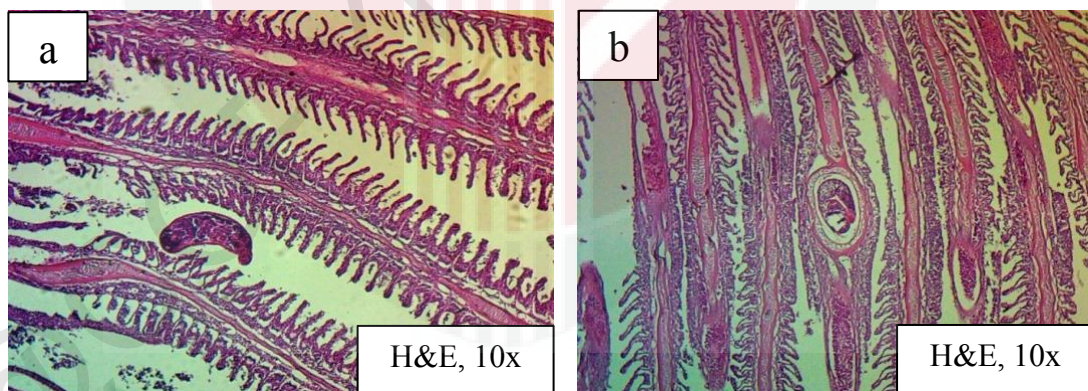


Figure 6.1 (a) *Dactylogyrus* spp. and lamellar hyperplasia observed on the gills of *Dichotomyctere nigroviridis*.

(b) Cysts found residing in the lamellar of *Dichotomyctere nigroviridis*.

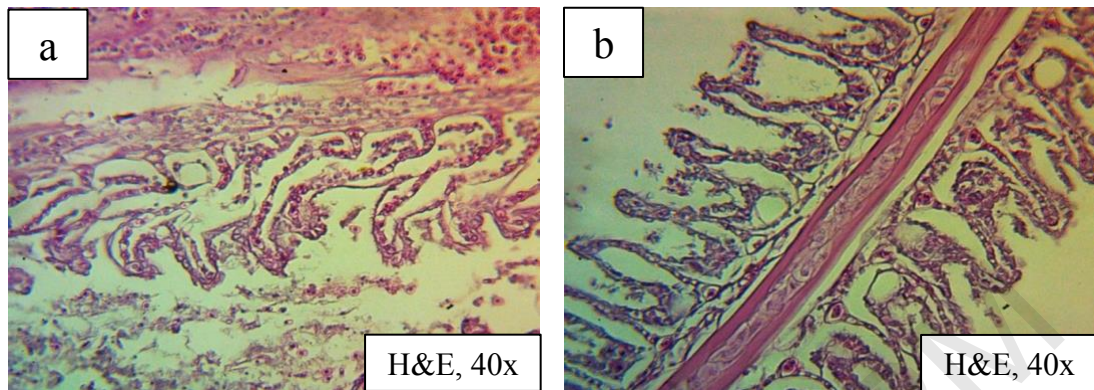


Figure 6.2 Cellular anomalies (a), lamellar fusion and lamellar edema (b) observed in the gills tissue of the *Dichotomyctere nigroviridis*

Statistical analysis was performed using the Mann-Whitney test to compare the histopathological scoring of each criterion between adult fish and juvenile fish. The result shows no significant difference with a p-value > 0.05 (0.1449).

4.3.4 HISTOPATHOLOGY RESULTS OF SKIN

Table 5.0: Histopathology evaluation on skin of juvenile *Dichotomyctere nigroviridis* sample

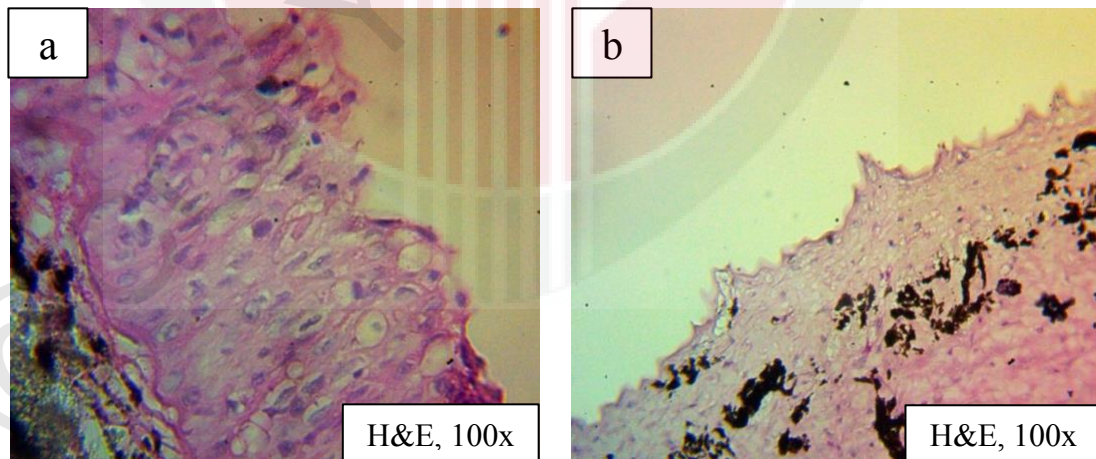
| Fish | Skin inflammation |
|------|-------------------|
| J1 | 1 |
| J2 | 0 |
| J3 | 0 |

The table above shows that only 1 juvenile fish sample has inflammatory cells found in the skin. Since there are no ectoparasites found in the skin scrapping, the inflammation can be caused by other factors which be discussed in the discussion.

Table 6.0: Histopathology evaluation on skin of adult *Dichotomyctere nigroviridis* sample

| Fish | Skin inflammation |
|------|-------------------|
| P1 | 1 |
| P2 | 1 |
| P3 | 1 |
| P4 | 1 |
| P5 | 1 |
| P6 | 0 |
| P7 | 1 |
| P8 | 1 |
| P9 | 1 |
| P10 | 1 |
| P11 | 0 |
| P12 | 1 |
| P13 | 1 |

The table above shows that only 2 adult fish sample has no inflammatory cells found in the skin. Similar to juvenile fish, there are no ectoparasites found in the skin and fin scrapping, hence the inflammation may be caused by other factors.



**Figure 7.0 (a) Presence of inflammatory cells can be seen in the skin of *Dichotomyctere nigroviridis*
(b) the skin structure in normal skin of *Dichotomyctere nigroviridis***

Statistical analysis was performed using the Mann-Whitney test to compare the histology scoring of skin between adult and juvenile fish, and there is no significant difference.

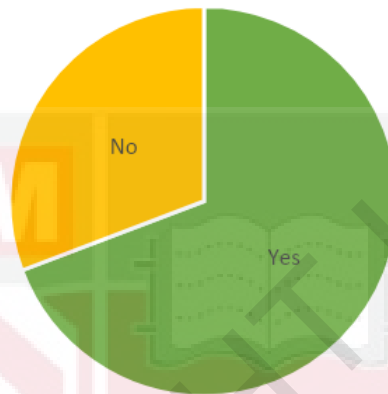


Figure 8.0: Pie chart showing the presence of inflammation of skin for all *Dichotomyctere nigroviridis* sample

The pie chart below shows the percentage of skin inflammation among the 16 fish samples. More than half of the fish which is 69% of the samples have the presence of inflammatory cells on the skin which comprised 9 fishes including adult and juvenile groups.

5.0 DISCUSSION

In this study, the intensity of ectoparasites, *Dactylogyrus* spp. in the gills of adult pufferfish, *Dichotomyctere nigroviridis* was recorded as higher compared to the juveniles. This is because larger fish possess an expanded gill surface area, leading to enhanced ventilation and mucous production, thereby increasing their susceptibility to parasites as it makes them appear more attractive which was indicated by a study by

Cedrik et al., (1998) that was conducted in Tahiti, French Polynesia involved the collection of various coral-reef fish species; *Stegastes nigricans*, *Dascyllus aruanus*, and *Cephalopholis argus* that were captured using handheld nets and spear guns, and their length and weight were subsequently recorded. Then, the collected data was then analyzed to examine and compare the parasitic load present in both the gills and visceral organs of the fish with the size of the fish. Furthermore, parasites tend to favor hosts with larger bodies and higher nutritional quality as it benefits the parasites' growth and development. A research was conducted by Parida et al., (2018) in India that looked at different sizes of Indian major carp called rohu which comprised of fingerling, juvenile, and pre-adult stages that were placed in separate tanks with *Argulus siamensis* parasites. The parasites were added at a rate of 1 adult per 4 grams of body weight, and, after 20 days, it was found that the pre-adult stage had the most parasites, showing it was the most vulnerable compared to the other stages. Nevertheless, a study stated that smaller fish, with a larger proportion of fin surface area relative to their overall body, will tend to have higher parasite count per square centimeter of body surface. Tucker et al., (2002) study using distinct groups of salmon, categorized by size into large fish ($644.4 \pm 61.6\text{g}$), medium-sized fish ($172.9 \pm 31.8\text{g}$), and small fish ($42.8 \pm 4.1\text{g}$), evenly distributed across two tanks, and, subsequently, they were subjected to an 8-hour infection period with *Lepeophtheirus salmonis*. The findings revealed that the count of copepods was most pronounced in the small fish group compared to the other two size groups. However, this study contradicts this assertion, as we specifically observed ectoparasites on the gills rather than on the fins.

This current study also found out that the presence of ectoparasites, *Dactylogyrus* spp. in the gills of adult fish is significantly associated with the

histopathological changes in the gills of *Dichotomyctere nigroviridis*. This correlation is supported by a study conducted by Zaiyana et al. (2022) in Indonesia, that did a study in 90 snakehead fish sourced from rice fields, swamps, and ditches focused on examining ectoparasites and associated histopathological abnormalities in gills, skins, and fins. The study revealed that fish afflicted with ectoparasites, particularly *Dactylogyrus* spp., exhibited notable histopathological manifestations such as lamellar hyperplasia, heightened mucus secretion by mucous cells, lamellar fusion, and swelling which in this study, the only ectoparasites found is *Dactylogyrus* spp. that typically adheres to the gill surface using an opisthaptor—a suction device that circulates in the blood. Additionally, the attachment of monogeneans leads to lamellae clubbing, resulting in increased tissue growth and the fusion of secondary lamellae. A further exploration done by Suliman et al., (2021) that was conducted in the Riyadh region of Saudi Arabia aimed to assess the impact of monogenean parasites on Tilapia, *Oreochromis niloticus* focusing on histopathological alterations. The observed changes included degeneration and fusion of secondary lamellae, persistent displacement of gill epithelial cells, destruction of gill filaments, and hyperplasia of gill epithelium. Hence, the lamellar appears thick in shape even when being seen from lower magnification. Furthermore, a study by Cheng et al. (2023) was done in China to detect the morphological identification and histology analysis of various *Dactylogyrus* spp. towards the gills of several random species of fish and it revealed that ectoparasite infestation may stimulate the proliferation of cartilaginous tissue and increase epithelial cell growth, contributing to the occurrence of lamellar hyperplasia.

In this study, all five distinct histopathological criteria are present, with cellular anomalies being the most prevalent, followed by other conditions like lamellar

hyperplasia, lamellar fusion, and lamellar edema. Both adult and juvenile fishes have all the lesions. According to a journal written by Feist and Longshaw (2008), it mentioned that lamellar hyperplasia was identified as the initial response of infection and can progress along with processes like lamellar fusion, lamellar stratification, and cellular anomalies. And it also stated the elevated score for cellular anomalies might suggest a prolonged infestation period, indicating that the fish are currently responding to a late-stage parasitic infection. It is essential to note that this observation could be influenced by the extended duration taken to process the samples for analysis. Ideally, fish samples should be processed promptly after collection to ensure tissue freshness and prevent post-mortem changes.

For the skin histopathological analysis that was done in this study, there is the presence of inflammatory cells on the skin of the spotted green pufferfish, *Dichotomyctere nigroviridis* even though there is no presence of ectoparasites insight during observation grossly or under the microscope. The inflammatory cells found are mainly comprised of lymphocytes and monocytes. A study done by Tabasum et al. (2023) in *Clarias gariepinus* observed the effects of ectoparasites; *Dactylogyrus* spp. and *Lernaea* sp. on skin which revealed that infested skin displayed a moderate level of mononuclear and polymorphonuclear inflammation, along with leukocyte infiltration and the withdrawal of blood at the location where the parasite was attached. Given the absence of ectoparasites in this investigation, coupled with the observed inflammation, it is plausible to posit that ectoparasites were initially present. However, due to the prolonged processing time of the samples, the ectoparasites began to detach from the skin surface of the fish. According to Mohammadi et al. (2012), the study conducted on *Astronotus ocellatus* and *Symphysodon discus* specimens were acquired,

and a wet mount, as well as a histopathological examination, were conducted on both their skin and gills. The results revealed dermatitis, dermal edema, the presence of vacuoles in epidermal cells, and infiltration of inflammatory cells between epithelial and dermal cells in the infected skin. From the study also, it can be observed that fish commonly experience skin lesions due to constant exposure to water and external environments, rendering them susceptible to pathogenic agents like ectoparasites. Thus, skin lesions were able to be seen more. However, in this investigation, the absence of ectoparasites suggests that inflammation may arise not solely from ectoparasites but also from other factors such as suboptimal water quality, stress, and environmental changes. Jones et al. (2006) performed a study in Atlantic Salmon, *Lepeophtheirus salmonis* located in Scotland to determine the effects of chalimus stage (Copepoda; Chaligidae) on the skin structure, whereas, during histopathological analysis, the dermis layer appeared to be fibrosed with the infiltration inflammatory cells and hyperplastic changes in the epidermis layer. This study also suggests that the skin serves as a primary target organ during ectoparasitic infections or other external threats, influencing the inflammatory response, which aligns with the observed presence of lymphocytes and monocytes.

6.0 CONCLUSION

In conclusion, the ectoparasite found in this study is *Dactylogyrus* spp with the highest prevalence recorded in juveniles which is 100% from the 3 samples. Meanwhile, the adult fish has higher intensity compared to juveniles with a record of 128.73. The skin scraping and fin scraping had a negative value as there is no presence of ectoparasites observed during direct wet mount. There is no significant difference between the number of parasites in adults and juveniles whereby the p-value > 0.05 which is 0.4625. As for the histopathological analysis, cellular anomalies are the most prominent lesions found among the gills of juvenile and adult fishes with 92.3% of fish samples affected followed by 87.5% of samples that had ancillary criteria. There is no significant difference between the histopathological lesions between adults and juveniles as it records a p-value > 0.05 which is 0.1449. The comparison between the presence of parasites in adults with the histopathological lesions shows a statistical significance with a p-value < 0.05 which is 0.0005. Unlike the adults, the presence of parasites in juveniles has no significant difference with the histopathological lesions as the p-value > 0.05 (0.4325). Inflammation was also observed in the skin histology by identifying the lymphocytes and macrophages. However, there is no significant difference between the skin inflammation of adults and juveniles with a p-value > 0.05 (0.1375).

7.0 RECOMMENDATIONS

As a suggestion, it would be advisable to increase the sample size until a balance is achieved between the number of adult and juvenile fish. By expanding the sample size, more comprehensive and precise results can be obtained regarding the occurrence of ectoparasites in pufferfish in Bagan Lalang, Selangor. The smaller sample size has the potential to skew parasite prevalence and intensity towards higher values. It is recommended to minimize the time from fishing to sample processing to reduce post-mortem changes and prevent further detachment of ectoparasites from the skin, fins, and gills. This adjustment would likely contribute to more accurate results. Moreover, for more precise identification of ectoparasite species, it is suggested to conduct molecular identification such as Polymerase Chain Reaction (PCR) that will help to ensure an accurate determination of the ectoparasite findings of this study. Further exploration and research on this particular pufferfish species are essential to gather additional information that can enhance the overall understanding of the subject. However, because of insufficient resources and limited exploration of this fish species, it was necessary to conduct further research on it.

8.0 REFERENCES

- Ahmed Chowdhury, I., Rakibul Hasan, M., Parveen, S., Kanti Dey, S., & Baki Billah, M. (2019). Proximate composition of two puffer fish species, *Leiodon cutcutia* and *Dichomyctere fluviatilis* of Bangladesh. In *Jahangirnagar University J. Biol. Sci* (Vol. 8, Issue 1).
- Cedrik, M. Lo, Morand, S., & Galzin, R. (1998). *Parasite diversity: host age and size relationship in three coral reef fishes from French Polynesia*.
- Cheng, J., Zou, H., Li, M., Wang, J., Wang, G., & Li, W. (2023). Morphological and Molecular Identification of *Dactylogyrus gobiocypris* (Monogenea: Dactylogyridae) on Gills of a Model Fish, *Gobiocypris rarus* (Cypriniformes: Gobionidae). *Pathogens*, 12(2). <https://doi.org/10.3390/pathogens12020206>
- Dada, A. C., Ahmad, A., Usup, G., & Heng, L. Y. (2013). Speciation and antimicrobial resistance of Enterococci isolated from recreational beaches in Malaysia. *Environmental Monitoring and Assessment*, 185(2), 1583–1599. <https://doi.org/10.1007/s10661-012-2653-6>
- Feist, S. W., & Longshaw, M. (2008). Histopathology of fish parasite infections - Importance for populations. In *Journal of Fish Biology* (Vol. 73, Issue 9, pp. 2143–2160). <https://doi.org/10.1111/j.1095-8649.2008.02060.x>
- Indahsari, M., Kismiyati, & Ulkhaq, M. F. (2019). Prevalence and Intensity of Ectoparasites of Tilapia (*Oreochromis niloticus*) in Ponds with Low, Medium and High Stocking Density. *IOP Conference Series: Earth and Environmental Science*, 236(1). <https://doi.org/10.1088/1755-1315/236/1/012108>
- Islam, M. R., Chowdhury, F. R., Das, S. K., Rahman, S. M. M., & Amin, M. R. (2018). Outbreak of puffer fish poisoning in Dhaka city. *Journal of Medicine (Bangladesh)*, 19(1), 30–34. <https://doi.org/10.3329/jom.v19i1.34837>
- Jones, M. & Sommerville, Christina & Bron, James. (2006). The histopathology associated with the juvenile stages of *Lepeophtheirus salmonis* on the Atlantic Salmon, *Salmo salar* L. *Journal of Fish Diseases*. 13. 303 - 310. [10.1111/j.1365-2761.1990.tb00786.x](https://doi.org/10.1111/j.1365-2761.1990.tb00786.x). Kawata, Y. (2012). Fishery resource recovery strategy without reducing the number of landings: A case study of the ocellate puffer in Japan. *Ecological Economics*, 77, 225–233. <https://doi.org/10.1016/j.ecolecon.2012.03.006>
- Klimpel, S., Kuhn, T., Münster, J., Dörge, D. D., Klapper, R., & Kochmann, J. (2019). *Parasites of Marine Fish and Cephalopods A Practical Guide*.
- Klinger, R., & Floyd, R. F. (2013). *Introduction to Freshwater Fish Parasites 1*. <http://edis.ifas.ufl.edu>.

- Melnikova, D. I., & Magarlamov, T. Y. (2022). An Overview of the Anatomical Distribution of Tetrodotoxin in Animals. In *Toxins* (Vol. 14, Issue 8). MDPI. <https://doi.org/10.3390/toxins14080576>
- Mitchell, S. O., Baxter, E. J., Holland, C., & Rodger, H. D. (2012). Development of a novel histopathological gill scoring protocol for assessment of gill health during a longitudinal study in marine-farmed Atlantic salmon (*Salmo salar*). *Aquaculture International*, *20*(5), 813–825. <https://doi.org/10.1007/s10499-012-9504-x>
- Mohammadi, F., Mousavi, S. M., & Rezaie, A. (2012). *Histopathological study of parasitic infestation of skin and gill on Oscar (Astronotus ocellatus) and discus (Symphysodon discus)*.
- Morsy, K., Saady, H., Abdel-Ghaffar, F., Bashtar, A. R., Mehlhorn, H., Quraishy, S. Al, & Adel, A. (2012). A new species of the genus *Heterobothrium* (Monogenea: Diclidophoridae) parasitizing the gills of tiger puffer fish *Tetraodon lineatus* (Tetraodontidae). A light and scanning electron microscopic study. *Parasitology Research*, *110*(3), 1119–1124. <https://doi.org/10.1007/s00436-011-2601-3>
- Muchlisin, Z. A., Munazir, A. M., Fuady, Z., Winaruddin, W., Sugianto, S., Adlim, M., Fadli, N., & Hendri, A. (2014). *Prevalence of ectoparasites on mahseer fish (Tor tambra Valenciennes, 1842) from aquaculture ponds and wild population of Nagan Raya District, Indonesia*. <http://www.hvm.bioflux.com.ro/>
- Parida, S., Mohapatra, A., Mohanty, J., & Sahoo, P. K. (2018). *Labeo rohita* and *Argulus siamensis* infection: Host size, local inflammatory reaction and immunity modulate ectoparasite load on fish. *Aquaculture Research*, *49*(2), 757–766. <https://doi.org/10.1111/are.13506>
- Santini, F., Nguyen, M. T. T., Sorenson, L., Waltzek, T. B., Lynch Alfaro, J. W., Eastman, J. M., & Alfaro, M. E. (2013). Do habitat shifts drive diversification in teleost fishes? An example from the pufferfishes (Tetraodontidae). *Journal of Evolutionary Biology*, *26*(5), 1003–1018. <https://doi.org/10.1111/jeb.12112>
- Suliman, E. A. M., Osman, H. A., & Al-Deghayem, W. A. A. (2021). Histopathological changes induced by ectoparasites on gills and skin of *oreochromis niloticus* (Burchell 1822) in fish ponds. *Journal of Applied Biology and Biotechnology*, *9*(1), 68–74. <https://doi.org/10.7324/JABB.2021.9109>
- Sures, B., Nachev, M., Selbach, C., & Marcogliese, D. J. (2017). Parasite responses to pollution: what we know and where we go in ‘Environmental Parasitology.’ In

Parasites and Vectors (Vol. 10, Issue 1, pp. 1–19). BioMed Central.
<https://doi.org/10.1186/s13071-017-2001-3>

Tabasum, B., Arjamand, S., Qayoom, I., Khan, S., & Dar, S. A. (2023). Effect of Ectoparasitic Infestations on Histology and Growth of *Clarias gariepinus*. *Biological Forum-An International Journal*, 15(1), 1.

Tucker, C. S., Sommerville, C., & Wootten, R. (2002). Does size really matter? Effects of fish surface area on the settlement and initial survival of *Lepeophtheirus salmonis*, an ectoparasite of Atlantic salmon *Salmo salar*. *DISEASE OF AQUATIC ORGANISMS*, 49, 145–152.

Vidal-Martínez, V. M., Ocaña, F. A., Soler-Jiménez, L. C., García-Teh, J. G., Aguirre-Macedo, M. L., May-Tec, A. L., Arcega-Cabrera, F., & Herrera-Silveira, J. (2022). Functional Groups of Metazoan Parasites of the Dusky Flounder (*Syacium papillosum*) as Bioindicators of Environmental Health of the Yucatan Shelf. *Bulletin of Environmental Contamination and Toxicology*, 108(1), 24–29. <https://doi.org/10.1007/s00128-021-03177-9>

Zaiyana, N., Sardi, A., Harahap, M. R., Humairani, R., Paujjah, E., Rumondang, R., & Zulfahmi, I. (2022). Alteration in gills, skin, and fins of snakehead fish (*Channa striata*) due to ectoparasite infection: a macropathological and histopathological approach. *E3S Web of Conferences*, 339. <https://doi.org/10.1051/e3sconf/202233901001>

Zhu, H., Sakai, T., Nagashima, Y., Doi, H., Takatani, T., & Arakawa, O. (2021). *Tetrodotoxin/Saxitoxins Selectivity of the Euryhaline Freshwater Pufferfish Dichotomyctere fluviatilis*. <https://doi.org/10.3390/toxins>

Zin Mohamed, M., & Hassan, N. (2017). *Journal of the Malaysian Institute of Planners VOLUME* (Vol. 15).

APPENDIX 1

Table 1: The correlation between the group of pufferfish, *Dichotomycere nigroviridis* with histopathological criteria in the gills

| p-value of the 2 groups with gills histopathological criteria | | | | | |
|---|----------------------|-----------------|----------------|--------------------|--------------------|
| Group/Criteria | Lamellar hyperplasia | Lamellar fusion | Lamellar edema | Cellular anomalies | Ancillary criteria |
| Adult | 0.0009 | 0.0006 | 0.0008 | 0.0014 | 0.0006 |
| Juvenile | 0.6 | 0.7 | 0.6 | 0.6 | 0.6 |

APPENDIX 2

Table 2: The histopathological score of gills for adult pufferfish, *Dichotomycere nigroviridis*

| Adult | Lamellar hyperplasia | Lamellar fusion | Cellular abnormalities | Lamellar edema | Ancillary criteria |
|-------|----------------------|-----------------|------------------------|----------------|--------------------|
| P1 | 0 | 0 | 0 | 0 | 1 |
| P2 | 0 | 0 | 1 | 0 | 1 |
| P3 | 0 | 0 | 1 | 0 | 1 |
| P4 | 1 | 0 | 2 | 2 | 1 |
| P5 | 2 | 1 | 3 | 2 | 0 |
| P6 | 2 | 2 | 3 | 3 | 0 |
| P7 | 2 | 2 | 2 | 1 | 1 |
| P8 | 3 | 2 | 1 | 2 | 1 |
| P9 | 3 | 2 | 1 | 2 | 1 |
| P10 | 3 | 2 | 3 | 3 | 1 |
| P11 | 3 | 2 | 1 | 2 | 1 |
| P12 | 1 | 1 | 1 | 1 | 1 |
| P13 | 3 | 2 | 2 | 1 | 1 |

0 = None, 1 = Mild, 2 = Moderate, 3 = Severe

APPENDIX 3

Table 3: The histopathological score of gills for juvenile pufferfish, *Dichotomyctere nigroviridis*

| Juvenile | Lamellar hyperplasia | Lamellar fusion | Cellular abnormalities | Lamellar edema | Ancillary criteria |
|----------|----------------------|-----------------|------------------------|----------------|--------------------|
| J1 | 2 | 1 | 1 | 2 | 1 |
| J2 | 2 | 2 | 2 | 1 | 1 |
| J3 | 3 | 3 | 2 | 2 | 1 |

0 = None, 1 = Mild, 2 = Moderate, 3 = Severe

APPENDIX 4

Table 4: Histopathology evaluation on skin of juvenile pufferfish, *Dichotomyctere nigroviridis* sample

| Juvenile | Inflammation (Presence of lymphocytes & macrophages) |
|----------|---|
| J1 | 1 |
| J2 | 0 |
| J3 | 0 |

0 = Absence of inflammation
1 = Presence of inflammation

APPENDIX 5

Table 5: Histopathology evaluation on skin of adult pufferfish, *Dichotomyctere nigroviridis* sample

| Adult | Inflammation (Presence of lymphocytes & macrophages) |
|-------|---|
| P1 | 1 |
| P2 | 1 |
| P3 | 1 |
| P4 | 1 |
| P5 | 1 |
| P6 | 0 |
| P7 | 1 |
| P8 | 1 |
| P9 | 1 |
| P10 | 1 |
| P11 | 0 |
| P12 | 1 |
| P13 | 1 |

0 = Absence of inflammation
1 = Presence of inflammation