



UNIVERSITI PUTRA MALAYSIA

**COMPARISON OF PARASITE SPECIES AND BURDEN BETWEEN
APPARENTLY HEALTHY AND CLINICALLY ILL RED JUNGLE FOWL,
*Gallus gallus gallus***

ZATI HIDAYAH BINTI ZAINI

**Ip
FPV 2016 91**

**COMPARISON OF PARASITE SPECIES AND BURDEN BETWEEN
APPARENTLY HEALTHY AND CLINICALLY ILL RED JUNGLE FOWL,
*Gallus gallus gallus***

ZATI HIDAYAH BINTI ZAINI

A project paper submitted to the
Faculty of Veterinary Medicine, Universiti Putra Malaysia

In partial fulfillment of the requirement for the
DEGREE OF DOCTOR OF VETERINARY MEDICINE

Universiti Putra Malaysia
Serdang, Selangor Darul Ehsan.

MARCH 2016

CERTIFICATION

It is hereby certified that we have read this project paper entitled “Comparison of Parasite Species and Burden between Apparently Healthy and Clinically Ill Red Jungle Fowl, *Gallus gallus gallus*”, by Zati Hidayah Binti Zaini and in our opinion it is satisfactory in terms of scope, quality, and presentation as partial fulfillment of the requirement for the course VPD 4999 – Project.

ASSOC. PROF. DR. JALILA ABU
DVM (UPM), M.Sc. (UPM), Ph.D. (MINNESOTA)
Department of Veterinary Clinical Studies
Faculty of Veterinary Medicine
Universiti Putra Malaysia
(Supervisor)

ASSOC. PROF. DR. SHAIKH MOHAMED AMIN BABJEE
B.V.Sc (LAHORE), M.Sc. (NORTH WALES), Ph.D (QUEENSLAND)
Department of Veterinary Pathology and Microbiology
Faculty of Veterinary Medicine
Universiti Putra Malaysia
(Co-Supervisor)

DEDICATIONS

This project paper is dedicated to the One Almighty God, Allah, who had created me
and made all things possible,

To my family,

Mr Zauj, Ghazali Roslani

My 'little fighter'

Mak, Rosidah Jaafar

Abah, Zaini Yunan

Atul & Ata

And to all my teachers who have committed themselves towards the
noble cause of education.

ACKNOWLEDGEMENTS

It is with deepest appreciation and gratitude that I thank Allah S.W.T and all those who have made this project paper a reality.

To the persons that have assisted throughout this project, I would firstly like to thank my project supervisor, Assoc. Prof. Dr. Jalila Abu for the time, wisdom and guidance that she had granted me throughout the duration of this project, and my studies at the faculty.

Special thanks to my co-supervisor, Assoc. Prof. Dr. Shaikh Mohamed Amin Babjee for the time, expertise, guidance, unwavering support and encouragement to improve the project, and myself personally which without it, this project paper would not exist.

To Prof. Dr. Mohamed Ariff Omar, thank you so much for guiding me with the statistical analysis.

I would also like to thank the staff of the Parasitology Lab and Post Mortem Lab, UPM which includes Mrs. Maizatul, Mr. Rashid, Mr. Syahir and Mr. Ghazali for always lending me a helping hand when I needed it, and sharing good company.

A special thanks to all my classmates of DVM 2016 who assisted directly or indirectly in this project with special mention to Fatin Omar, Najihah Shobat Settic, Marlia Marji and Lizma Felisha Mazlan.

Last but not least, my most heartfelt gratitude to my family; my husband, my 'little fighter', father, mother, and dear sisters for their love and support throughout my studies.

CONTENTS

Title	i
Certification	ii
Dedication	iii
Acknowledgements	iv
Contents	v
Abstrak	vi
Abstract	viii
1.0 INTRODUCTION	1
1.1 Red Jungle Fowl	1
1.2 Parasitism	2
2.0 LITERATURE REVIEW	4
2.1 Avian blood parasites	4
2.1.1 Leucocytozoon sp.	4
2.1.2 Plasmodium sp.	4
2.1.3 Microfilaria sp.	5
2.1.4 Trypanosome sp.	5
2.2 Avian ectoparasites	5
2.2.1 Ticks	5
2.2.2 Mites	6
2.2.3 Lice	6
2.3 Avian endoparasites	7
2.3.1 Cecal worms (Heterakis sp.)	7
2.3.2 Thread worms (Capillaria sp.)	8
2.3.3 Tape worms (Raillietina sp.)	8
2.3.4 Protozoa (Eimeria sp.)	9
3.0 MATERIALS AND METHODS	10
3.1 Sample collection	10
3.2 Blood parasites examination procedure	10
3.3 Ectoparasites examination procedure	11
3.4 Endoparasites examination procedure	11
4.0 RESULTS	12
4.1 Blood parasite	12

4.1.1	Blood parasite species	12
4.1.2	Burden of blood parasites	13
4.2	Ectoparasites	14
4.2.1	Ectoparasite species	14
4.2.2	Burden of ectoparasites	16
4.3	Endoparasites	18
4.3.1	Endoparasite species	18
4.3.2	Burden of endoparasites	21
5.0	DISCUSSION	23
6.0	CONCLUSION	25
7.0	RECOMMENDATIONS	26
8.0	REFERENCES	27

ABSTRAK

Abstrak daripada kertas projek yang dikemukakan kepada Fakulti Perubatan Veterinar untuk memenuhi sebahagian daripada keperluan kursus VPD 4999 – Projek

PERBANDINGAN SPESIS PARASIT DAN BEBANAN ANTARA AYAM HUTAN YANG KELIHATAN SIHAT DAN KELIHATAN SAKIT,

Gallus gallus gallus.

Oleh

Zati Hidayah Binti Zaini

2016

Penyelia: Prof. Madya Dr. Jalila Abu

Penyelia bersama: Prof. Madya Dr. Shaikh Mohamed Amin Babjee

Ayam hutan, *Gallus gallus* adalah salah satu daripada empat spesies ayam hutan yang ditemui di Asia. Ia dikenali sebagai moyang kepada ayam domestik (*Gallus domesticus*) disebabkan oleh penemuan yang meluas. Ayam ini apabila dijinakkan diperhatikan sangat mudah terdedah kepada penyakit yang menjejaskan ayam domestik. Oleh kerana terdapat hanya beberapa kajian yang dijalankan ke atas spesies ayam hutan terutamanya untuk membandingkan flora parasit antara burung sihat dan sakit, oleh itu kajian ini dijalankan bertujuan untuk mengenal pasti ektoparasit, endoparasit dan parasit darah yang dijangkiti oleh ayam hutan yang kelihatan sihat dan kelihatan sakit dan untuk

membandingkan beban parasit antara kedua-dua kumpulan ini. 12 ekor ayam hutan yang kelihatan sakit (yang menunjukkan simptom klinikal) dan empat ekor ayam hutan yang kelihatan sihat telah disampel dari sebuah ladang ayam hutan terletak di Jenderam Hulu, Selangor. Burung-burung ini telah diperiksa untuk ektoparasit, endoparasit dan parasit darah. Spesies parasit yang ditemui termasuk *Haemaphysalis wellingtoni*, *Lipeurus caponis*, *Menopon gallinae*, *Menacanthus stramineus*, *Goniodes dissimilis*, *Goniocotes hologaster* (ektoparasit); *Capillaria* sp, *Heterakis gallinarum*, *Raillietina cesticillus*, *Raillietina tetragona*, *Raillietina echinobothridia*, *Eimeria* sp, (endoparasit); *Plasmodium gallinaceum*, *Leucocytozoon sabrazezi*, *Microfilaria* sp., *Trypanosome* sp. (parasit darah). Hasil kajian menunjukkan bahawa tidak terdapat perbezaan yang signifikan di antara beban spesies parasit dalam ayam hutan yang kelihatan sihat dan yang kelihatan sakit kecuali hanya untuk kutu, *Lipeurus caponis*. Kesimpulannya, secara amnya, ayam hutan yang kelihatan sihat dan yang kelihatan sakit mempunyai spesies dan beban parasit yang sama yang menjangkiti mereka. Seseengah organisma lain, mungkin bakteria atau virus boleh menyebabkan penyakit pada burung yang secara klinikalnya terjejas.

Kata kunci: *Ayam hutan, ektoparasit, endoparasit, parasit darah, ayam hutan yang kelihatan sihat, ayam hutan yang kelihatan sakit.*

ABSTRACT

Abstract of the project paper presented to the Faculty of Veterinary Medicine in partial requirement for the course VPD 4999 – Project

**COMPARISON OF PARASITE SPECIES AND BURDEN BETWEEN
APPARENTLY HEALTHY AND CLINICALLY ILL RED JUNGLE FOWLS,
Gallus gallus gallus.**

By

Zati Hidayah Binti Zaini

2016

Supervisor: Assoc. Prof. Dr. Jalila Abu

Co-supervisor: Assoc. Prof. Dr. Shaikh Mohamed Amin Babjee

The Red Jungle Fowl, *Gallus gallus* is one of the four species of jungle fowl found in Asia. It is known as the ancestor of the domestic fowl (*Gallus domesticus*) due to its widespread distribution. These birds when domesticated were observed to be very susceptible to the diseases affecting the domestic chickens. As there are only few studies conducted on the Red Jungle Fowl species especially comparing the parasite flora of healthy and sick birds, therefore this study is aimed to identify the ectoparasites, endoparasites and blood parasites harboured by the apparently healthy and clinically ill Red Jungle Fowl and to compare the burden of the parasites between these two groups. 12 clinically ill (those showing clinical symptoms) and four apparently healthy Red Jungle

Fowl were sampled from a Red Jungle Fowl farm located at Jenderam Hulu, Selangor. The birds were examined for ectoparasites, endoparasites and blood parasites. The species of parasites recovered included *Haemaphysalis wellingtoni*, *Lipeurus caponis*, *Menopon gallinae*, *Menacanthus stramineus*, *Goniodes dissimilis*, *Goniocotes hologaster* (ectoparasites); *Strongeloides* sp., *Capillaria* sp., *Heterakis gallinarum*, *Raillietina cesticillus*, *Raillietina tetragona*, *Raillietina echinobothridia*, *Eimeria* sp., (endoparasites); *Plasmodium gallinaceum*, *Leucocytozoon sabrazezi*, *Microfilaria* sp., *Trypanosome* sp.(blood parasites). The results showed that there were no significant differences between burden of parasite species in apparently healthy and clinically ill Red Jungle Fowls except only for the lice, *Lipeurus caponis*. In conclusion, generally, the apparently healthy and clinically ill Red Jungle Fowls have the same species and burden of parasites harbouring them. Some other organisms, probably bacteria or viruses may be causing the disease in clinically affected birds.

Keywords: *Red Jungle Fowl*, *ectoparasites*, *endoparasites*, *blood parasites*, *apparently healthy*, *clinically ill*.

1.0 INTRODUCTION

1.1 Red Jungle Fowl

The red jungle fowl (*Gallus gallus*) is one of the most important members of the family Phasianidae. It is one of the four species of jungle fowl found in the Indian subcontinent and South East Asia. The other three species are Grey jungle fowl (*Gallus sonneretii*), Ceylonese jungle fowl (*Gallus lafayetti*) and Green jungle fowl (*Gallus varius*). It is regarded as the ancestor of the domestic fowl (*Gallus domesticus*) due to its widespread distribution (Beebe, 1926; Nishida *et al.*, 1985).

The two subspecies of the red jungle fowl are *Gallus gallus gallus* and *Gallus gallus spadiceus*. An important distinguishing feature between the two is the presence of white ear patch in the subspecies *G.g. gallus* while the subspecies *G.g. spadiceus* has a red ear patch (Nishida *et al.*, 1985).

Red Jungle Fowl, when domesticated were observed to be very susceptible to the diseases affecting the domestic chickens. There were several reports on parasites of the Red Jungle Fowl (Amin-Babjee *et al.*, 1985; Lee and Amin-Babjee, 1993). In the case of the Ceylonese Jungle Fowl, *Ascaridia galli*, *Raillietina tetragona* and *Eimeria praecox* are the only parasites recorded (Rysavy *et al.*, 1973), whereas in the Grey Jungle Fowl, *Lemnada sonneretta* is the only parasite recorded (Ali, 1969).

1.2 Parasitism

Parasitic infection can result in an increase in mortality and decrease in hatch rate of birds, thus regulating the population structure (Poulin *et al.*, 2004). In general, parasitism negatively affects the productivity of the local scavenging chickens since they either compete for feed or cause distress to the birds (Jansen and Pandey, 1989; Poulsen *et al.*, 2000)

Avian haemoparasites are known to be pathogenic to their hosts causing high mortalities, reproductive failure, retardation of growth, reduced productivity, and may exert negative effects on behavior and community structure (Dunn *et al.*, 2011). Protozoan parasites include haemosporidia in the genera Plasmodium sp., Haemoproteus sp., Leucocytozoon sp., Hepatozoon sp., Babesia sp., and haemoflagellates in the genus Trypanosoma.

Ectoparasites have a foremost impact on the yield, welfare and husbandry of domestic animals (Colebrook and Wall, 2004). According to Fabiyi (1996), ectoparasites act as biological and mechanical vectors transmitting number of pathogens. It has been known to be a major barrier to chicken health worldwide, causing direct and indirect loss (Permin *et al.*, 2002; Sonaiye and Swan, 2004; Swai *et al.*, 2007).

Endoparasites are those parasites that live within the body of the host and can cause many problems in bird's stomach and intestines, but also affect the normal function of other organs (Hussen *et al.*, 2012). Helminthes of poultry are commonly divided into three main groups; cestodes, nematodes and trematodes (Jordan and Pattison, 1996). The

cestodes of significant importance are of the two genera *Raillietina* sp. and *Hymenolepis* sp. Nematodes constitute the most important group of helminthes of poultry both in number of species and the extent of damage they cause; the main genera include *Ascaridia* sp., *Heterakis* sp. and *Capillaria* sp. (Matur and Dawam, 2010). The prevalence of parasitic helminthes in chickens were reported in several studies, such as India, 90.9% (Yadav *et al.*, 1991), Kenya 93.3% (Mungube *et al.*, 2008), Zambia 95.2% (Phiri *et al.*, 2007) and Nigeria 87.7% (Yoriyo *et al.*, 2008).

As there had been numerous studies conducted to determine the common parasites infesting the domestic chickens such as village chickens and as there were only few studies conducted on the Red Jungle Fowl species especially comparing the parasite flora of the healthy and the sick birds, this study was undertaken to fulfill the following objectives:

- To identify the ectoparasites, endoparasites and blood parasites harboured by the apparently healthy and clinically ill Red Jungle Fowl.
- To compare the burden of the parasites between these two groups.

For this research, the following hypotheses were proposed:

- The populations of parasite species found in the clinically ill Red Jungle Fowls are different compared to the healthy ones.

2.0 LITERATURE REVIEW

2.1 Avian blood parasites

2.1.1 Leucocytozoon sp.

Leucocytozoon sp. is haematozoan that are transmitted by blood sucking arthropods (Jordan, 1990). There are more than 60 species of Leucocytozoon sp. that have been detected from birds throughout the world (Bennett *et al.*, 1982). Although it is rare that leucocytozoonosis is incriminated as a cause of death, it has been observed in some avian species, including waterfowl (Greiner, 1991), eagles (Stuht *et al.*, 1999) and grouse (Clarke, 1935). Leucocytozoon sp. is a common parasite of birds belonging to the Tetraoninae and has a Holarctic distribution (Bennett *et al.*, 1991).

2.1.2 Plasmodium sp.

Plasmodium sp is a genus of Apicomplexan parasites. Currently, over 200 species of this genus are recognized and new species continued to be described (Chavatte *et al.*, 2007; Perkins *et al.*, 2008). Of the over 200 known species of Plasmodium sp., at least 11 species infect humans. Other species included monkeys, rodents, birds and reptiles.

2.1.3 Microfilaria sp.

The microfilaria is an early stage in the life cycle of certain parasitic nematodes in the family Onchocercidae (Anderson, 2000). The presence of microfilariae in the host bloodstream is called 'microfilaraemia'.

2.1.4 Trypanosome sp.

Avian Trypanosome sp. is surprisingly successful blood parasites that are widespread and prevalent in birds throughout the world (Bishop and Bennett, 1992). They are transmitted by wide variety of blood-sucking arthropods belonging to the Simuliidae, Culicidae, Ceratopogonidae, Hippoboscidae and Dermanyssidae (Baker, 1976; Molyneux, 1973). Trypanosome sp. has been named and described, mainly based on morphological features of hematozoic trypomastigotes, i.e., so called bloodstream forms (Baker, 1976; Bennett *et al.*, 1994).

2.2 Avian Ectoparasites

2.2.1 Ticks

Ticks are one of the most important ectoparasites of the Red Jungle Fowl. They are found attached to different parts of the head and neck region sucking blood and increasing the risk of infection to various microorganisms in humans and animals (Konto *et al.*, 2014).

According to a research carried out by M. Konto *et al.* (2015), all ticks found in the Red Jungle Fowls sampled, belong to the genus *Haemaphysalis* sp. with body length and width ranging between 1 to 2mm. Distribution of ticks based on developmental stages

during their life cycles showed that out of the total number of ticks collected, the ear predominate with 63% as the most predominant predilection site for all the developmental stages. The larval stage was solely restricted to the ear while the adult males were more commonly found on the wattle.

2.2.2 Mites

Mites are small arachnids with body measure went around up to 1mm in length. The body of mites are round and it does not has visible segmentation where the body is divided into two regions which are the anterior gnathosoma comprising of the mouthpart and posterior idiosoma comprising of the rest of the body (Ralph, 1949). According to Amin-Babjee *et al.* (1985), *Megninia cubitalis* is the species of mite that was found in the Malayan Red Jungle Fowls that were sampled in the study.

2.2.3 Lice

Lice are small ectoparasites, ranging between 1 to 6mm in length. It is wingless organism with straw coloured body which is dorsoventrally flattened in appearance with elongated abdomen. Lice belongs in order of Phthiraptera which is then broken down into two groups known as Anoplura which are the sucking lice and Mallaphaga which is also known as biting or chewing lice (Ralph, 1949). Anoplura which is also known as sucking lice feeds on mammal and in size from 0.5mm to 8mm in length. The mouthparts of these lice are adapted for piercing of the skin. Mallaphaga lice will feed on hair, skin fragments and feathers of the host. Some species of Mallaphaga will feed on blood oozing out of the scratches in the skin and these chewing lice will feed on mammal and birds (Ralph, 1949).

In 1956, Emerson has listed around 11 species of lice that can be found on chickens. They are found on different parts of the body. They are *Cuclotogaster heterographus*, *Goniocotes gallinae*, *Goniodes dissimilis*, *Goniodes gigas*, *Lipeurus caponis*, *Lipeurus lawrensis tropicalis*, *Menacanthus cornutus*, *Menacanthus pallidus*, *Menacanthus stramineus*, *Menopon gallinae* and *Oxylipeurus dentatus*.

Based on the study that was carried out by Faris *et al.* (2014), regarding the prevalence of ectoparasites in chickens in west of Iran, it has been known that, 64.8% of chickens were infected with lice and the most dominant species was the *M. stramineus*, 50.16%. According to Amin-Babjee *et al.* (1997), 10 species of ectoparasites were discovered from the chicken from the villages in Sungai Sekamat and Semenyih, Selangor.

2.3 Avian Endoparasite

2.3.1 Cecal worms (Heterakis sp.)

Heterakis sp. is small in size and can be found in the large intestine, in contrast to *Ascaridia* sp. which are large and inhabit the small intestine. According to Marizvikuru *et al.*, (2011), *Heterakis* sp. was the most prevalent parasite of chickens. It was reported in several studies, 10% (Hassouni and Belghyti, 2006), 39.6% (Molla *et al.*, 2012) and 31% (Effiong *et al.*, 2013). Adult worms are white, small up to 1.5cm in length; found in cecae (Roberts and Janovy, 2009).

Diagnosis of this parasite in the laboratory is done by examination of the eggs, which may be found on fecal floatation (Soulsby, 1982). Eggs are ellipsoidal, with a thick, smooth shell, 65 – 80µm in size, containing a single cell (Monnig, 1950).

2.3.2 Thread worms (*Capillaria* sp.)

There are several species of *Capillaria* sp. that occur in poultry. *Capillaria obsignata* is present in the upper small intestine of chickens, turkeys and pigeons and has a direct life cycle (Monnig, 1950). *Capillaria* sp. was reported in several studies, 6% (Hassouni and Belghyti, 2006) and 29% (Effiong *et al.*, 2013).

2.3.3 Tape worms (*Raillietina* sp.)

Cestodes are mainly parasites of birds, domestic fowls, turkey and pigeon (Mu *et al.*, 2009). The body of *Raillietina* sp. composed of a series of ribbon-like body segments, gradually enlarging from the anterior end towards the posterior. It is whitish in colour, highly elongated, dorso-ventrally flat and entirely covered with a tegument (Sato *et al.*, 1988). The most important species of *Raillietina* sp. is *Raillietina echinobothridia* which is up to 25cm long (Soulsby, 1982; Mu *et al.*, 2009). *Raillietina* sp. is the major helminth observed in the chickens, 5.7% (Hassouni and Belghyti, 2006), 59.26% (Molla *et al.*, 2012), 11% (Effiong *et al.*, 2013).

2.3.4 Protozoa (*Eimeria* sp.)

Coccidiosis is one of the most common and economically important diseases of chickens worldwide following bacterial diseases, the second largest problem worldwide

wherever poultry is reared in crowded conditions. Coccidial parasites are protozoa belonging to the phylum Apicomplexa. For chicken, coccidiosis is caused by seven species, all from the genus *Eimeria*; *E. acervulina*, *E. brunette*, *E. maxima*, *E. mitis*, *E. necatrix*, *E. praecox* and/or *E. tenella*.

3.0 MATERIALS AND METHODS

3.1 Sample collection

The Red Jungle Fowls were sampled from a Red Jungle Fowl farm located at Jenderam Hulu, Selangor. The population of the fowls reared in the farm was approximately 500 birds. Most of the fowls in the farm were managed semi-intensively and some of them were managed as free range. They are fed with commercial feed specialized for starter, grower and layer, twice daily. A total of 16 birds were selected, 12 were categorized as clinically ill shows respiratory symptoms while the other four were apparently healthy. All the fowls were euthanised using Halal-slaughtering method.

This research project was approved by the Institutional Animal Care and Use Committee (IACUC).

3.2 Blood parasites examination procedure

2ml of blood were collected from jugular vein of the fowls and were kept in Heparin tubes. Some of the blood were used for thin blood smear and stained with Giemsa stain. Some of the blood was also used for direct wet mount to observe for presence of *Microfilaria* sp. and *Trypanosome* sp. To reconfirm for the presence of those two species of blood parasites, Hematocrit Centrifugation Technique (HCT) were done. Lastly, all the blood parasites were examined and identified under compound microscope.

3.3 Ectoparasites examination procedure

The feathers from various parts of the fowls included the head, body, wing and tail were taken and were then soaked in 70% alcohol. The parasites were then collected

from the feathers using fine forceps under stereomicroscope and preserved in 70% alcohol. For examination and identification of the parasites, the parasites were mounted on glass slide using Hoyer's medium and were observed under compound microscope.

3.4 Endoparasites examination procedure

Post mortem were done on all the fowls and the body parts were examined grossly for any endoparasites. The gastrointestinal tract included the large and small intestine were taken and soaked in normal saline before the helminth were collected from the intestines and preserved in 70% alcohol. The nematodes found were directly mounted on the glass slide with Lactophenol medium while the cestodes and trematodes found were stained with Aceto alum carmine staining and mounted on glass slide with DPX medium before all of them are examined and observed under compound microscope.

4.0 RESULTS

4.1 Blood parasitess

4.1.1 Blood parasite species

The blood parasite species that were found in the Red Jungle Fowl were *Microfilaria* sp., *Leucocytozoon sabrazezi*, Trypanosome sp., and Plasmodium sp. (Figure 1-4).

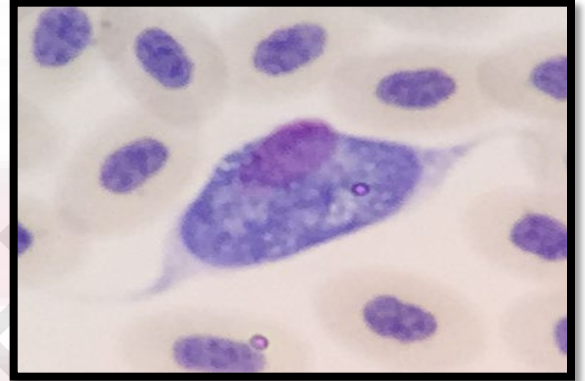
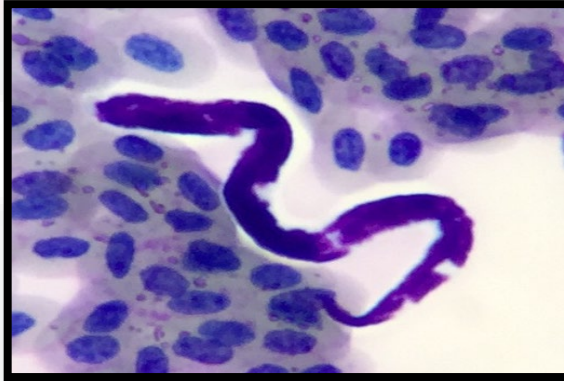

Figure 1 Microfila

Figure 2 *Leucocytozoon sabrazezi*

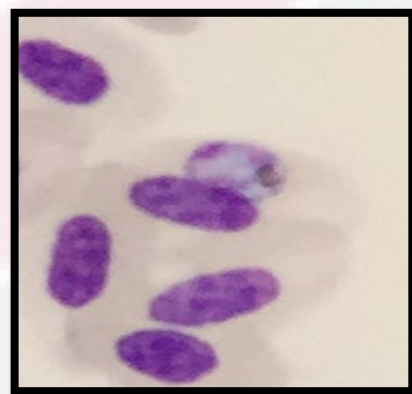
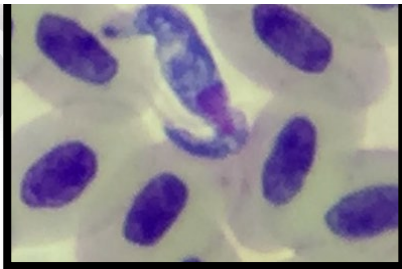

Figure 3 Trypanosome sp.

Figure 4 Plasmodium sp.

4.1.2 Burden of blood parasites

Table 1 Burden of blood parasites between apparently healthy and clinically ill Red Jungle Fowl sampled.

BLOOD PARASITES	STATUS	MEDIAN	RANGE	P VALUE
Leucocytozoon sp.	Clinically ill	0	0 - 4	0.862
	Apparently healthy	-		
Plasmodium sp.	Clinically ill	0		0.862
	Apparently healthy	-		
Trypanosome sp.	Clinically ill	0		0.684
	Apparently healthy	0		
Microfilaria sp.	Clinically ill	0		0.212
	Apparently healthy	0.50		

Based on the data analyzed with SPSS, when $\alpha = 0.05$, there were no significant difference between burden of all of the blood parasite species between apparently healthy and clinically ill Red Jungle Fowls.

4.2 Ectoparasites

4.2.1. Ectoparasite species

The ectoparasite species that were found in the Red Jungle Fowl were *Haemaphysalis* sp. (tick), *Megninia cubitalis* (feather mite), *Lipeurus caponis*, *Goniodes dissimilis*, *Goniocotes hologaster*, *Menacanthus stramineus* and *Menopon gallinae* (lice) (Figure 5–11).

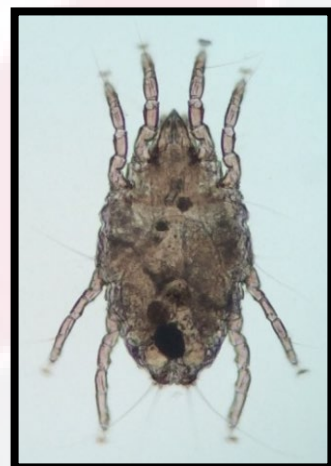

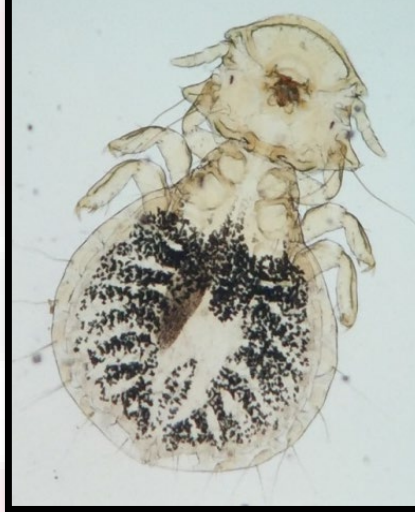Figure 5 *Haemaphysalis* sp.

Figure 6 *Megninia cubitalis*



Figure 7 *Lipeurus caponis*



Figure 8 *Menacanthus stramineus*Figure 9 *Menopon gallinae*Figure 10 *Goniocotes hologaster*Figure 11 *Goniodes dissimilis*

4.2.2 Burden of ectoparasite species

Table 2 Burden of ectoparasites (ticks and lice) between apparently healthy and clinically ill Red Jungle Fowl sampled.

ECTOPARASITES	STATUS	MEAN \pm SE	P VALUE
<i>Haemaphysalis</i> sp.	Clinically ill	1.17 \pm 0.991	0.517
	Apparently healthy	0	
<i>Lipeurus caponis</i>	Clinically ill	38.83 \pm 6.988	0.025

	Apparently healthy	7.50 ± 2.901	
<i>Menacanthus stramineus</i>	Clinically ill	4.83 ± 1.502	0.316
	Apparently healthy	2.0 ± 1.080	
<i>Menopon gallinae</i>	Clinically ill	30 ± 4.758	0.087
	Apparently healthy	12.25 ± 8.721	
<i>Goniodes dissimilis</i>	Clinically ill	5.17 ± 1.065	0.106
	Apparently healthy	1.75 ± 1.109	
<i>Goniocotes hologaster</i>	Clinically ill	3.92 ± 1.654	0.430
	Apparently healthy	1.50 ± 0.957	

Table 3 Burden of ectoparasites (mites) between apparently healthy and clinically ill Red Jungle Fowl sampled.

ECTOPARASITES	STATUS	MEDIAN	RANGE	P VALUE
Feather mites	Clinically ill	3.00	0-4	0.262
	Apparently healthy	1.50		

Based on the data analyzed with SPSS, when $\alpha = 0.05$, there were no significant difference between burden of all of the ectoparasite species between apparently healthy and clinically ill Red Jungle Fowls except for the lice, *Lipeurus caponis* which showed the burden were higher in clinically ill as compared to the apparently healthy fowls.



4.3 Endoparasite species

The endoparasite species that were found in the Red Jungle Fowl were *Heterakis* sp. (cecal worm), *Capillaria* sp. (thread worm), *Raillietina cesticillus*, *Raillietina tetragona*, *Raillietina echinobothrida* (tape worm) and the ova and oocyst found were *Heterakis* ova, *Capillaria* ova and *Eimeria* oocyst (Figure 12 -21).

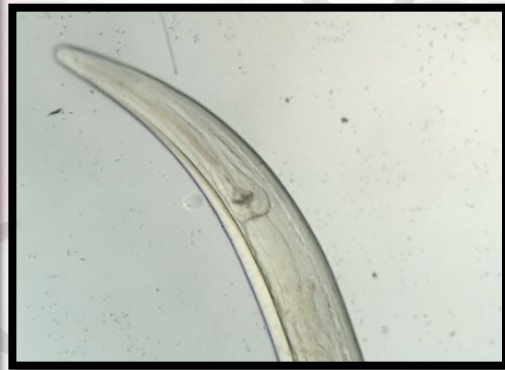
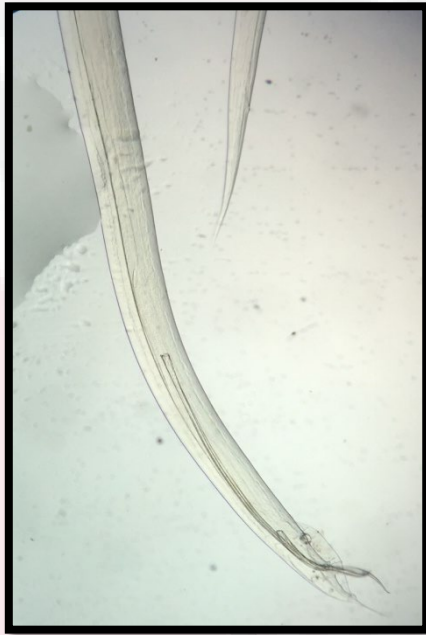

Figure 12 & 13 *Heterakis* sp.

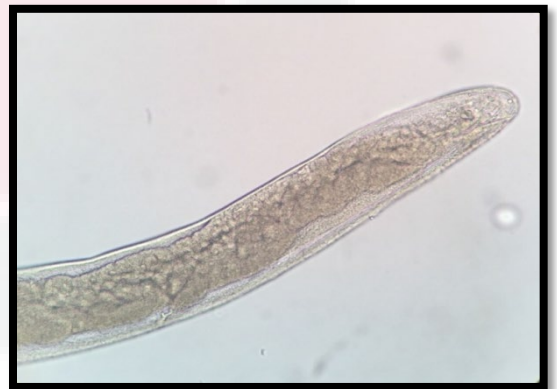
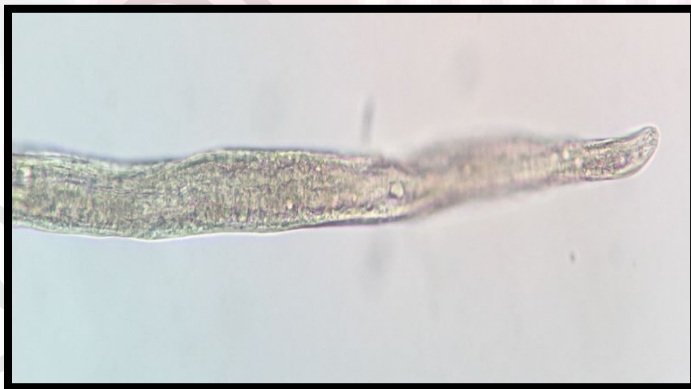
Figure 14 & 15 *Capillaria* sp.

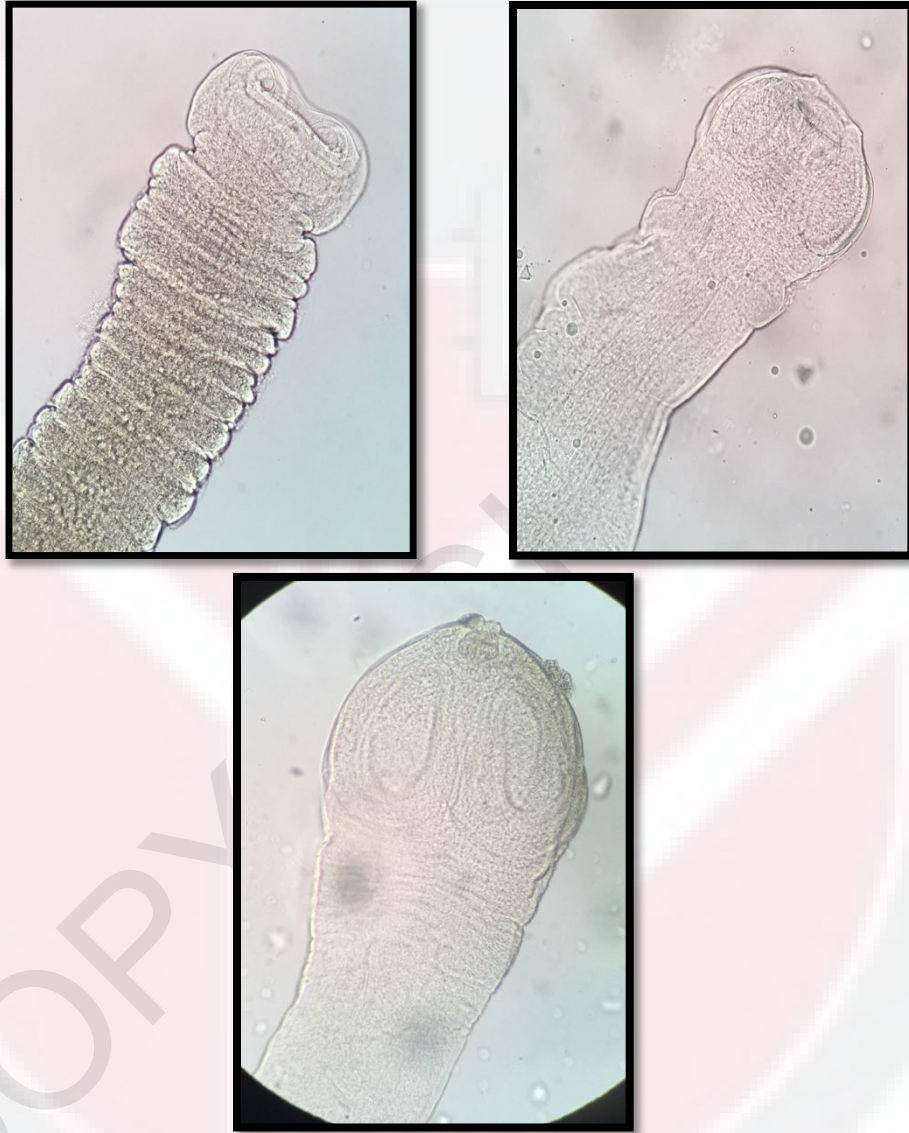

Figure 16,17,18 Raillietina sp.
(*R. cesticillus*, *R. tetragona*, *R. echinobothridia*)

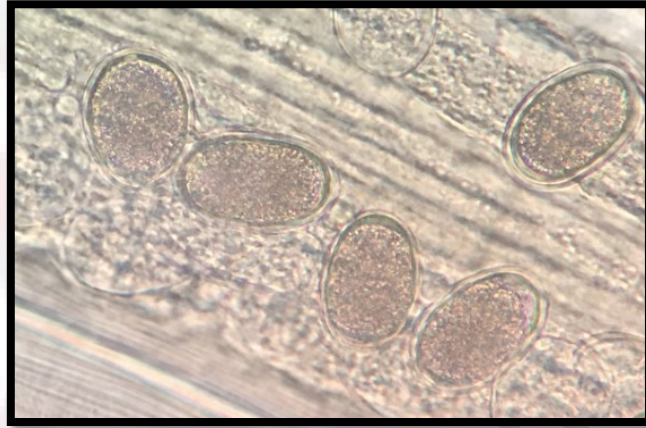


Figure 19 Heterakis ova

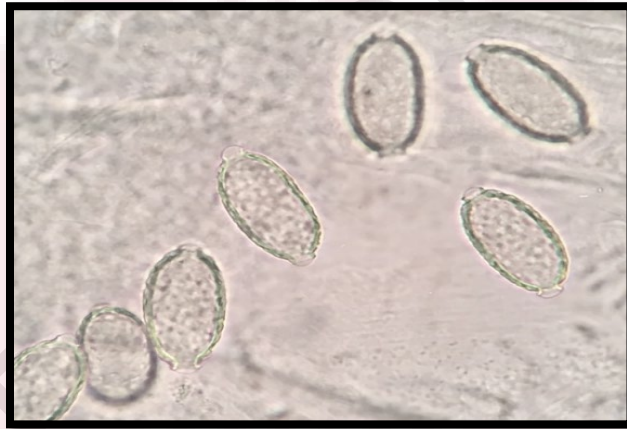

Figure 20 Capillaria ova

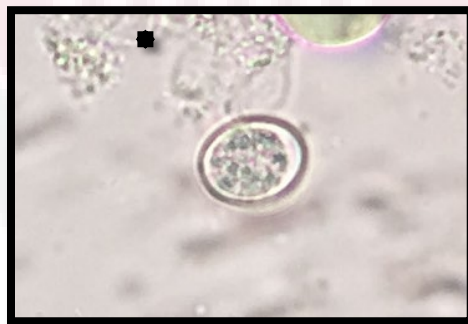

Figure 21 Eimeria oocyst

4.3.2 Burden of endoparasite species

Table 4 Burden of endoparasites between apparently healthy and clinically ill Red Jungle Fowl sampled.

ENDOPARASITES	STATUS	MEAN ±SE	P VALUE
Raillietina sp.	Clinically ill	7.42 ± 4.444	0.619
	Apparently healthy	12.25 ± 9.928	
Heterakis sp.	Clinically ill	24.83 ± 7.605	0.160
	Apparently healthy	4.75 ± 2.428	
Capillaria sp.	Clinically ill	0.17 ± 0.167	0.582
	Apparently healthy	-	

Table 5 Burden of ova and oocyst between apparently healthy and clinically ill Red Jungle Fowl sampled

ENDOPARASITES	STATUS	MEAN ± SE	P VALUE
Capillaria sp.	Clinically ill	279.17 ± 274.653	0.993
	Apparently healthy	275.00 ± 188.746	
Heterakis sp.	Clinically ill	1091.67 ± 365.192	0.767
	Apparently healthy	862.50 ± 735.237	
Eimeria sp.	Clinically ill	11037.50 ± 4389.830	0.155
	Apparently healthy	30175.00 ± 18868.895	
	Apparently healthy	0	

Based on the data analyzed with SPSS, when $\alpha = 0.05$, there were no significant difference between burden of all of the endoparasite species, the ova and the oocyst between apparently healthy and clinically ill Red Jungle Fowls.

5.0 DISCUSSION

Based on current knowledge of reviewed articles, this is the first study in specifically comparing the parasite species and burden between apparently healthy and clinically ill Red Jungle Fowls,. This study has successfully described that the parasite burden is not one of the factors that caused the clinical symptoms in the clinically ill Red Jungle Fowl. As being proved statistically, there are no significant differences between all species and burden of parasite in apparently healthy and clinically ill Red Jungle Fowls except for the lice, *Lipeurus caponis*.

According to Bermudez *et al.* (2008), disease is a result of impaired body functions and the degree of impairment depends on the severity of the disease. This impairment may be caused by various pathogens such as virus, bacteria and parasites. It can also be caused by nutritional deficiency, physical injury or toxic substances. Thus, in case of this study, some other causes other than parasites may be causing the clinical symptoms in clinically affected birds. They are most likely to be infected with other pathogens which are the virus and bacteria.

This study also shows that Red Jungle Fowls are a hardy species especially towards the parasitic infection. As shown from the fowls sampled, all of the apparently healthy birds are not showing any clinical symptoms although they have high parasite burden.

As compared to a study on village chickens done by Adele and Dipeolu (1975), it stated that parasitism ranks high among factors that threaten village chicken production.

The authors also reported that mortality due to parasitic diseases was higher than those attributed to Newcastle disease, an acknowledged most endemic and mortality causing viral infection of poultry. Thus, though the healthy ones have high parasite count, they are not showing any clinical symptoms as they can withstand the parasite burden and the species seemed to be hardy towards parasite burden.

6.0 CONCLUSION

Generally, the apparently healthy and clinically ill Red Jungle Fowls have the same species and burden of parasites harbouring them. As being proved statistically, there are no significant differences between all species and burden of parasite in apparently healthy and clinically ill Red Jungle Fowls except for the lice, *Lipeurus caponis*. Through this study, Red Jungle Fowl is also found as a species that is hardy and 'resistant' to parasite burden.

7.0 RECOMMENDATION

In future study, it is best to use larger sample size to obtain a more reliable data. It is highly suggestive to use the same number of fowls for both apparently healthy and clinically ill groups. Optimally, more farms from more states should be involved to assess whether different location will affect the parasite species and burden of the Red Jungle Fowls. In addition, fowls from different age and gender groups should be included to cover all fowls in a farm.

To support the result obtained, the organs such as lung, liver and kidney should also be isolated and cultured for bacteria and virus identification for confirmatory description of parasite does not causing the clinical symptoms in the fowls.

8.0 REFERENCES

- Ali, M.M. (1969). Observations on some filariid worms from Indian birds with a description of two genera. *Zool. Anz.* 183: 309-316.
- Amin-Babjee, S.M., C.C. Lee & Mahmood, A. A. (1997). Prevalance of ectoparasite infestation in different age groups of village chickens. *Journal of Veterinary Association Malaysia* 9(2):55-59.
- Amin-Babjee, S.M., C.C. Lee & M. Krishnasamy. (1985). A preliminary survey of parasites of Malaysian red jungle fowl (*Gallus gallus spadiceus*). *Kaj. Vet.* 17: 141-146.
- Anderson, R.C. (2000). Nematode parasites of vertebrates: Their development and transmission. Second Edition. *CABI Publishing: Wallingford, England.* pp. 472-475.
- Baker, J. R. (1956). Studies on *Trypanosoma avium*.
- Beebe, W. (1926). *Pheasants: Their Lives and Homes*. Garden City, New York: Doubleday, Page & Co.
- Bennett, G. F., Whiteway, M. & Woodwothlynas, C. (1982). A host-parasite catalogue of the avian haematozoa. *Memorial Univ. Newfoundland Occ. Pap. Biol.* 5:1-243.
- Bennett, G. F., R. A. Earle, M. A. Peirce, F. W. Huchzermeyer & D. Squires-Parsons. (1991). Avian Leucocytozoidae: The leucocytozoids of the Phasianidae sensu lato. *Journal of Natural History* 25: 1407-1428.
- Bishop, M. A. & G. F. Bennett. (1992). Host parasite catalogue of the avian haematozoa: Supplement 1 and bibliography of the avian blood-inhabiting haematozoa: Supplement 2. *Occasional Papers in Biology, Memorial University of Newfoundland* 15: 1-244.
- Chavatte J.M., Chiron F., Chabaud A., Landau I. (2007). Probable speciation by host-vector fidelity: 14 species of Plasmodium from magpies. *Parasite* 14(1):21-37.

- Clarke, C. H. D. (1935). Blood parasites of ruffled grouse (*Bonasa umbellus*) and spruce grouse (*Canachites Canadensis*), with description of *Leucocytozoon bonasae* n. sp. *Canadian Journal of Research* 12: 646-650.
- Colebrook E, Wall R. (2004). Ectoparasites of livestock in Europe and the Mediterranean region. *Veterinary Parasitology*. 120: 251-274.
- Dunn J.C., Cole, E.F. & Quinn, J.L. (2011). Personality and parasites: Sex dependent associations between avian malaria infection and multiple behavioral traits. *Behavioral Ecology and Sociobiology*. 65:1459-1471.
- Effiong, E., Offiong, A. O. E., Umoh, J. U., Essien, C. A., Idiong, N. B. (2013). A survey of gastrointestinal helminthes of local chickens in Abak Local Government Area of Akwa Ibom State. *International Journal of Sciences: Basic and Research (IJSBAR)*. V. 9, No 1, pp 1-4.
- Fabiyi, J.P. (1996). Association between duration of humid season and geographical distribution of patterns of different species of chewing lice (Mallophaga: Insects) infesting domestic chickens in Nigeria. *Journal of Parasitology*. 82: 1034-1036.
- Greiner, E.C. (1991). Leucocytozoonosis in waterfowl and wild galliform birds. *Bulletin of the Society for Vector Ecology* 16:84-93.
- Hassouni, T. and Belghyti, D. (2006). Distribution of gastrointestinal helminthes in chicken farms in the Gharb region-Morocco. *Parasitol. Res.*, 99:181-183.
- Hussen, H., Chaka, H., Deneke, Y., & Bitew, M. (2012). Gastrointestinal Helminths Are Highly Prevalent in Scavenging Chickens of Selected Districts of Eastern Shewa Zone, Ethiopia. *Pak J Biol Sci*. 15; 15(6):284-9.
- Jansen, J. and Pandey, V.S. (1989). Observations on helminth parasites of domestic fowls in Zimbabwe. *Zimbabwe Veterinary Journal*. 20(1): 15-17.
- Jordan, F.T.W., (1990). Leucocytozoonosis in Poultry disease, F.T.W. Jordan (ed.). 3rd Edition. Bailliere Tindall, London, UK, p. 245.
- Jordan, F.T.M. & Pattison, M. (1996). Poultry diseases. 4th edition, London: W.B. Saunders, 283-286.

- Konto, M., Biu, A.A., Ahmed, M.I. and Charles, S. (2014). Prevalence and seasonal abundance of ticks on dogs and the role of *Rhipicephalus sanguineus* in transmitting Babesia species in Maidugiri, North-Eastern Nigeria. *Vet. World*, 7(3): 119-124.
- Konto, M., Fufa, G.I., Khan M.K. (2015). Tick fauna of Malaysia red jungle fowl (*Gallus gallus*) in Bangi, Malaysia. *Veterinary World* 8:1167-1171.
- Lee, C.C. & Amin Babjee, S.M.(1993). New host records of parasites in the Malayan Red Jungle Fowl, *Gallus gallus spadiceus*. *Pertanika J. Trap. Agric. Sci.* 16(2): 107-110.
- Marizvikuru, M. & Patrick, J. M. (2011). Point prevalence study of gastrointestinal parasites in village chickens of Centane district, South Africa. *African Journal of Agricultural Research* Vol. 6(9), pp. 2033-2038.
- Matur, B. & Dawam, N.M.Y. (2010). Gastrointestinal helminth parasites of local and exotic chickens slaughtered in Gwagwalada, Abuja (FCT), Nigeria. *New York Science Journal*. 3(5):96-99.
- Molla, W., Haile, H., Almaw, G. and Temesgen W. (2012). Gastrointestinal helminthes of local backyard chickens in North Gondar Administrative Zone, Ethiopia. *Revue Medecine Veterinaire*, 163:362-367.
- Molyneux, D.H. (1973a). *Trypanosoma bouffardi* of West African Ploceidae (Aves). *Parasitology* 66:215-230.
- Monnig, H.O. (1950). *Veterinary Helminthology and Entomology*. 3th ed. The Williams and Wilkins company. Great Britain.
- Mu, L. L., H. Y. & Yan, B.Z. (2009). Comparative study on morphology and development of two species of Raillietina from chicken. *Zhongguo Ji Sheng Chong Xue Yu Ji Sheng Chong Bing Za Zhi* 27(3): 232-236.
- Mungube, E.O., Bauni, S.M., Tenhagen, B.A., Wamae, L.W., Nzioka, S.M., Muhammed L. and Nginyi, J.M. (2007). Prevalance of parasites of the local scavenging chickens in a selected semi-arid zone of Eastern Kenya. *Tropical Animal Health and Production*, 40:101-109.

- Nishida, T., Y. Hayashi, T. Hashiguchi & S. Mansjoer. (1985). Morphological identification and distribution of jungle fowls in Indonesia. *Jap. J. Zootech. Sci.* 56: 598-610.
- Perkins, S.L., Austin, C. (2008). Four new species of Plasmodium from New Guinea Lizards: Integrating Morphology and Molecules. *J. Parasitol.* 95(2):1.
- Permin, A., Esmann J.B., Hoj C.H, Hove, Mukaratirwa. (2002). Ecto, Endo and Haemoparasites in free-range chickens in the Goromonzi District in Zimbabwe. *Preventive Veterinary Medicine.* 45: 237-245.
- Phiri, I.K., Phiri, A.M., Ziela, M., Chota, A., Masuku, M. & Monrad J. (2007). Prevalance and distribution of gastrointestinal helminthes and their effects on weight gain in free-range chickens in Central Zambia. *Tropical Animal Health and Production*, 39: 309-315.
- Poulin, R., Morand, S. (2004). *Parasite Biodiversity*. Smithsonian Books, Washington.
- Poulsen, J., Permin, A., Hindsbo, O., Yelifari, L., Nansen, P. Bloch, P. (2000). Prevalence and distribution of gastrointestinal helminthes and haemoparasites in young scavenging chickens in upper eastern region of Ghana, West Africa. *Preventive Veterinary Medicine.* 45: 237-245.
- Ralph E. William. (1949). USA: Veterinary entomology: Livestock and companion animals. Florida: CRC Press.
- Roberts, L. S. & Janovy, J. R. (2009). Foundations of Parasitology. 8th ed. The McGraw-Hill companies.
- Rysavy, B. V. Barus & M.A. Fernando. (1973). Two helminth species from *Gallus lafayetti* (Galliformes) in Ceylon. *Folia Parasitol.* 20: 39-40.
- Sato, H., Okamoto, M., Ohbayashi, M. & Basanez, M. G. (1988). A new cestode, *Raillietina oligocapsulata* and *R. demerariensis* from Venezuelan mammals. *Japanese Journal of Veterinary Research*, 36(1): 31-45.
- Sonaiye. E.B. & Swan, S.E.J. (2004). Small – scale Poultry Production; Technical guide. FAO Animal Production and Health Manual I. FAO, Rome, Italy.

- Soulsby, E. J. L. (1982). Helminthes, arthropods and protozoa of domesticated animals. 7th Edition. Billiere Tindall, London, UK.
- Stuht, J. N., W. W. Bowerman, and D. A. Best. (1999). Leucocytozoonosis in nesting bald eagles in Michigan and Minnesota. *Journal of Wildlife Diseases* 35:608-612.
- Swai E.S., Karimuribo, E.D. Kyakaisho, P.F., Mtui, P.F. (2007). Free range village chickens on the humid coastal belt of Tanga, Tanzania: Their roles, husbandary and health status. *Livestock Research for Rural Development*. 19, Article 104.
- Yadav, K.V., Adav, A.K. and Tandon. V. (1991). Helminth parasitism of domestic fowl (*Gallus domesticus*) in a subtropical high-rainfall area of India. *Beitr. Trop. Landwirtschaft. Veterinarmed.* 29, 97-104.
- Yoriyo, K.P., Adang, J.P., Fabiyi, S.U., Oriyo, P., K. I., Adang, J.P. and Fabiyi, S. U. (2008). Helminthes parasites of local chickens in Bauchi State, Nigeria. *Science World Journal* 3, 35-37.