



**UNIVERSITI PUTRA MALAYSIA**

***HISTOPATHOLOGICAL EXAMINATION ON SELECTED ORGANS OF  
ARTHRITIC RATS TREATED WITH QUINONE RICH FRACTION OF  
Ardisia crispa***

**LIEW KAI MAN**

**Ip  
FPSK2 2021 4**



**HISTOPATHOLOGICAL EXAMINATION ON SELECTED ORGANS OF  
ARTHRITIC RATS TREATED WITH QUINONE RICH FRACTION OF  
*Ardisia crispera***

**LIEW KAI MAN**

**A PROJECT PAPER SUBMITTED AS PARTIAL REQUIREMENT FOR  
THE DEGREE OF BACHELOR OF SCIENCE (BIOMEDICAL SCIENCES)**

**DEPARTMENT OF BIOMEDICAL SCIENCES  
FACULTY OF MEDICINE AND HEALTH SCIENCES  
UNIVERSITI PUTRA MALAYSIA**

**2021**

## ABSTRACT

### HISTOPATHOLOGICAL EXAMINATION ON SELECTED ORGANS OF ARTHRITIC RATS TREATED WITH QUINONE RICH FRACTION OF *Ardisia crispa*

Liew Kai Man<sup>a</sup>, Razana Mohd Ali<sup>b</sup>, Roslida Abd Hamid<sup>a</sup>

<sup>a</sup>*Department of Biomedical Sciences, Faculty of Medicine and Health Sciences,*

*Universiti Putra Malaysia*

<sup>b</sup>*Department of Pathology, Faculty of Medicine and Health Sciences,*

*Universiti Putra Malaysia*

**Introduction:** Rheumatoid arthritis (RA), a chronic autoimmune inflammatory disease is reported to be mediated via excessive angiogenesis. A few conventional drugs used in treating RA are reported to exhibit undesirable adverse effects. Thus, the public has turned into herbal remedies in RA treatment. *Ardisia crispa* locally known as “Mata itik”, is a herbal plant reportedly exhibits various pharmacological effects including anti-inflammation, antiulcer, antimetastatic and antitumor. The hexane extract of *Ardisia crispa* roots (ACRH) and its isolated quinone rich fraction (QRF) were reported to exhibit antiarthritic effect. Specifically, QRF was recently shown to exert antiarthritic effect mediated via angiogenesis suppression in collagen-induced arthritis in male Sprague Dawley rats for 28 days. Nevertheless, the safety of the sample (QRF) orally and chronically administered, has yet to be determined. Therefore, in the present study, apart from the therapeutic effect of QRF at various dosages (3, 10 and 30 mg/kg) which has been already clarified, the hazardous potential of QRF should be taken into account to confirm its safety for a long-term consumption. **Objective:** This study aimed to identify and demonstrate the non-toxicity of QRF by assessing the histopathological changes in selected organs i.e liver, kidney and spleen of arthritis rats treated with QRF for 13 days. **Methodology:** A semi-quantitative histopathological evaluation on the selected organs i.e liver, spleen and kidney of arthritic control, vehicle (normal) and QRF-treated groups were carried out, respectively. The organs underwent a series of histopathological processes including tissue fixation, tissue processing, tissue embedding, tissue sectioning, slide staining with haematoxylin-eosin stain and microscopic examination. Any changes in histopathological features by assessing the microscopic changes was analysed via established histopathological scoring. The data was then expressed as Mean  $\pm$  Standard Error of Mean (S.E.M.) and analysed using one-way ANOVA, followed by Tukey’s post hoc test for multiple comparison. Values with  $p < 0.05$  was statically significant. **Result:** From the histopathological evaluation and scoring, QRF-treated groups (3, 10 and 30 mg/kg) showed no significant difference between vehicle and arthritic control groups,

respectively. Interestingly, a mild focal inflammation was observed in the liver of treatment and control groups, and kidney of 3mg/kg and 30mg/kg treatment groups. **Discussion:** The mild focal inflammation that observed in both liver and kidney was the inconsistent background lesion that may occur spontaneously in rodents' chronic toxicity test. Therefore, the mild focal inflammation is non-specific to indicate toxicity of QRF. **Conclusion:** From the histopathological findings, quinone rich fraction of *Ardisia crispa* (QRF) is able to exhibit antiarthritic effect without inducing toxicity to the liver, kidney and spleen at the mentioned dosages. For future research direction, an extensive analysis can be carried out to further investigate the background lesion that observed in the liver and kidney of the rat models. Moreover, a chronic toxicity test for longer period and higher dosages with other additional organs such as brain, stomach, and heart can be carried out to confirm the safety profile of QRF.

**Keywords:** *Ardisia crispa*, Rheumatoid arthritis, quinone rich fraction (QRF), liver scoring, histopathological changes

## ABSTRAK

### PEMERIKSAAN HISTOPATOLOGI TERHADAP ORGAN TERPILIH TIKUS ARTRITIK DIRAWAT DENGAN FRAKSI KAYA KUINON *Ardisia crispa*

Liew Kai Man<sup>a</sup>, Razana Mohd Ali<sup>b</sup>, Roslida Abd Hamid<sup>a</sup>

<sup>a</sup>Jabatan Sains Bioperubatan, Fakulti Perubatan dan Sains Kesihatan,  
Universiti Putra Malaysia

<sup>b</sup>Jabatan Pathologi, Fakulti Perubatan dan Sains Kesihatan,  
Universiti Putra Malaysia

**Pengenalan:** Arthritis reumatoid (RA), penyakit radang autoimun kronik dilaporkan dimediasi melalui angiogenesis berlebihan. Beberapa ubat konvensional yang digunakan dalam merawat RA dilaporkan menunjukkan kesan buruk yang tidak diinginkan. Oleh itu, orang ramai telah bertukar menggunakan ubat-ubatan herba dalam rawatan RA. *Ardisia crispa* yang dikenali sebagai "Mata itik", adalah tumbuhan herba yang dilaporkan menunjukkan pelbagai kesan farmakologi termasuk anti-radang, antiulser, antimetastatik dan antitumor. Ekstrak heksana akar *Ardisia crispa* (ACRH) dan fraksi kaya kuinonnya (QRF) telah dilaporkan menunjukkan kesan antiartritik. Secara khusus, QRF baru-baru ini terbukti memberikan kesan antiartritik yang dimediasi melalui penindasan angiogenesis pada arthritis yang disebabkan oleh kolagen pada tikus Sprague Dawley jantan selama 28 hari. Walaupun begitu, keselamatan sampel (QRF) diberikan secara oral dan kronik, masih belum ditentukan. Oleh itu, dalam kajian ini, selain daripada kesan terapi QRF pada pelbagai dos (3, 10 dan 30 mg/kg) yang telah diperjelaskan, potensi berbahaya QRF harus diambil kira untuk mengesahkan keselamatannya untuk jangka masa panjang - penggunaan jangka masa. **Objektif:** Kajian ini bertujuan untuk mengenal pasti dan menunjukkan ketoksikan QRF dengan menilai perubahan histopatologi pada organ terpilih iaitu hati, ginjal dan limpa tikus arthritis yang dirawat dengan QRF selama 13 hari. **Metodologi:** Pemeriksaan histopatologi semikuantitatif terhadap organ terpilih iaitu hati, limpa dan ginjal dari kawalan artritik, kawalan kenderaan dan kumpulan yang dirawat dengan QRF. Organ-organ tersebut menjalani serangkaian proses histopatologi termasuk penetapan tisu, pemprosesan tisu, penyisipan tisu, pemotongan tisu, pewarnaan slaid dengan pewarnaan haematoxylin-eosin dan pemeriksaan mikroskopik. Sebarang perubahan ciri histopatologi dengan menilai perubahan mikroskopik dianalisis melalui pemarkahan histopatologi yang ditetapkan. Data kemudian dinyatakan sebagai min  $\pm$  ralat piawai min (S.E.M.) dan dianalisis menggunakan ANOVA sehalu, diikuti dengan ujian post hoc Tukey untuk perbandingan berganda. Nilai dengan  $p < 0.05$  adalah signifikan secara statistik. **Hasil:** Dari penilaian histopatologi dan pemarkahan, kumpulan yang dirawat dengan QRF (3, 10 dan 30 mg/kg) menunjukkan tiada perbezaan yang signifikan dengan kumpulan kawalan kenderaan dan arthritic. Menariknya, keradangan fokus ringan diperhatikan dalam

hati rawatan dan kumpulan kawalan, dan ginjal 3mg/kg dan 30mg/kg rawatan kumpulan. **Perbincangan:** Keradangan fokus ringan yang diperhatikan di hati dan ginjal diwakili sebagai luka latar belakang yang tidak konsisten dan mungkin berlaku secara spontan dalam kajian ketoksikan kronik tikus. Oleh itu, keradangan fokus ringan tidak khusus untuk menunjukkan ketoksikan QRF. **Kesimpulan:** Dari penemuan histopatologi, fraksi kaya kuinonnya (QRF) dapat menunjukkan kesan antiartrititik tanpa menimbulkan keracunan pada hati, ginjal dan limpa pada dos yang diberikan. Untuk arahan penyelidikan masa depan, analisis yang selanjut boleh dijalankan untuk menyiasat lagi lesi latar belakang yang diperhatikan di hati dan buah pinggang model tikus. Selain itu, kajian ketoksikan kronik untuk tempoh yang lebih lama dan dos yang lebih tinggi dengan organ tambahan lain seperti otak, perut, dan jantung boleh dijalankan untuk mengesahkan profil keselamatan QRF.

**Kata kunci:** *Ardisia crispa*, Arthritis reumatoid, pecahan kaya quinone (QRF), pemarkahan hati, perubahan histopatologi

## ACKNOWLEDGEMENT

First and foremost, I would like to express my gratitude towards my supervisor, Prof. Dr. Roslida has been ever so willing to support and guide me during this research project and provide useful advice and inspiration as well as information on my first and the last project in the degree course.

Hereby, I would like to express my appreciation to Dr. Razana Ali, co-supervisor of my FYP for accepting me as her supervisee and gave me the opportunity to learn so much special and interesting knowledge on histology in such a short period of time. I would also like to give my acknowledgement to Dr. Hasni, our FYP coordinator who always keeps contact and updates us with the latest information between the Dean office and our faculty as well as helps us to settle down the date to go back to faculty for laboratory work.

My sincere appreciation to every assisting staff in the Histology lab, Faculty of Medicine and Health Sciences, University Putra Malaysia, especially Miss Juita and Miss Noor, for teaching the related knowledge and technique when working in the histology lab, being so friendly and supervised me while I was undergoing my project. A special thanks to John Anak Blin (PhD student of Dr. Roslida) for his help, advice and constructive suggestions throughout this research project. I would like to apologize if I made any mistake during the discussion.

Lastly but not least, I sincerely appreciate those who helped and mentally supported me in this period of time. I would like to thank all my family members and friends who showed their love and care about me by keeping up with me. I extend all my gratitude and thanks, without all of you this project will not be so successful and completed. Thank you all very much.



## TABLE OF CONTENT

	<b>Page</b>
<b>ABSTRACT</b>	i
<b>ABSTRAK</b>	iii
<b>ACKNOWLEDGEMENTS</b>	v
<b>APPROVAL</b>	vii
<b>DECLARATION</b>	viii
<b>TABLE OF CONTENTS</b>	ix
<b>LIST OF TABLES</b>	xi
<b>LIST OF FIGURES</b>	xii
<b>LIST OF ABBREVIATION</b>	xiii
<b>CHAPTER 1: INTRODUCTION</b>	
1.1 Background of study	1
1.2 Objective	
1.2.1 General objective	4
1.2.2 Specific objectives	4
1.3 Hypothesis	5
<b>CHAPTER 2: LITERATURE REVIEW</b>	
2.1 Histopathological	6
2.1.1 Histopathological assessment	7
2.1.2 Histopathological Scoring system	9
2.1.3 Semiquantitative assessment	13
2.2 Rheumatoid Arthritis	15

2.2.1	Adverse effect of conventional therapy for Rheumatoid Arthritis	17
2.3	<i>Ardisia crispa</i>	
2.3.1	Description of <i>Ardisia crispa</i>	19
2.3.2	Morphology of <i>Ardisia crispa</i>	20
2.3.3	Ethnobotanical uses	22
2.4	Quinone rich fraction of <i>Ardisia crispa</i> (QRF)	23
2.5	Toxic effect of hexane extract and rich fraction of <i>Ardisia crispa</i> roots	24
<b>CHAPTER 3: METHODOLOGY</b>		
3.1	Animal samples	26
3.2	Histopathological examination	28
3.3	Histopathological scoring	31
3.4	Statistical Analysis	32
<b>CHAPTER 4: RESULTS</b>		
4.1	Histopathological findings	33
4.2	Histopathological evaluation	36
<b>CHAPTER 5 DISCUSSION</b>		42
<b>CHAPTER 6 CONCLUSION AND RECOMMENDATIONS</b>		
6.1	Conclusion	49
6.2	Recommendations	50
<b>REFERENCES</b>		51
<b>APPENDICES</b>		60

## LIST OF TABLES

TABLE		PAGE
2.1	Diagnosis Parameter for different organs in Toxicologic Pathology	11-12
2.2	Adverse effect of conventional therapy in Rheumatoid Arthritis	18
2.3	The toxic effect of hexane extract and rich fraction of <i>Ardisia crispa</i>	25
3.1	List of treatments that given to the animal models	27
3.2	Diagnostic features for selected organs	31
4.1	Lesion scoring of liver, kidney and spleen from male Sprague Dawley rats in all treatment groups	35

## LIST OF FIGURES

FIGURE		PAGE
2.1	Hand drawn morphology of <i>Ardisia crispera</i>	20
2.2	The leaves and fruits of <i>Ardisia Crispera</i>	21
2.3	Chemical structure of 2-methoxy-6-undecyl-1,4-benzoquinone	23
3.1	Flowchart of histology tissue processing	30
4.2.1	Photomicrograph of the normal liver sections of rats at the end experiment	36
4.2.2	Photomicrograph of focal inflammation in the liver sections of rats at the end experiment	37 – 38
4.2.3	Photomicrograph of the normal kidney sections of rats at the end experiment	39
4.2.4	Photomicrograph of focal inflammation in the renal parenchyma of experimental rats at the end of experiment	40
4.2.5	Photomicrograph of the normal spleen sections of rats at the end experiment	41

## LIST OF ABBREVIATIONS

ACRH	<i>Ardisia crispa</i> root hexane fraction
ANOVA	Analysis of variance
CIA	Collagen induced arthritis
CMC	Carboxymethylcellulose
DMARD	Disease-modifying antirheumatic drugs
DPX	Dibutylphthalate Polystyrene Xylene
H & E	Hematoxylin and Eosin stain
mg/kg	milligram per kilogram
NSAID	Non-steroidal anti-inflammatory drugs
QRF	Quinone rich fraction
RA	Rheumatoid Arthritis
TQF	Triterpine-quinone fraction
Tukey HSD test	Tukey Honest Significant Different Test

## CHAPTER 1

### INTRODUCTION

#### 1.1 Background

Histopathology is a diagnosis and study of the signs of a disease tissue under a microscope, while histopathology assessment is a tissue examination that is able to provide an extensive information in characterizing and diagnosing the diseased tissue (The Royal College of Pathologists, 2021; Gurcan *et al.*, 2009). Besides, histopathology assessment is commonly used in toxicology studies to assess the potential hazardous and safety of a drugs, chemical, biologics or treatment (Crissman *et al.*, 2004). Since histopathology assessment is able to provide histopathology images from the tissues, it is then considered as the “gold standard” in diagnosing a disease (Rubin *et al.*, 2008). Hence, it has been widely used by the professionals to reveal the structural alteration of the spontaneous or induced disease (Slaoui & Fiette, 2011).

Rheumatoid arthritis (RA) is an autoimmune chronic inflammatory disease that affects the joints which is lined with synovial membrane and causes pain, swelling and tenderness (Guo *et al.*, 2018). According to the World Health Organization (WHO), there is approximately 0.5-1.0% prevalence of RA

reported globally, and it tends to affect females over male. Statistics have shown that prevalence cases of rheumatoid arthritis rose from 5.3% in 1990 to 9.4% in 2017, while the incidence cases was rose from 5.9% in 1990 to 10.5% in 2017 (Safiri *et al.*, 2019). Interestingly, RA commonly affects Indian population as compared to Chinese and Malay in Malaysia (Teh *et al.*, 2014).

Many recent studies have provided that the current conventional treatment for RA shows effective results in reducing pain, swelling and the progression of RA (Bullock *et al.*, 2018). For instance, Non-steroidal Anti-inflammatory Drugs (NSAIDs), Disease-modifying antirheumatic drugs (DMARDs) and corticosteroids are commonly used for RA treatment. Also, the combination of the drugs is widely practised in maximizing the effects of treatment (Chopra *et al.*, 2008). However, the use of conventional drugs is reported to cause undesirable side effects and complications such as renal, hepatic and cardiovascular toxicity (Crofford, 2013; Kamal and Baldi, 2015). Hence, the public have turned to an alternative way to replace conventional drugs with herbal remedies (Padher & Bhalekar, 2018).

*Ardisia crispa* (Thunb) A. DC is an herbal plant from the Primulaceae Batsch ex Borkh. family (Plants of the World Online, 2017). The plant is widely distributed in east Asia including Malaysia, Indonesia, Japan, China and India (Hamsin *et al.*, 2013). The roots and leaves of *Ardisia crispa* is traditionally used to treat scurvy, sore throat, angina, rheumatic disease, diarrhea, fever and so on

(Kobayashi & De Mejía, 2005). In addition, *Ardisia crispa* (Thunb) A. DC was reported to possess various medicinal properties for human ailment treatment including antioxidant (Jindal & Mohammad, 2012), anti-inflammation, antipyretic and antihyperalgesic (Lau *et al.*, 2009; Roslida & Kim, 2008), antimetastatic and antitumor (Kang *et al.*, 2001; Yeong *et al.*, 2013), antiarthritic (Hamid *et al.*, 2017), anti-angiogenesis (Hamsin *et al.*, 2013; Jun *et al.*, 2019) and so forth.

In Malaysia, *Ardisia crispa* (Thunb) A. DC is generally known as “Mata itik” (Nordin *et al.*, 2017). Interestingly, the hexane extract of *Ardisia crispa* roots (ACRH) has been reported to exhibit antiarthritic effect (Hamid *et al.*, 2017). A recent study proposed that the Quinone rich fraction (QRF) was shown to exert a therapeutic antiarthritic effect mediated via angiogenesis suppression in collagen-induced arthritis in male Sprague Dawley rats for 28 days at various dosages (3, 10 and 30mg/kg) (Blin *et al.*, 2021). However, the safety of the sample (QRF) administered orally and chronically remains to be determined. Thus, this fundamental study was carried out to determine its hazardous potential and safety of QRF for a long-term consumption by observing the histopathological alteration of the liver, kidney and spleen of the arthritic rats.

## 1.2 Objectives

### 1.2.1 General objective

The study was aimed to investigate the safety profile of QRF in treating collagen-induced arthritis by identifying the histopathological changes on the kidney, spleen and liver after 13 days of quinone rich fraction of *Ardisia crispa* (QRF) administration in arthritic rats.

### 1.2.2 Specific objectives

- To assess the microscopic features of liver, spleen and kidney in QRF-treated group (3, 10 and 30mg/kg), vehicle control group and arthritic control group.
- To compare the histopathology alteration of liver, spleen and kidney in QRF-treated group (3, 10 and 30mg/kg) with vehicle control group and arthritic control group.

### 1.3 Hypothesis

It is hypothesized that the QRF shows no significant histopathological changes in liver, spleen and kidney of QRF-treated groups at 3, 10 and 30mg/kg after 13 days treatment.



## CHAPTER 2

### LITERATURE REVIEW

#### 2.1 Histopathology

Histopathology is the descriptive science that involves the examination of cell morphology of a tissue or cells under a microscope (The Royal College of Pathologists, 2021). It is extensively practised in most of the countries around the world and still in transitional stage especially in the developing countries (Sikandar, 2018). According to Slaoui and Fiette (2011), histopathology is an important diagnosis tool based on the histology of human or animal and is achieved by examining the thin layer of tissue section from various organs. Besides, histopathology provides important information for disease prognosis, disease identification, lesion differentiation and grading in quantitative analysis, and treatment decision making (Rastogi, 2018). In addition, histopathology is useful in discovering the causes and pathogenesis of the disease (Sikandar *et al.*, 2012). Interestingly, histopathology is usually used in toxicology studies to assess the potential hazardous and safety of a drugs, chemical, biologics or treatment (Crissman *et al.*, 2004).

### 2.1.1 Histopathology assessment

Histopathology assessment is a procedure to evaluate a 2D or 3D biological microstructure from the slide, identify, distinguish, interpret and grading the normal and abnormal histological alteration that can be observed from tissue (Crissman *et al.*, 2004). According to Gurcan *et al.* (2009), histopathology assessment is able to provide extensive information in characterizing and diagnosing the diseased tissue by providing the principal view of the histological structure of the tissue to compare between the control group and the treatment group. Besides, histopathology assessment also supports and confirms the test result of biochemical assessment by providing the image of the structural alteration (Kaid *et al.*, 2019).

In histopathological assessment, the design of an experiment and the sample used in the experiment are the important standpoints that are associated with valid results (Meyerholz & Beck, 2018). Ruehl-Fehlert *et al.* (2003) proposed that the organs that need to be used for histopathology evaluation depend upon the purpose of the study since none of the guidelines did mention which organs should be used in histopathological assessment. Thus, study objective and related literature reviews are essential in determining the part of organs to be used in histopathological evaluation (Gibson-Corley *et al.*, 2013). For example, liver, kidney, heart, testes, brain, spleen and adrenal glands are recommended to be used for histopathology assessment in general toxicology

research (Seller *et al.*, 2007). In the process of histopathology assessment, the knowledge of the experimental design such as species and age of animal model, route of exposure, dosage and duration of drug exposure should be available prior to the slide evaluation in toxicological histopathology (Crissman *et al.*, 2004).



### 2.1.2 Histopathological Scoring System

Tissue scoring system is a process to grade the sectioned tissue. It comprises of a few propositions that should be considered in developing a specific semi-quantitative histopathologic scoring system, such as slides examination, lesion parameters and scoring categories (Gibson-Corley *et al.*, 2013; Meyerholz & Beck, 2018). During the slide examination, the observer should carefully inspect, calibrate, determine and identify the slide within and between groups of samples (Alexandra, 2020). For example, a lesion that was observed in all groups of the sample was considered as a “background” lesion and the scoring of the “background” lesion will create a room for further analysis (Shackelford *et al.*, 2002).

On the other hand, the lesion parameter that is required for lesion evaluation in tissue is critical in the histopathology assessment (Gibson-Corley *et al.*, 2013). Some of the lesion parameters can be assessed in all tissues but some are not, therefore, the lesion parameters for each tissue or organs are specific and should be found from literature search to enhance the quality of histopathological results (Gibson-Corley *et al.*, 2013; Qureshi *et al.*, 2012). For instance, Crissman *et al.* (2004) suggested that the use of systematize diagnostic parameter such as Standardized System of Nomenclature and Diagnostic Criteria (SSNDC) Guide is effective in assessing and evaluating the tissues for

toxicologic pathology. Different diagnostic parameters that can be assessed in different organs for toxicologic pathology are stated in table 2.1.

For histopathology scoring categories, a lesion severity scoring system should be developed to aim for better severity classification on condition that the incidence of the tissue alteration is based upon the treatment given (Gibson-Corley *et al.*, 2013). Additionally, the scoring system for toxicologic lesion that shows continuous severity of the lesion should be consistent, definable, reproducible and meaningful (Crissman *et al.*, 2004; Meyerholz & Beck, 2018). Furthermore, animal model is one of the issues that will affect the result of the scoring system. For example, the number of sample used and the part of tissue harvested is crucial in determining the accuracy of true lesion in histopathological scoring (Crissman *et al.*, 2004).

**Table 2.1: Diagnosis Parameter for different organs in Toxicologic Pathology.**

Organs	Diagnostic Parameters	References
Liver	<ul style="list-style-type: none"> <li>- Hepatocellular lesion (Focal lesion, Changes of inflammatory cells, Regenerative hyperplasia, Hepatocellular carcinoma, and adenoma)</li> <li>- Intrahepatic lesion (Bile duct hyperplasia, Formation of biliary cysts)</li> <li>- Miscellaneous lesion (cystic degeneration, focal fatty changes)</li> </ul>	<p>Society of Toxicologic Pathology (2021); Gibson-Corley <i>et al.</i> (2013); Aldahmash and El-Naga (2016)</p>
Kidney	<ul style="list-style-type: none"> <li>- Cell growth disturbance (glomerular and tubule atrophy, tubule hypertrophy and tubule regeneration)</li> <li>- Degeneration changes (Vacuolation, Pigmentation, Tubule dilation and Present of tubular cast)</li> <li>- Cell death (Single cell death and Necrosis)</li> <li>- Changes of inflammatory cells (Interstitial nephritis and Fibrosis)</li> <li>- Vascular changes (Thrombosis)</li> </ul>	<p>Society of Toxicologic Pathology (2021); Brzoska <i>et al.</i> (2003)</p>
Heart	<ul style="list-style-type: none"> <li>- Heart (Fatty infiltration, Fatty changes, Thrombosis, Inflammation of pericardium, epicardium, myocardium and endocardium)</li> <li>- Blood vasculature (Medial degeneration, Arterial and capillary thrombosis, Atherosclerosis)</li> </ul>	<p>Society of Toxicologic Pathology (2021)</p>
Spleen	<ul style="list-style-type: none"> <li>- Necrosis (Lymphoid)</li> <li>- Thrombosis</li> <li>- Neutrophil influx</li> <li>- Red pulp expansion</li> </ul>	<p>Nagagi <i>et al.</i> (2017); Aldahmash and El-Naga (2016); Gibson-Corley <i>et al.</i> (2013)</p>

Stomach	<ul style="list-style-type: none"> <li>- Non-glandular stomach (Hyperplasia, Squamous cell papilloma, Squamous cell carcinoma)</li> <li>- Glandular stomach (Ulceration, Parietal cell necrosis, Focal hyperplasia, Adenocarcinoma, Adenoma)</li> </ul>	Society of Toxicologic Pathology (2021)
Adrenal glands	<ul style="list-style-type: none"> <li>- Focal cortical hyperplasia</li> <li>- Cortical carcinoma and adenoma</li> <li>- Focal medullary hyperplasia</li> <li>- Diffuse medullary hyperplasia</li> </ul>	Society of Toxicologic Pathology (2021)

### 2.1.3 Semiquantitative assessment

Semiquantitative scoring system is a system that is widely used in determining the different of group-specific data. There are several approaches used to grade the tissue changes, such as normal, mild, moderate, and severe (Thoolen *et al.*, 2010; Meyerholz and Beck, 2018). These approaches are important in characterizing the histopathological changes into each category and minimize the error in classifying the result into each category (Gibson-Corley *et al.*, 2013). Moreover, Matthews (2017) proposed 4 different scales of scoring measurement which are nominal, ordinal, interval and ratio based on Steven's typology on the level of measurement. Firstly, the nominal measurement is used when the measurement is unlinked with the level or severity, for examples, gender and favourite colour. Secondly, the ordinal measurement (eg: 0, 1, 2, 3 and 4) will be used when there is rank ordering like disease severity or progression. Each of the scoring represents different frequency of tissue involvement, for instance, "0" is none, "1" is 1-25%, "2" is more than 26-50% and "3" is 51-75% and "4" is 76-100% (Meyerholz & Beck, 2018). Thirdly, the interval measurement is based on a scale between two attributes, and it also has the same numerical distance (Trochim, 2020). For example, the temperature difference between 10-20 and 90-100 is the same. Lastly, the ratio measurement is an equal interval scale with a true zero value which indicates the absence of a characteristic such as the weight and height (Lee, 2016).

On the other hand, statistical data analysis on the scoring is the key element in research-based studies (Gibson-Corley *et al.*, 2013). A statistical analysis software is usually used to analyse the data and generate a comprehensible graph (Mann *et al.*, 2012). Besides, selecting an applicable and right statistical test in running the statistical analysis is crucial in every experimental data set. For instance, the used of non-parametric test in comparing two groups of data or analyse the variance in comparing multiple groups (Shott, 2011; Meyerholz & Beck, 2018). Moreover, the statistical test is important to meet the “assumption” of the selected test and this “assumption” is based on the specific test that is being used in the analysis. For example, the “assumptions” are the normal distribution of data (normality), same variance from different groups of data (homogeneity of variance), linear relationships between data (linearity) and independence of data (Shott, 2011; Zaiontz, 2014).

## 2.2 Rheumatoid Arthritis

Arthritis is a joint inflammation that describes the pain, swelling and tenderness of the joint or the tissues around the joint. There are a few common types of arthritis including rheumatoid arthritis, osteoarthritis, psoriatic arthritis and gout. The type of arthritis can be classified based on the symptoms of the arthritis (Centers for Disease Control and Prevention, 2020).

Rheumatoid arthritis (RA) is a progressive autoimmune and inflammatory disease in which the lining of the joint is attacked by the immune system and causing inflammation. The manifestations of RA are primarily in the joint that is lined with synovial membrane (Guo *et al.*, 2018). For instance, symmetric pain and synovial inflammation are commonly found in the hands and feet of a RA patient (Smith, 2020).

Besides, RA was reported to cause effect on other parts of body, such as skeleton, skin, mouth, eyes, lungs and heart (Jamie, 2018). For example, the chronic inflammation from RA will damage the cartilage of the joint thus leads to the loss of bone density, bone thinning and fractures. In addition, inflammation from RA will damage the tear and moisture producing glands and cause dryness of the mouth and eyes (Arthritic Foundation, 2021). Moreover, the inflammation also caused the development of painless rheumatoid nodules under the skin, especially the elbow and fingers (Kristeen, 2019). Furthermore,

the long term effect from the progression of rheumatoid arthritis will reflect on the patient's body. For instance, the symptoms of the RA getting more frequent and severe. RA patient would experience an increase of pain and swell on the joint or even a formation of symptoms on the new area of the body (Jamie, 2018).

According to Aletaha & Smolen (2018), treatment of RA is aimed to achieve the remission of the disease by reducing the disease activity. There are a few conventional drugs found in the market that reported to reduce the symptoms and prevent the progression of RA. For example, NSAIDs, disease modifying antirheumatic drugs (DMARD) and glucocorticoids (Bullock *et al.*, 2018). However, the continuous consumption of these conventional drugs may lead to serious side effects on the liver, kidney, heart and lungs (Arthritic Foundation, 2021). Hence, a safer alternate treatment for rheumatoid arthritis was developed by replacing the conventional drugs with herbal remedies (Padher & Bhalekar, 2018).

### 2.2.1 Adverse effect of Rheumatoid Arthritis Medication

Latest treatment for rheumatoid arthritis aimed to reduce pain, swelling and slow the RA progression (Howard, 2021). Based on Crofford (2013), non-steroidal anti-inflammatory drugs (NSAIDs) are the first line treatment in RA. Interestingly, different classes of drugs possess different properties to target specific mechanisms in treating RA. Hence, the combination of few conventional drugs including NSAIDs, disease modifying antirheumatic drugs (DMARD), corticosteroids and other biological agents are usually used to maximize the effects of treatment (Chopra *et al.*, 2008). The conventional drugs are reported to be widely used in RA treatment; however, it would bring negative effects to the patients. For example, the use of NSAIDs is able to cause nephrotoxicity, hepatotoxicity and cardiac toxicity. Besides, the use of DMARDs and glucocorticoids was proved to cause lung, liver and stomach lesion, microorganisms' infections, and bone diseases (Crofford, 2013; Kamal & Baldi, 2015; Cronstein, 2013; Conway & Carey, 2017; Weinblatt *et al.*, 2003; Benjamin *et al.*, 2020; Joseph *et al.*, 2016; Youssef *et al.*, 2016). **Table 2.2** below shows the list of therapeutic drugs and the adverse effects that are used in RA treatment.

**Table 2.2: Adverse effect of conventional therapy in Rheumatoid Arthritis**

Class of therapeutic drugs	Mechanism of action	Toxic effects	References
NSAIDs	COX and PG inhibitor	Renal, hepatic and cardiovascular toxicity	Crofford (2013); Kamal & Baldi (2015)
DMARDs	Chemical: proinflammatory cytokine inhibitor, MMPs modulator, Th17 cell differentiation suppressor, immunosuppressant	Chemical: Liver fibrosis, bone marrow suppression, tuberculosis and gastrointestinal distress	Benjamin <i>et al.</i> (2020); Gerards <i>et al.</i> (2003); Tchetverikov <i>et al.</i> (2008); Haskó & Cronstein (2013); Conway & Carey (2017); Weinblatt <i>et al.</i> (2003)
	Biological: Tumor necrosis factor (TNF)- $\alpha$ and IL-6 receptor inhibitor and B-cell factor inhibitor	Biological: Bacterial, fungal and viral infection, tuberculosis and hepatitis	
Glucocorticoids	Macrophage accumulation inhibitor and anti-inflammation	Osteoporosis, peptic ulcer and increased rate of infections	Joseph <i>et al.</i> (2016); Youssef <i>et al.</i> (2016); Spies <i>et al.</i> (2010)

## 2.3 *Ardisia crispa*

### 2.3.1 Description of *Ardisia crispa*

*Ardisia crispa* (Thunb.) A.DC. is a medicinal plant from Primulaceae Batsch ex Borkh. Family and is widely distributed in east Asia including Malaysia, Indonesia, Japan, China and India (Plants of the World online, 2017; Hamsin *et al.*, 2013). This plant is given a variety of English names such as Coral Berry, Christmas Berry or Hen's eyes. This plant is known by different names according to their local languages. In Malaysia, it is known as village ardisia or "mata itik", while in China it is known as "Bai Liang Jin" (Nordin *et al.*, 2017). Interestingly, a long chain of alkyl-1,4-benzoquinones is a major compound that can be found in the roots of *Ardisia crispa* (Thunb.) A.DC which possesses pharmacological properties. For instance, 2-methoxy-6-tridecyl-1,4-benzoquinone which isolated from the root of *Ardisia crispa* (Thunb.) A.DC. has been shown to exhibit antimetastatic and antitumor effect (Kang *et al.*, 2001). Moreover, 2-methoxy-6-undecyl-1,4-benzoquinone that can be isolated from *Ardisia crispa* roots exhibited antiangiogenic and antiarthritic effects in both in vitro and in vivo models (Blin *et al.*, 2021a; Blin *et al.*, 2021b).

### 2.3.2 Morphology of *Ardisia crispa*

*Ardisia crispa* (Thunb.) A.DC. is an evergreen shrub where the plants remain green in all years. *Ardisia crispa* can grow up to 1.2 meters and usually in a single stem. The leaves of *A. crispa* (Thunb.) A.DC. are simple, dark green in color and able to reach 15 cm long. Besides, it has petiole and lanceolate leaves with punctate and revolute margins. The calyx lobe is ovule in shape and its flowers grow up to 8mm in diameter with acute corolla-lobes. The filament of the stamen is closely obsolete and the anthers mucronate (Plants of the World online, 2017; Halliday, 1984). The flower of *Ardisia crispa* is fragrant, white or pinkish red in color and grows in the form of a cluster. The fruit of *Ardisia crispa* is bright, red and small berries and the seeds germinate well under the dense canopy (Plants Rescue, 2019).



**Figure 2.1: Hand drawn morphology of *Ardisia crispa*.**

(Temperate Plants Database, 2021)



**Figure 2.2: The leaves and fruits of *Ardisia Crispa*.**

(Plants for a Future, 2010-2021)

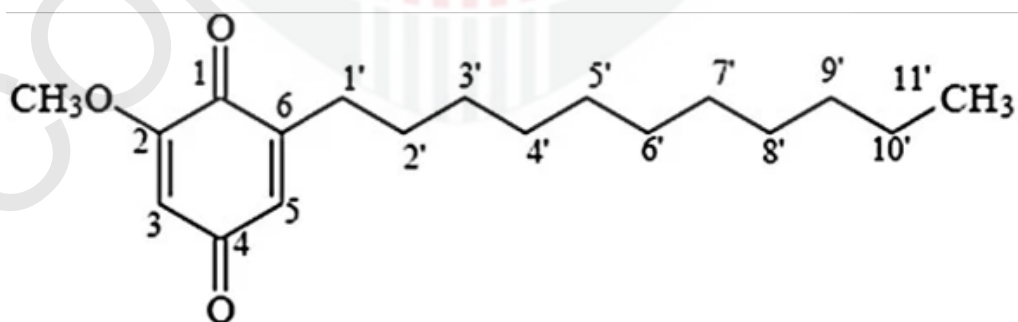
### 2.3.3 Ethnobotanical uses

*Ardisia crispa* (AC) has been traditionally used by the locals of east Asia. The roots and the leaves have been claimed by the traditional practitioners to possess numerous medicinal properties for treating human ailment and it is able to be used in both internal and external treatments. In Malaysia, the juice blended from the leaves was used to treat scurvy by the locals. Besides, the roots of *Ardisia crispa* were boiled to treat sore throat, angina as well as Rheumatic diseases (Kobayashi & De Mejía, 2005).

Burkill (1966) claimed that the roots of *Ardisia crispa* were processed into Chinese herbal decoction and marketed as “sin-lo-san” to treat sprains and fractures. In addition, the blended roots juice was reported to show effect in treating cough, diarrhea and fever (Muhammad & Mustafa, 1994). In Thailand, *Ardisia crispa* is a traditional herb that is mixed with other traditional herbs to promote and stimulate the menstrual blood flow thus relieving menstrual pain (Chaweewan *et al.*, 1987). In addition, the roots of *Ardisia crispa* are commonly used by the locals in China to treat fever and hypersalivation (Christophe, 2002).

## 2.4 Quinone rich fraction of *Ardisia crispa* (QRF)

Quinone rich fraction of *Ardisia crispa* (QRF) is isolated from hexane fraction of *Ardisia crispa* roots ethanolic extract (ACRH) via silica gel column chromatography. An antiangiogenesis substance, termed as AC-2 compounds was isolated from the roots of *Ardisia crispa* and identified as 2-methoxy-6-undecyl-1,4-benzoquinone (Roslida, 2004). This benzoquinone was classified under quinone class (National Center for Biotechnology Information, 2021). Quinone is an aromatic compound that consists of two double bonds, one aromatic ring, long saturated and unsaturated side chain, and with the presence of hydroxyl and methoxy groups (Michalík *et al.*, 2019). Interestingly, quinone is a cytotoxic agent and its toxicity can be caused by the substituent effect of the chemical structure (Monks & Jones, 2002). These characteristics of the quinone is significant in determining the potential hazardous and safety of QRF in long term consumption.



**Figure 2.3: Chemical structure of 2-methoxy-6-undecyl-1,4-benzoquinone**

(Hamsin *et al.*, 2013)

## **2.5 Toxic effect of hexane extract and rich fraction of *Ardisia crispa* roots**

According to Blin *et al.* (2021a) benzoquinone isolated from quinone rich fraction of *Ardisia crispa* (QRF) exhibited an antiarthritic effect, *in vitro*. Interestingly, this benzoquinone belongs to quinone class which is a cytotoxic agent that increases the potential toxicity in cells and animal model (National Center for Biotechnology Information, 2021).

Various studies using hexane extract (ACRH) and its rich fraction of *Ardisia crispa* shows different therapeutic effects like antiangiogenesis and anti-tumor promotion. Hamsin *et al.* (2013) reported that the administration of ACRH and QRF at 10, 30 and 100 mg/kg on male ICR mice for 5 days did not show any toxic effect in anti-angiogenesis study. Besides, a subchronic toxicity study performed by Fifi (2013) demonstrated that the healthy ICR mice showed a mild toxic effect in hematology analysis after administration of ACRH at 300 mg/kg after 28 days. Moreover, a study by Yeong *et al.* (2015) reported that 100 mg/kg of TRF isolated from ACRH showed promotion of the tumour growth in male ICR mice at 20 weeks of sample exposure in antitumor promoting study. The summarized toxic effect of ACRH, QRF and TQF are shown in the **table 2.3** as below.

Based on these studies, the toxic effect of the *Ardisia crispa* samples was believed to be attributed by the dosages, time exposure, route of administration and the extraction protocol with different solvent, i.e. hexane, methanol or aqueous extract.

**Table 2.3: The toxic effect of hexane extract and rich fraction of *Ardisia crispa*.**

Studies	Models	Samples	Dosages (mg/kg)	Exposure to sample	Toxic effect	References
Anti-angiogenesis	Male ICR mice	ACRH, QRF	10, 30 and 100	5 days	Absent	Hamsin <i>et al.</i> (2013)
Subchronic toxicity study on healthy mice	ICR mice	ACRH	10, 30, 100 and 300	28 days	Mild toxic at 300mg/kg (Changes in haematology analysis)	Fifi (2013)
Antitumor promoting	Male ICR mice	TRF	10, 30 and 100	20 weeks	Promote tumour growth at 100mg/kg	Yeong (2015)

## CHAPTER 3

### METHODOLOGY

#### 3.1 Animal samples

The male Sprague Dawley rats were induced with type II collagen (on day 0) and treated with QRF for 13 days (from day 14 to 26). The rats were divided into 5 groups, including vehicle control (5% of CMC), arthritic control (CIA induction) and three QRF- treated groups (3, 10, 30mg/kg). CIA was defined as collagen-induced arthritis where the animal model was induced with autoimmune arthritis by immunization with type II collagen (Brand & Rosloniec, 2007). These animal model's preparation was done by Joan Blin, a PhD student of Prof. Roslida. The selected organ i.e liver, spleen and kidney were obtained from the dissection and were fixed in a 10% buffered formalin solution after his study. **Table 3.1** below showed the list of treatment that was administered to the animal models.

**Table 3.1: List of treatments that given to the animal models.**

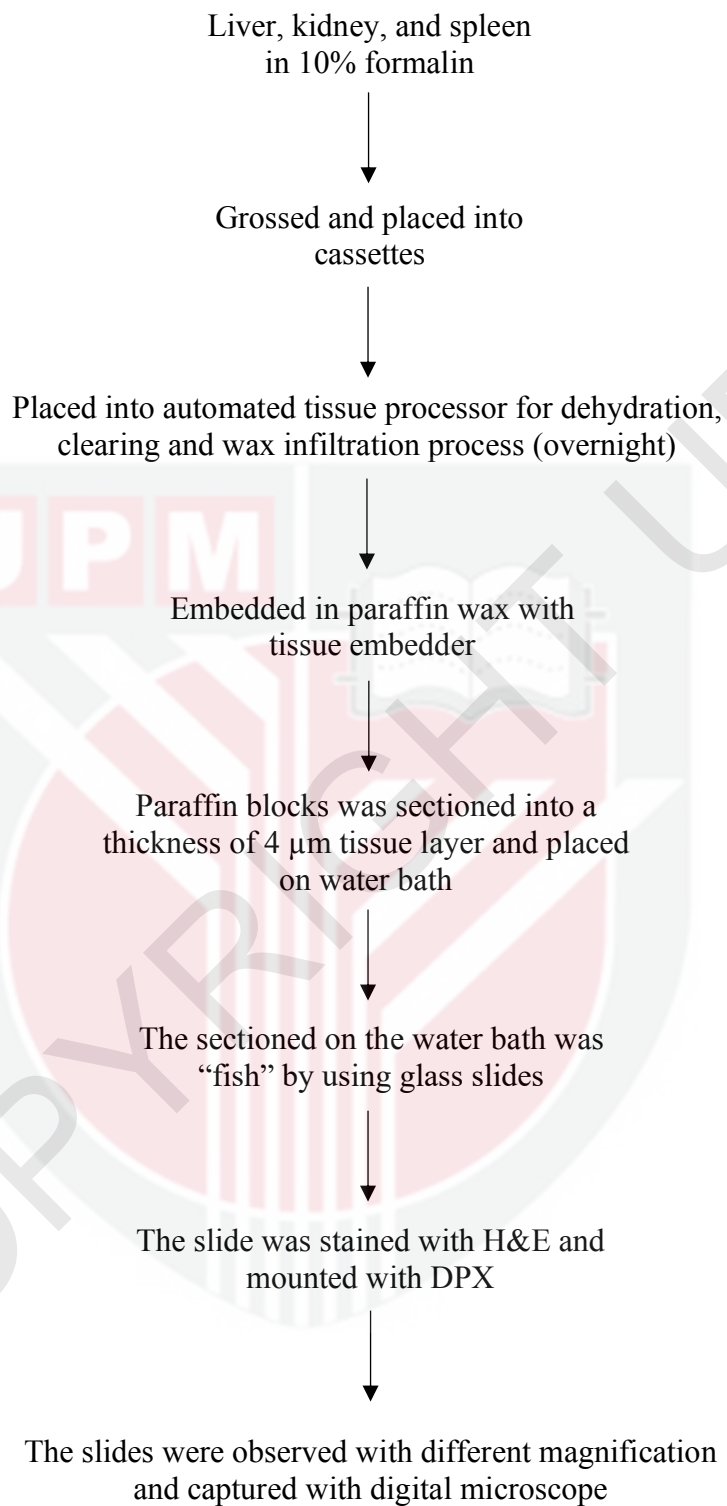
<b>Groups</b>	<b>Treatment</b>
<b>A</b>	Vehicle control (5% of CMC)
<b>B</b>	Arthritic control (CIA induction)
<b>C</b>	3mg/kg QRF
<b>D</b>	10 mg/kg QRF
<b>E</b>	30 mg/kg QRF

### **3.2 Histopathological examination**

All of the animal models that used in this study were approved by Institutional Animal Care and Use Committee (ACUC), UPM with reference number UPM/IACUC/AUP-R092/2015, and the histopathological examination was conducted in the Histopathology laboratory, Faculty of Medicine and Health Sciences, UPM. Firstly, all the organs were grossed and placed in the cassette. The tissues were then processed for overnight in an automatic tissue processor (Leica TP1020, Germany). In the tissue processor, the tissues underwent a few processes such as dehydration, clearing and wax infiltration. During the dehydration process, the tissues were immersed in a series of alcohol from a lower to higher concentration until water-free alcohol is obtained. This process is to remove water prior to the wax infiltration process since the melted wax is immiscible to water. Then, a “clearing reagent”, xylene was used to clear the excess fat from the tissue. In addition, xylene was used to displace the alcohol in the tissue because of the higher miscibility than alcohol and thus to ease the wax infiltration process. In wax infiltration process, the tissue was infiltrated with histological wax which allowed it to be sectioned into layers.

After that, the processed tissues that infiltrated with wax were removed from the tissue processor and embedded in a paraffin wax and left cool using embedding machine (Leica EG1160, Germany). Paraffin block was then sectioned into a thickness of 4  $\mu\text{m}$  using a sectioning rotatory microtome (Leica

RM2235, Germany). The sectioned tissue layer was immediately placed in 45° water bath (Leica HI1210, Germany) for “fishing” process with the used of glass slides. All the slides were then stained with conventional Hematoxylin & Eosin (H&E) stains using an automated slide staining machine (Leica ST5010, Germany) in order to view the clear microstructure of the tissue. The stained slides were then continued with the mounting process using Dibutylphthalate Polystyrene Xylene (DPX) with a cover slip. The slides were then examined under microscope with the magnification of 40×, 100× and 400×. The digital micrographs of the slide were taken.



**Figure 3.1: Flowchart of histology tissue processing.**

### 3.3 Histopathological scoring

The histopathological features for each organ were evaluated for any histopathological changes. In the liver, presence of inflammation, fibrosis, necrosis were examined while inflammation, necrosis and hydropic degeneration were assessed in the kidney. Similarly in the spleen, inflammation, necrosis and a change in splenic architecture such as lymphoid necrosis and red pulp expansion were determined. **Table 3.2** below showed a summary of the histological features assessed in the organs. A semiquantitative scale to determine the histopathological grading in liver, spleen and kidney: normal (0) = 0, mild (1) = 1%-30%, moderate (2) = 31%-70% and severe (3) = >70% of the changes seen in tissue of affected area were used (Asyura *et al.*, 2016).

**Table 3.2: Diagnostic features for selected organs.**

<b>Organs</b>	<b>Diagnostic features</b>
Liver	Inflammation, Necrosis and Fibrosis
Kidney	Inflammation, Necrosis and Hydropic degeneration
Spleen	Inflammation, Necrosis, Lymphoid necrosis and Red pulp expansion

### 3.4 Statistical Analysis

All the data from the groups were expressed as mean  $\pm$  standard error of mean (S.E.M.). IBM SPSS v25 statistical software was used to analyse the differences between groups by using One-way Analysis of Variance (ANOVA) and followed by Tukey's post hoc test for multiple comparisons in different groups. A *p*-value of less than 0.05 was considered statistically significant.

## CHAPTER 4

### RESULTS

#### 4.1 Histopathological findings

The hazardous potential and safety of quinone rich fraction (QRF) of *Ardisia crispa* on rats was evaluated via histopathological assessment. Based on the histopathological evaluation, the Tukey test for the multiple lesion scoring comparison showed non-significant result ( $p > 0.05$ ) in the selected organs (liver, spleen and kidney) of treatment and control groups (**Table 4.1**).

In histopathological evaluation of the liver, the arthritic rats treated with 3mg/kg, 10mg/kg and 30mg/kg of QRF exhibited presence of focal portal inflammation. This mild focal inflammations that observed within the portal tracts was fairly non-specific. Lymphocytes were found at the sites of focal inflammation and interface hepatitis or piecemeal necrosis was absent in treatment and control groups.

Within the kidney of arthritic rats treated with 3mg/kg and 30mg/kg of QRF, mild focal lymphocytic inflammations were observed in the renal interstitium with no tissue damage. Rat models treated with 10mg/kg of QRF

however, showed no histopathological alteration as compared to the vehicle and arthritic control groups.

In histopathological evaluation of the spleen of arthritic rats treated with 3mg/kg, 10mg/kg and 30mg/kg of QRF showed normal white pulp and red pulp architecture similar to the spleen of both vehicle and arthritic control groups that exhibited the normal histological features.

**Table 4.1: Lesion scoring of liver, kidney and spleen from male Sprague Dawley rats in all treatment groups.**

Organs	Mean score of lesion	Groups				
		A	B	C	D	E
Liver	Inflammation	0.40 ± 0.25 <sup>a</sup>	0.20 ± 0.20 <sup>a</sup>	0.40 ± 0.25 <sup>a</sup>	0.60 ± 0.25 <sup>a</sup>	0.40 ± 0.25 <sup>a</sup>
	Necrosis	0 <sup>a</sup>	0 <sup>a</sup>	0 <sup>a</sup>	0 <sup>a</sup>	0 <sup>a</sup>
	Fibrosis	0 <sup>a</sup>	0 <sup>a</sup>	0 <sup>a</sup>	0 <sup>a</sup>	0 <sup>a</sup>
Kidney	Inflammation	0 <sup>a</sup>	0 <sup>a</sup>	0.20 ± 0.20 <sup>a</sup>	0 <sup>a</sup>	0.20 ± 0.20 <sup>a</sup>
	Necrosis	0 <sup>a</sup>	0 <sup>a</sup>	0 <sup>a</sup>	0 <sup>a</sup>	0 <sup>a</sup>
	Hydropic degeneration	0 <sup>a</sup>	0 <sup>a</sup>	0 <sup>a</sup>	0 <sup>a</sup>	0 <sup>a</sup>
Spleen	Inflammation	0	0	0	0	0
	Lymphoid necrosis	0	0	0	0	0
	Red pulp necrosis	0	0	0	0	0
	Red pulp expansion	0	0	0	0	0

All data were expressed as mean ± SEM. Result were analysed by using One-way ANOVA. The superscript letter <sup>a</sup> within a row is indicate non-significance at  $p > 0.05$ .

(Note: A: Vehicle control (5% CMC); B: Arthritic control (CIA induction); C: 3mg/kg of QRF; D:10mg/kg of QRF; E: 30mg/kg of QRF)

## 4.2 Histopathological evaluation

### 4.2.1 Liver

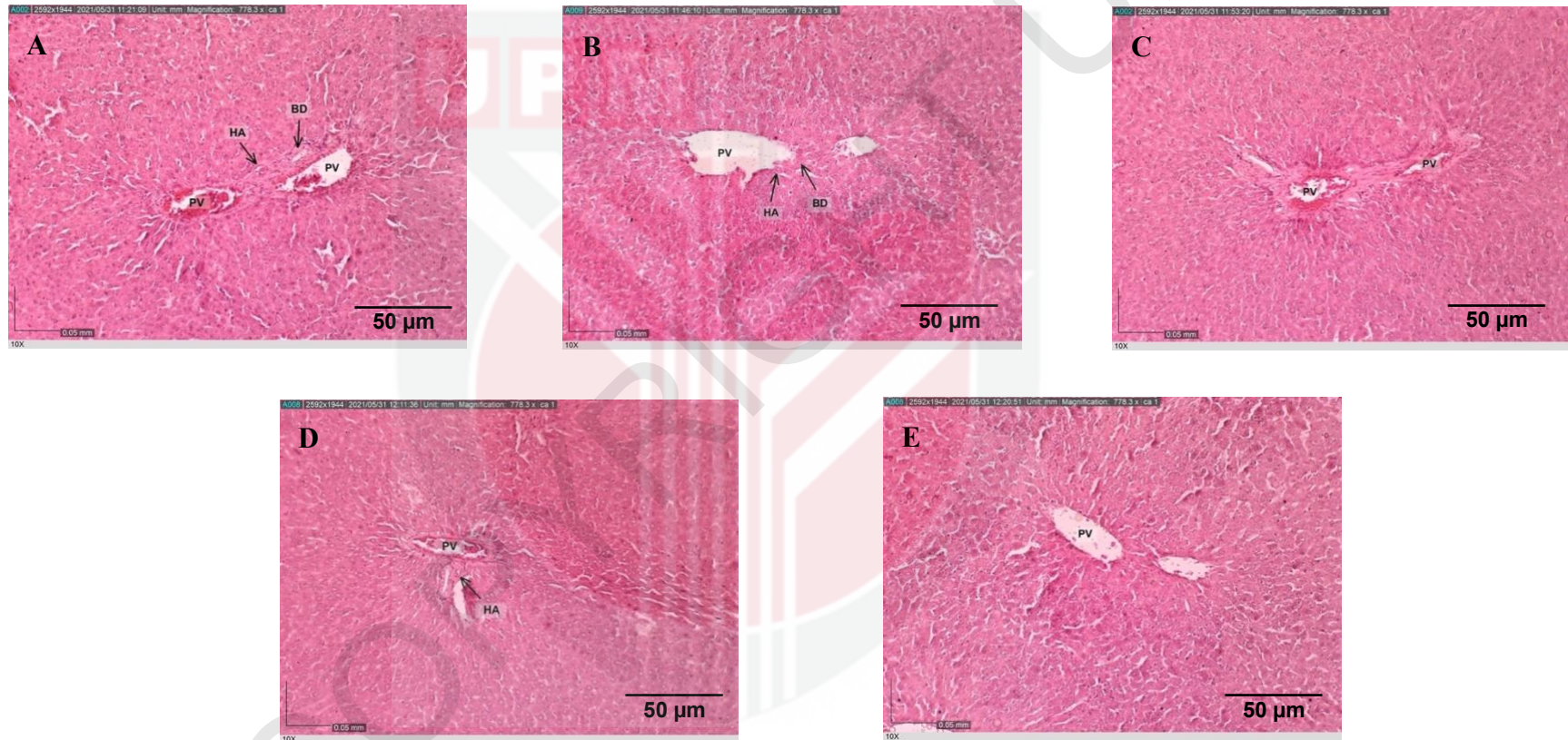
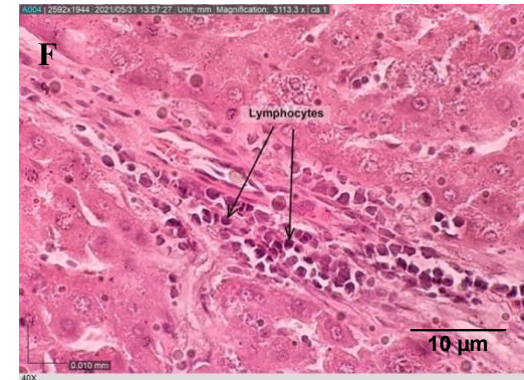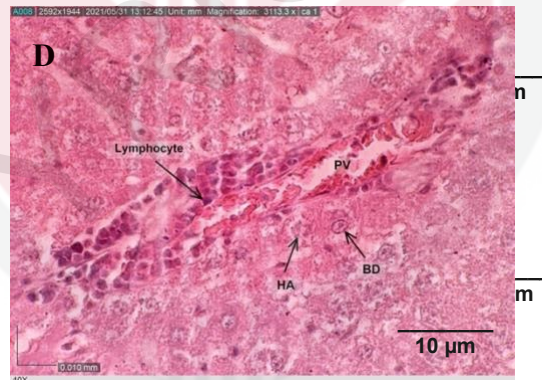
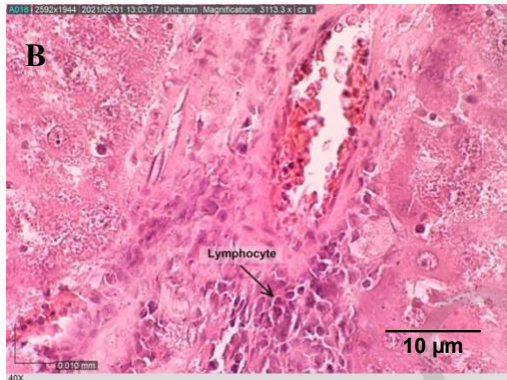
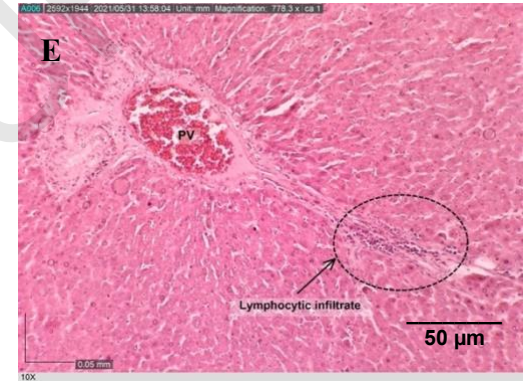
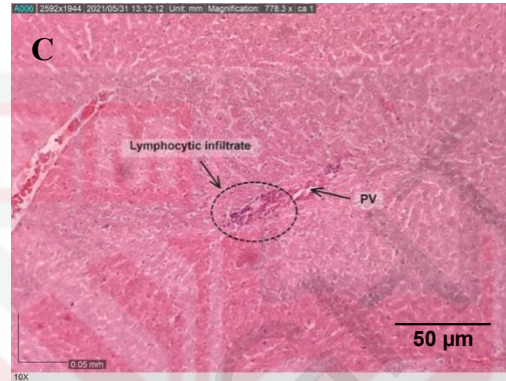
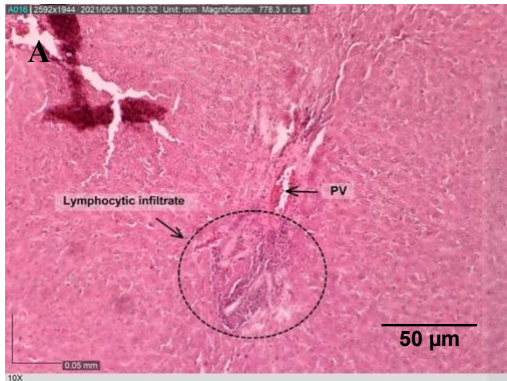


Figure 4.2.1: Photomicrograph of the normal liver sections of rats at the end experiment. (A) vehicle control, (B) arthritic control, (C) 3mg/kg, (D) 10mg/kg and (E) 30mg/kg group. Note that **PV** (Portal venules), **HA** (Hepatic artery) and **BD** (Bile duct). (H&E stain, Magnification: X100)

## 4.2.2 Liver



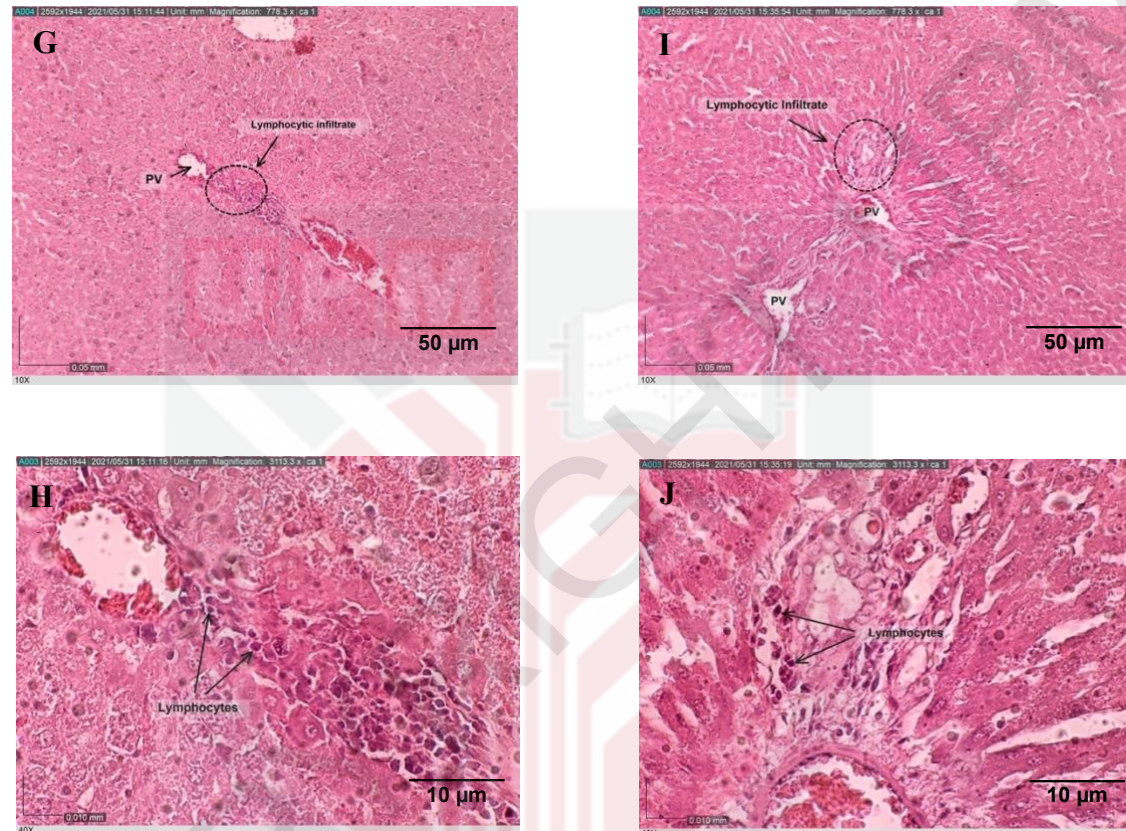


Figure 4.2.2: Photomicrograph of focal inflammation in the liver sections of rats at the end experiment. (A) and (B): focal inflammation with partial involvement of portal tract from vehicle control, (C) and (D): (C) and (D): mild to moderate inflammation within portal tract (lymphocytic) from arthritic control (E) and (F): lymphocytic infiltration in the portal tract from 3mg/kg, (G) and (H): mild inflammation with lymphocytic infiltration from 10mg/kg and (I) and (J): focal mild lymphocytes in the portal tract from 30mg/kg group. Note that **PV** (Portal venules), **HA** (Hepatic artery) and **BD** (Bile duct). (H&E stain; Magnification: X100 (A, C, E, G and I), X400 (B, D, F, H and J))

### 4.2.3 Kidney

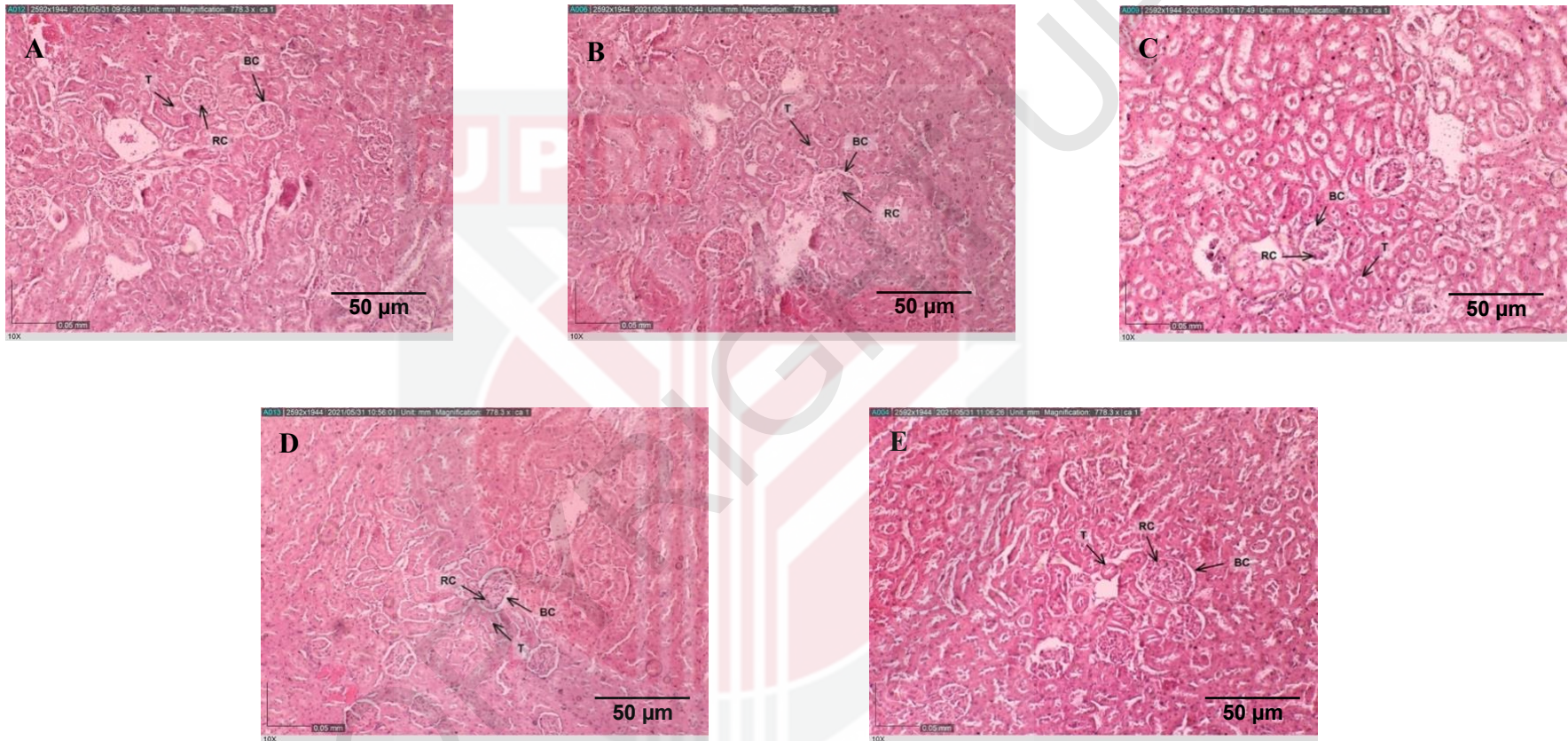


Figure 4.2.3: Photomicrograph of the normal kidney sections of rats at the end experiment. (A) vehicle control, (B) arthritic control, (C) 3mg/kg, (D) 10mg/kg and (E) 30mg/kg group. Note that **BC** (Bowman's space), **RC** (renal corpuscle) and **T** (tubules). (H&E stain, Magnification: X100)

#### 4.2.4 Kidney

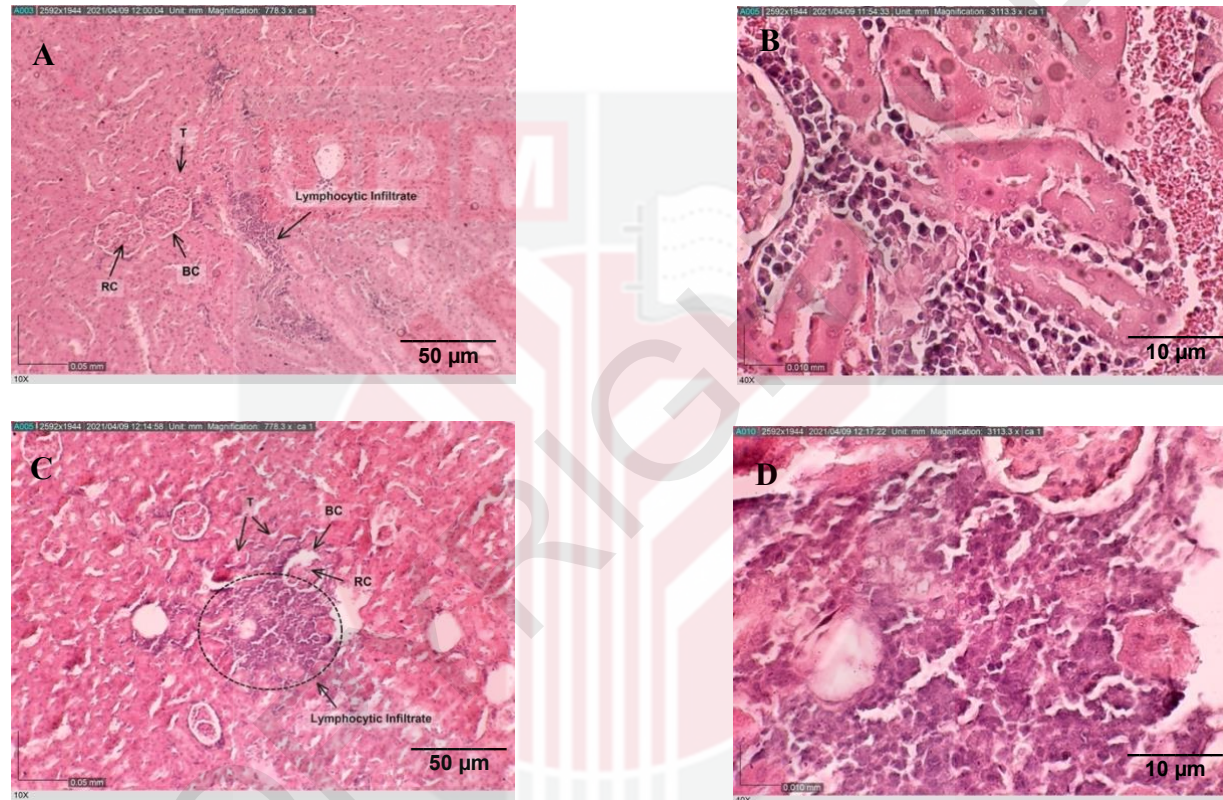


Figure 4.2.4: Photomicrograph of focal inflammation in the renal parenchyma of experimental rats at the end of experiment. Lymphocytes were observed in the renal interstitium in (A) and (B) from 3mg/kg; and (C) and (D) from 30mg/kg treatment group. Note that **BC** (Bowman's space) and **RC** (renal corpuscle), **T** (tubules). (H&E stain; Magnification: X100 (A and C), X400 (B and D))

#### 4.2.5 Spleen

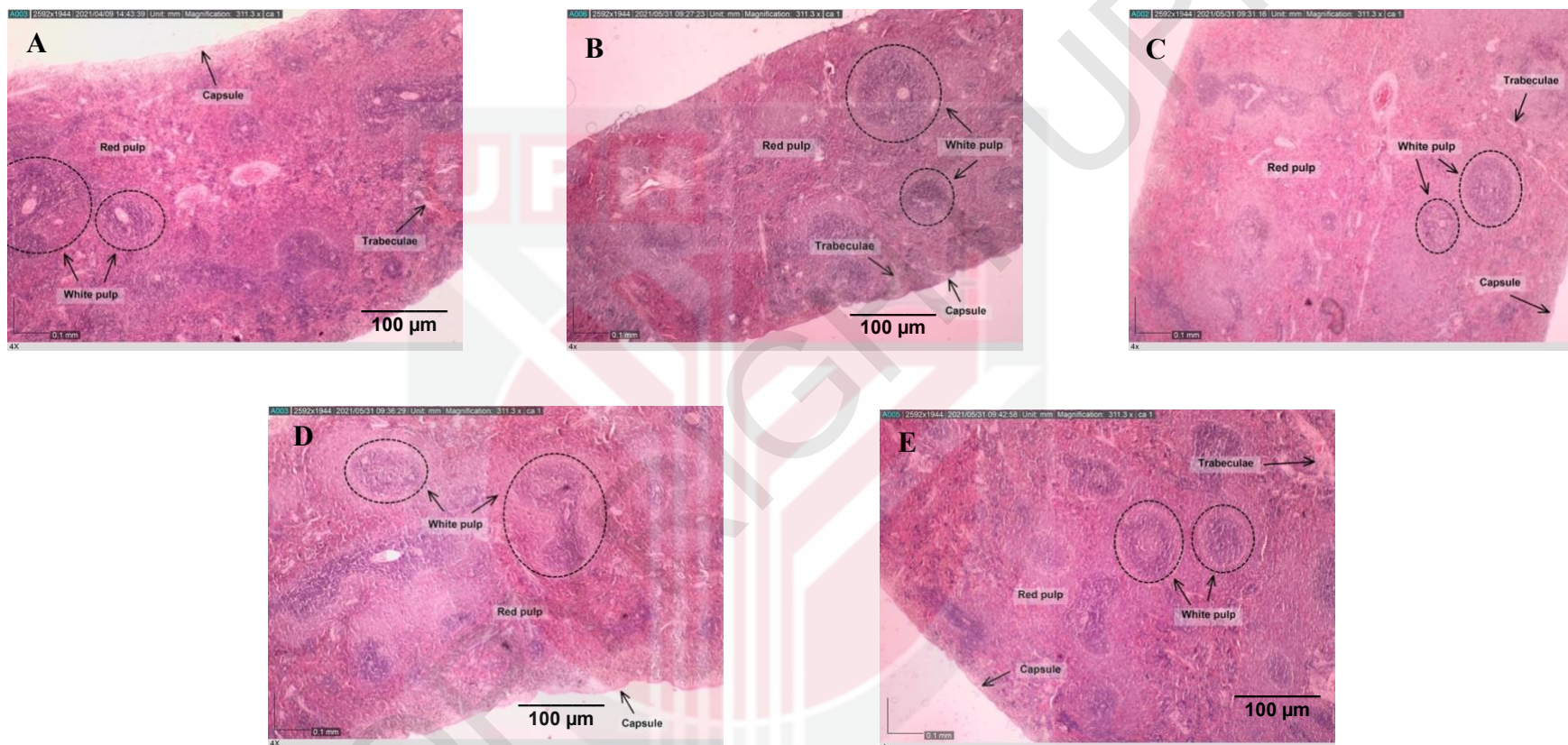


Figure 4.2.5: Photomicrograph of the normal spleen sections of rats at the end experiment. (A) vehicle control, (B) arthritic control, (C) 3mg/kg, (D) 10mg/kg and (E) 30mg/kg group. (H&E stain; Magnification: X40)

## CHAPTER 5

### DISCUSSION

Rheumatoid arthritis is a global public health issue that affected 1% of adults worldwide (Lwin *et al.*, 2020). In the present era, the therapy, and medications for symptoms remission in rheumatoid arthritis has been well established, however, this conventional medication showed liver and cardiovascular manifestations, ophthalmology, skin, renal and splenic impairment in the RA patient after long term of treatment (Turesson *et al.*, 2003; Jamie, 2018). Therefore, alternative treatment for rheumatoid arthritis was developed with the used of herbal remedies such as Traditional Chinese Medicine, Ayurveda and Jamu (Faedah *et al.*, 2015; Padher & Bhalekar, 2018). *Ardisia crispa* (mata itik) is a medicinal plant that is able to exhibit different pharmacological activities and one of them was antiarthritic effect (Hamid *et al.*, 2017; Blin *et al.*, 2021; Blin *et al.*, 2021).

*Ardisia crispa* has been studied for different purposes such as antioxidant (Jindal & Mohammad, 2012), anti-inflammation and antihyperalgesic (Lau *et al.*, 2009; Roslida & Kim, 2008), antimetastatic and antitumor (Kang *et al.*, 2001; Yeong *et al.*, 2013), antiarthritic (Hamid *et al.*, 2017), anti-angiogenesis (Hamsin *et al.*, 2013; Jun *et al.*, 2019) and so on. Interestingly, 2-methoxy-6-undecyl-1,4-benzoquinone from quinone class can

be found from the roots of *Ardisia crispa* (Roslida, 2004; National Center for Biotechnology Information, 2021). However, the toxic effect of *Ardisia crispa* was believed to be attributed by the dosages, time exposure, route of administration and the extraction protocol with different solvent (Hamsin *et al.*, 2013; Fifi, 2013). A previous study proposed that quinone rich fraction of *Ardisia crispa* (QRF) was shown to exert a therapeutic antiarthritic effect in male Sprague Dawley rats for 28 days at various dosages (3, 10 and 30mg/kg) (Blin *et al.*, 2021). Thus, we have conducted a study to assess the subchronic toxicity effect on male Sprague Dawley rats in 13 days of ACRH treatment. In this study, we determined the potential hazardous and safety of QRF by observing the histopathological alteration of selected organs of the rats.

Liver, kidney, and spleen were used in assessing the histopathological alteration of quinone rich fraction of *Ardisia crispa* (QRF). This is because these selected organs were suggested to be used for histopathology assessment in toxicology studies (Seller *et al.*, 2007). According to Nigatu *et al.* (2017), any toxic agent that enter the body system will affect and disturb the organs' physiological function, mainly in liver, kidney, and spleen. Liver is the most common organ that is affected by toxicity in the view of fact that it is the major site to breakdown the metabolites and drug biotransformation (Soldatow *et al.*, 2013; LibreTexts, 2021). In addition, kidneys are responsible in blood filtration, removing wastes and extra fluid from our body system, including toxin. (LibreTexts, 2021; National Kidney Foundation, 2021). Thus, any toxic effect will disrupt the histopathological appearance and cause histopathological

alteration in the tissue (Nigatu *et al.*, 2017). Other than that, spleen is functioned to remove the microorganism, damaged and abnormal cells while also involves in our body immune system which is sensitive to toxic agents (De Jong & Van Loveren, 2007). For instance, the present of toxic agents will accumulate in the spleen will disrupt the immune defense and induce inflammatory cytokines (Sizova *et al.*, 2011; Sang *et al.*, 2012). Therefore, the selection of liver, kidney, and spleen is able to provide an insight to the histopathological changes that caused by the potential hazardous of QRF administration.

In the present study, the histopathological examination showed that the daily administration of *Ardisia crispa* at dosages of 3mg/kg, 10mg/kg and 30mg/kg for 13 days induced focal inflammation in the liver of all treatment and control groups averagely. Besides, focal inflammations were observed in the kidney of low dosage (3mg/kg) and high dose (30mg/kg) of treatment groups. Focal inflammation is an inflammatory process where the polymorphonuclear neutrophils or lymphocytes are randomly accumulated on the tissue (NCIthesaurus, 2021). From the histological examination, the lesion scoring for the selected organs from different treatment groups reported no significant difference ( $P > 0.05$ ) from the control.

In the liver sectioned tissue, **figure 4.2.2** showed the focal portal inflammation with lymphocytic infiltration in the liver of all QRF-treated groups and control groups. Lymphocytes was distributed within the portal tract with the

absence of other inflammatory processes such as interface hepatitis or piecemeal necrosis and fibrosis. Histologically, the presence of lymphocytic portal tract infiltration in liver of QRF treatment groups can also be found in the vehicle and arthritic control groups,, which thus led to insignificant comparison between groups. In addition, Robert (2014) proposed that the presence of one or two focal inflammation that observed in both control and treatment groups of liver is considered as background lesion and graded under the minimal scoring.

According to Robert (2014), focal inflammation in liver that involved infiltrating cell, especially lymphocytes, is a spontaneous activity which can occur in the rodents' tissue in toxicity studies. On the other hand, focal inflammation may be associated with the infectious agent or organism that unable to eliminate from the tissue. For example, any infection agent or organism that enter the rat models during the oral administration together with the treatment is believed to be the cause of focal inflammation (Robert, 2014; Pahwa *et al.*, 2020). In addition, Ferrell (2000) and Robert (2014) claimed that the cause of a focal inflammation in the liver is always unknown or different to identify. However, the microscopic features of the tissue would help in differentiating the causes of the injury process when apply with the settings of the study (Ferrell, 2000). In this study, it is not significant to indicate that the focal inflammation within the portal tract is caused by the QRF administration since the result showed is fairly non-specific.

In the kidney sectioned tissue, mild focal lymphocytic inflammation was also observed in the renal parenchyma. Based on **figure 4.2.4**, small number of lymphocytes were only observed in the renal interstitium of 3mg/kg and 30mg/kg treatment groups. Lymphocytic infiltration is diagnosed due to the low quantity of inflammatory cell and not associated with any other sign of inflammation such as tissue damage, oedema and haemorrhage (John & Amy, 2014). Rats treated with 10mg/kg showed a normal histological features as control group (**figure 4.2.3**). Renal interstitium is the spaces between the tubules, glomerulus and capillaries, and it has a function in fluid and electrolyte exchange as well as insulation in the kidney when any compound passing through it (Lemley and Kriz, 1991; Zeisberg and Kalluri, 2015). According to Frazier *et al.* (2012), the inflammatory cell infiltration within the renal interstitium is a regular and spontaneous activity in rats and mice, and carry no toxicity. In addition, John and Amy (2014) claimed that lymphocytic infiltration can be frequently observed in the rodents' kidney and these infiltration is commonly represented as the background feature. Therefore, the inflammatory cells observed at focal lymphocytic inflammation in renal interstitium of rats treated with 3mg/kg and 30mg/kg QRF are assumed as the inconsistent background lesion which is not associated with QRF treatment.

In the spleen sectioned tissue, there was no histopathologic alteration was observed in microscopic evaluation in control and treated rat models. Based

on **figure 4.2.5**, all the structure of the spleen remained normal. Thus, the histopathology results successfully proved that QRF administration up to a high dose of 30mg/kg appear to induce no histopathological changes in the spleen.

Nevertheless, artifacts can be observed in the sectioned tissue. Artifacts can be defined as the tissue alteration on the tissue slides that caused by external factor such as the inappropriate sectioning and mounting technique during tissue processing (Seoane *et al.*, 2004). In this study, tearing, folding, wrinkles and air bubbles in tissue sectioned was noticed. Taqi *et al.* (2018) reported that the tearing, folding and wrinkles of the tissue sectioned are related to the microtomy technique. For instance, the tearing of tissue sectioned was believed to be caused by a dull blade or nick on the blade, while the folding and wrinkles was caused by the uneven stretch of tissue section during the sectioning process. Moreover, the air bubbles on the tissue sectioned was related to the mounting technique when the cover slip was placed on the slide that have insufficient mounting medium, and so the air was trapped between the slide and cover slip (Chatterjee *et al.*, 2014; Taqi *et al.*, 2018).

In summary, the histopathological results on selected organs ie liver, kidney and spleen showed no significant difference in treatment and control group for 13 days of daily administration of quinone rich fraction (QRF) of *Ardisia crispa*. Therefore, the histopathological examination proved that the

administration of QRF up to 30mg/kg induced no hepatic, renal, and splenic toxicity. This result was supported by Dey *et al.*, 2014 where they reported that the oral administration of ethanol extract of *Ardisia elliptica* fruits (EFA) up to a higher dose of 3,200mg/kg exhibited antioxidant and antidiarrheal activities without any toxic reaction in Wistar rat models. In addition, alkylbenzoquinone derivatives that can be extracted from *Ardisia seiboldii* demonstrated cytotoxic and anti-inflammatory activities without inducing toxicity to the RAW 264.7 cells (Shahinozzaman *et al.*, 2019).

## CHAPTER 6

### CONCLUSION AND FUTURE RECOMMENDATION

#### 6.1 Conclusion

Quinone rich fraction of *Ardisia crispa* (QRF) have previously shown to exert antiarthritic effect. In this present study, the results indicated that the quinone rich fraction of *Ardisia crispa* (QRF) induced no hepatic, renal, and splenic toxicity after 13 days of treatment. These results was based on histopathological examination on the liver, spleen and kidney of the rats which showed a non-specific mild focal inflammation in liver and kidney of the rat models. Therefore, this can be concluded that the 3mg/kg, 10mg/kg and 30mg/kg of QRF is able to exhibit antiarthritic effect without inducing toxicity on the rat models after 13 days of treatment.

## 6.2 Future Recommendation

The present study conducted was a fundamental study to identify the histopathological changes on the kidney, spleen and liver after 13 days of quinone rich fraction of *Ardisia crispera* (QRF) administration. However, the results is non-significant to indicate the toxicity of QRF. Therefore, a chronic toxicity test of QRF for longer period is suggested to confirm the safety profile of QRF. Besides, increasing the dosages of the QRF is helpful for further research in assessing the toxic dose of QRF. Furthermore, an extensive analysis can be carried out to investigate the background lesion observed in the liver and spleen of the rat models. Moreover, other organs such as brain heart and stomach can be used to evaluate and confirm the safety dosages of *Ardisia crispera*.

## REFERENCES

- Aldahmash, B. A., & El-Nagar, D. M. (2016). Antioxidant effects of captopril against lead acetate-induced hepatic and splenic tissue toxicity in Swiss albino mice. *Saudi journal of biological sciences*, 23(6), 667–673. <https://doi.org/10.1016/j.sjbs.2016.05.005>
- Aletaha, D., & Smolen, J. S. (2018). Diagnosis and management of rheumatoid arthritis: a review. *Jama*, 320(13), 1360-1372.
- Alexandra Sieroslawska. (2020, August 31). How to examine histology slides. Retrieved from <https://www.kenhub.com/en/library/learning-strategies/how-to-examine-a-histology-slide>
- Arthritic Foundation. (2021). How rheumatoid arthritis affects more than joints. Retrieved from <https://www.arthritis.org/diseases/more-about/how-rheumatoid-arthritis-affects-more-than-joints>
- Asyura, S. N., Hamzah, H., Shaari, R. M., Sithambaram, S., & Mustapha, N. M. (2016). Blood profiles and histopathological changes of liver and kidney tissues from male sprague dawley rats treated with ethanol extracts of *Clinacanthus nutans* leaf. *J Clin Toxicol*, 6(329), 2161-0495.
- Benjamin, O., Bansal, P., Goyal, A., & Lappin, S. L. (2020). Disease Modifying Anti-Rheumatic Drugs (DMARD). In *StatPearls*. StatPearls Publishing.
- Blin, J. A., Ali, R. M., Nurdin, A., & Abd Hamid, R. (2021). Quinone-rich fraction of *Ardisia crispera* (Thunb.) A. DC roots alters angiogenic cascade in collagen-induced arthritis. *Inflammopharmacology*, 1-18.
- Blin, J. A., Hamid, R. A., & Khaza'ai, H. (2021). Bioactive fractions and compound of *Ardisia crispera* roots exhibit anti-arthritic properties mediated via angiogenesis inhibition in vitro. *BMC Complementary Medicine and Therapies*, 21(1), 1-16.
- Bolton, J. L., Trush, M. A., Penning, T. M., Dryhurst, G., & Monks, T. J. (2000). Role of quinones in toxicology. *Chemical research in toxicology*, 13(3), 135–160. <https://doi.org/10.1021/tx9902082>
- Brand, D. D., Latham, K. A., & Rosloniec, E. F. (2007). Collagen-induced arthritis. *Nature protocols*, 2(5), 1269.
- Brzoska, M. M., Moniuszko-Jakoniuk, J., Piłat-Marcinkiewicz, B., & Sawicki, B. (2003). Liver and kidney function and histology in rats exposed to cadmium and ethanol. *Alcohol and Alcoholism*, 38(1), 2-10.
- Bullock, J., Rizvi, S., Saleh, A. M., Ahmed, S. S., Do, D. P., Ansari, R. A., & Ahmed, J. (2018). Rheumatoid Arthritis: A Brief Overview of the Treatment. *Medical*

*principles and practice : international journal of the Kuwait University, Health Science Centre*, 27(6), 501–507. <https://doi.org/10.1159/000493390>

Burkill, I. H. (1966). A Dictionary of The Economic Product of The Malay Peninsula Vol II. *Art Printing Works, Malaysia*, 976.

CDC. (2020). Arthritis. Retrieved from <https://www.cdc.gov/arthritis/basics/faqs.htm>

Chatterjee S. (2014). Artefacts in histopathology. *Journal of oral and maxillofacial pathology : JOMFP*, 18(Suppl 1), S111–S116. <https://doi.org/10.4103/0973-029X.141346>

Chaweewan J., Herbert B., Lennart K. and Gunnar S. Ardisiacrispin A and B, Two utero-contracting Saponins from *Ardisia crispa*. *Planta Med.* 53(5): 405-409 (1987)

Chen, L., Deng, H., Cui, H., Fang, J., Zuo, Z., Deng, J., Li, Y., Wang, X., & Zhao, L. (2017). Inflammatory responses and inflammation-associated diseases in organs. *Oncotarget*, 9(6), 7204–7218. <https://doi.org/10.18632/oncotarget.23208>

Chopra, D., Gulati, M., Singh, S., Duggal, S., & Kumar, R. (2008). Use of liposomal drugs in the treatment of rheumatoid arthritis. *Current Rheumatology Reviews*, 4(1), 63-70.

Christophe W. (2002). *Medical Plants of Southeast Asia*. Selangor. Prentice Hall.

Conway, R., & Carey, J. J. (2017). Risk of liver disease in methotrexate treated patients. *World journal of hepatology*, 9(26), 1092–1100. <https://doi.org/10.4254/wjh.v9.i26.1092>

Crissman, J. W., Goodman, D. G., Hildebrandt, P. K., Maronpot, R. R., Prater, D. A., Riley, J. H., ... & Thake, D. C. (2004). Best practices guideline: toxicologic histopathology. *Toxicologic pathology*, 32(1), 126-131.

Crofford L. J. (2013). Use of NSAIDs in treating patients with arthritis. *Arthritis research & therapy*, 15 Suppl 3(Suppl 3), S2. <https://doi.org/10.1186/ar4174>

De Jong, W. H., & Van Loveren, H. (2007). Screening of xenobiotics for direct immunotoxicity in an animal study. *Methods*, 41(1), 3-8.

Dey, S. K., Hira, A., Howlader, M. S. I., Ahmed, A., Hossain, H., & Jahan, I. A. (2014). Antioxidant and antidiarrheal activities of ethanol extract of *Ardisia elliptica* fruits. *Pharmaceutical biology*, 52(2), 213-220.

Ferrell L. (2000). Liver pathology: cirrhosis, hepatitis, and primary liver tumors. Update and diagnostic problems. *Modern pathology : an official journal of the United States and Canadian Academy of Pathology, Inc*, 13(6), 679–704. <https://doi.org/10.1038/modpathol.3880119>

- Fifi S. I. (2013). Subchronic toxicity study of *Ardisia crispa* root hexane extract in mice. (Unpublished Bachelor Dissertation). Universiti Putra Malaysia.
- Frazier, K. S., Seely, J. C., Hard, G. C., Betton, G., Burnett, R., Nakatsuji, S., Nishikawa, A., Durchfeld-Meyer, B., & Bube, A. (2012). Proliferative and Nonproliferative Lesions of the Rat and Mouse Urinary System. *Toxicologic Pathology*, 40(4\_suppl), 14S-86S. <https://doi.org/10.1177/0192623312438736>
- Gerards, A. H., de Lathouder, S., de Groot, E. R., Dijkmans, B. A., & Aarden, L. A. (2003). Inhibition of cytokine production by methotrexate. Studies in healthy volunteers and patients with rheumatoid arthritis. *Rheumatology (Oxford, England)*, 42(10), 1189–1196. <https://doi.org/10.1093/rheumatology/keg323>
- Gibson-Corley, K. N., Olivier, A. K., & Meyerholz, D. K. (2013). Principles for valid histopathologic scoring in research. *Veterinary pathology*, 50(6), 1007–1015. <https://doi.org/10.1177/0300985813485099>
- Guo, Q., Wang, Y., Xu, D., Nossent, J., Pavlos, N. J., & Xu, J. (2018). Rheumatoid arthritis: pathological mechanisms and modern pharmacologic therapies. *Bone research*, 6, 15. <https://doi.org/10.1038/s41413-018-0016-9>
- Gurcan, M. N., Boucheron, L. E., Can, A., Madabhushi, A., Rajpoot, N. M., & Yener, B. (2009). Histopathological image analysis: a review. *IEEE reviews in biomedical engineering*, 2, 147–171. <https://doi.org/10.1109/RBME.2009.2034865>
- Hall WC, Ganaway JR, Rao GN, Peters RL, Allen AM, Luczak JW, Sandberg EM, Quigley BH. 1992. Histopathologic observations in weanling B6C3F1 mice and F344/N rats and their adult parental strains. *Toxicol Pathol* 20:146–154.
- Halliday, P. (1984). *Myrsinaceae*. Taylor & Francis
- Hamid, R. A., Fong, L. M., & Ting, Y. L. (2017). Anti-arthritic and gastroprotective activities of *Ardisia crispa* root partially mediated via its antioxidant effect. *Journal of complementary & integrative medicine*, 15(1), /j/jcim.2018.15.issue-1/jcim-2017-0012/jcim-2017-0012.xml. <https://doi.org/10.1515/jcim-2017-0012>
- Hamid, R. A., Othman, F., Anthony, J. J., & Ting, Y. L. (2013). Chemopreventive effect of *Ardisia crispa* hexane fraction on the peri-initiation phase of mouse skin tumorigenesis. *Medical principles and practice : international journal of the Kuwait University, Health Science Centre*, 22(4), 357–361. <https://doi.org/10.1159/000346622>
- Hamsin, D. E. Z. A., Hamid, R. A., Yazan, L. S., Taib, C. N. M., & Yeong, L. T. (2014). *Ardisia crispa* roots inhibit cyclooxygenase and suppress angiogenesis. *BMC complementary and alternative medicine*, 14(1), 1-9.

- Hamsin, D.E.Z.A., Hamid, R.A., Yazan, L.S. *et al.* The hexane fraction of *Ardisia crispa* Thunb. A. DC. roots inhibits inflammation-induced angiogenesis. *BMC Complement Altern Med* 13, 5 (2013). <https://doi.org/10.1186/1472-6882-13-5>
- Howard R Smith. (Mar 05, 2021). Rheumatoid Arthritis (RA) Treatment & Management.
- Jamie Crawford. How does RA affect different part of the body? (2018, September 18). Retrieved from <https://www.medicalnewstoday.com/articles/323095>
- Jindal, H. M. K., & Mohamad, J. (2012). Antioxidant activity of *Ardisia crispa* (Mata pelanduk). *Sains Malaysiana*, 41(5), 539-545.
- John C. S. and Amy B. (October 28, 2014). NTP Noneoplastic Lesion Atlas. Kidney, Interstitium – Infiltration, Cellular. Retrieved from [https://ntp.niehs.nih.gov/nl/urinary/kidney/ininfiltr/kidney-interstitium-infiltration-cellular-pdf\\_508.pdf](https://ntp.niehs.nih.gov/nl/urinary/kidney/ininfiltr/kidney-interstitium-infiltration-cellular-pdf_508.pdf)
- Joseph, R. M., Hunter, A. L., Ray, D. W., & Dixon, W. G. (2016, August). Systemic glucocorticoid therapy and adrenal insufficiency in adults: a systematic review. In *Seminars in arthritis and rheumatism* (Vol. 46, No. 1, pp. 133-141). WB Saunders.
- Jun, L. W., Foong, C. P., & Abd Hamid, R. (2019). *Ardisia crispa* root hexane fraction suppressed angiogenesis in human umbilical vein endothelial cells (HUVECs) and in vivo zebrafish embryo model. *Biomedicine & Pharmacotherapy*, 118, 109221.
- Kamal, J., & Baldi, A. (2015). Approaches to overcome NSAID induced ulceration in arthritic pain management: Perspectives and prospects. *Journal of Drug Delivery and Therapeutics*, 5(2), 9-16.
- Kang, Y. H., Kim, W. H., Park, M. K., & Han, B. H. (2001). Antimetastatic and antitumor effects of benzoquinonoid AC7-1 from *Ardisia crispa*. *International journal of cancer*, 93(5), 736–740. <https://doi.org/10.1002/ijc.1384>
- Klopfleisch, R. (2013). Multiparametric and semiquantitative scoring systems for the evaluation of mouse model histopathology-a systematic review. *BMC veterinary research*, 9(1), 1-15.
- Kobayashi, H., & De Mejía, E. (2005). The genus *Ardisia*: a novel source of health-promoting compounds and phytopharmaceuticals. *Journal of Ethnopharmacology*, 96(3), 347-354.
- Kristeen Cherney. Effects of Rheumatoid Arthritis on the body. (2019, November 26). Retrieved from <https://www.healthline.com/health/rheumatoid-arthritis/effects-on-body>

- Lee, J. Ann (2016, January 21). *Measurement scale*. *Encyclopedia Britannica*. <https://www.britannica.com/topic/measurement-scale>
- Lemley, K. V., & Kriz, W. (1991). Anatomy of the renal interstitium. *Kidney international*, 39(3), 370-381.
- LibreTexts. Organ Toxicity. (2021, January 4). Retrieved from <https://bio.libretexts.org/@go/page/11949>
- Mann, P. C., Vahle, J., Keenan, C. M., Baker, J. F., Bradley, A. E., Goodman, D. G., ... & Tanaka, T. (2012). International harmonization of toxicologic pathology nomenclature: an overview and review of basic principles. *Toxicologic pathology*, 40(4\_suppl), 7S-13S.
- Matthews, N. L. (2017). Measurement, Levels Of. *The International Encyclopedia of Communication Research Methods*, 1-7.
- Meyerholz, D. K., & Beck, A. P. (2018). Principles and approaches for reproducible scoring of tissue stains in research. *Laboratory investigation*, 98(7), 844-855.
- Monks, T. J., & Jones, D. C. (2002). The metabolism and toxicity of quinones, quinonimines, quinone methides, and quinone-thioethers. *Current drug metabolism*, 3(4), 425-438.
- Nagagi, Y.P., Silayo, R.S., Luziga, C. *et al.* In vivo effect of *Commiphora swynnertonii* ethanolic extracts on *Trypanosoma congolense* and selected immunological components in mice. *BMC Complement Altern Med* 17, 275 (2017). <https://doi.org/10.1186/s12906-017-1785-1>
- National Center for Biotechnology Information (2021). PubChem Compound Summary for CID 4650, 1,4-Benzoquinone. Retrieved May 4, 2021 from [https://pubchem.ncbi.nlm.nih.gov/compound/1\\_4-Benzoquinone](https://pubchem.ncbi.nlm.nih.gov/compound/1_4-Benzoquinone).
- National Kidney Foundation. How Your Kidney Work. (2021). Retrieved from <https://www.kidney.org/kidneydisease/howkidneyswrk>
- NCIthesaurus. Focal acute inflammation. (April 26, 2021) Retrieved from <https://www.ncbi.nlm.nih.gov/medgen/226827#Definition>
- Nigatu, T. A., Afework, M., Urga, K., Ergete, W., & Makonnen, E. (2017). Toxicological investigation of acute and chronic treatment with *Gnidia stenophylla* Gilg root extract on some blood parameters and histopathology of spleen, liver and kidney in mice. *BMC research notes*, 10(1), 625. <https://doi.org/10.1186/s13104-017-2964-3>
- Nordin, M. L., Abdul Kadir, A., Zakaria, Z. A., Othman, F., Abdullah, R., & Abdullah, M. N. H. (2017). Cytotoxicity and apoptosis induction of *Ardisia crispa* and its solvent partitions against *Mus musculus* mammary carcinoma cell line (4T1). *Evidence-Based Complementary and Alternative Medicine*, 2017.

- Nordin, M.L., Abdul Kadir, A., Zakaria, Z.A. *et al.* In vitro investigation of cytotoxic and antioxidative activities of *Ardisia crispa* against breast cancer cell lines, MCF-7 and MDA-MB-231. *BMC Complement Altern Med* 18, 87 (2018). <https://doi.org/10.1186/s12906-018-2153-5>
- Padher, S., & Bhalekar, M. R. (2018). Natural remedies for rheumatoid arthritis.
- Pahwa, R., Goyal, A., Bansal, P., & Jialal, I. (2020). Chronic Inflammation. In *StatPearls*. StatPearls Publishing.
- Plant Rescue. (2010-2019). *Ardisia crenata*. Retrieved from <http://www.plantsrescue.com/tag/ardisia-crenata/>
- Plants for a Future. (2010-2021). *Ardisia crispa* - (Thunb.)A.DC. Retrieved from <https://pfaf.org/user/Plant.aspx?LatinName=Ardisia+crispa>
- Plants of the World online. (2017). *Ardisia crispa*. Retrieved from <http://www.plantsoftheworldonline.org/taxon/urn:lsid:ipni.org:names:586896-1>
- Qureshi, A., Loya, A., Azam, M., Hussain, M., Mushtaq, S., & Mahmood, T. (2012). Study of parameters to ensure quality control in histopathology reporting: a meta-analysis at a tertiary care center. *Indian journal of pathology & microbiology*, 55(2), 180–182. <https://doi.org/10.4103/0377-4929.97857>
- Rastogi A. (2018). Changing role of histopathology in the diagnosis and management of hepatocellular carcinoma. *World journal of gastroenterology*, 24(35), 4000–4013. <https://doi.org/10.3748/wjg.v24.i35.4000>
- Robert R. Maronpot. (June 19, 2014). NTP Noneoplastic Lesion Atlas. Retrieved from [https://ntp.niehs.nih.gov/nl/hepatobiliary/liver/inflamm/liver-inflammation\\_508.pdf](https://ntp.niehs.nih.gov/nl/hepatobiliary/liver/inflamm/liver-inflammation_508.pdf)
- Roslida, A. H. (2004). Anti-inflammatory and analgesic effects of AC-2 isolated from *Ardisia crispa* are mediated via COX-2 inhibition. *Kuala Lumpur, Malaysia: PhD thesis, Universiti Malaya, Physiology Department*.
- Roslida, A., & Kim, K. (2008). Anti-inflammatory and anti-hyperalgesic effects of *Ardisia crispa* Thunb. DC. *Pharmacognosy Magazine*, 4(16), 262.
- Rubin, R., Strayer, D. S., & Rubin, E. (Eds.). (2008). *Rubin's pathology: clinicopathologic foundations of medicine*. Lippincott Williams & Wilkins.
- Ruehl-Fehlert, C., Kittel, B., Morawietz, G., Deslex, P., Keenan, C., Mahrt, C. R., ... & Deschl, U. (2003). Revised guides for organ sampling and trimming in rats and mice—part 1: a joint publication of the RITA and NACAD groups. *Experimental and Toxicologic Pathology*, 55(2-3), 91-106.

- Safiri, S., Kolahi, A. A., Hoy, D., Smith, E., Bettampadi, D., Mansournia, M. A., ... & Cross, M. (2019). Global, regional and national burden of rheumatoid arthritis 1990–2017: a systematic analysis of the Global Burden of Disease study 2017. *Annals of the rheumatic diseases*, 78(11), 1463-1471.
- Sang, X., Zheng, L., Sun, Q., Li, N., Cui, Y., Hu, R., Gao, G., Cheng, Z., Cheng, J., Gui, S., Liu, H., Zhang, Z., & Hong, F. (2012). The chronic spleen injury of mice following long-term exposure to titanium dioxide nanoparticles. *Journal of biomedical materials research. Part A*, 100(4), 894–902. <https://doi.org/10.1002/jbm.a.34024>
- Sellers, R. S., Mortan, D., Michael, B., Roome, N., Johnson, J. K., Yano, B. L., ... & Schafer, K. (2007). Society of Toxicologic Pathology position paper: organ weight recommendations for toxicology studies. *Toxicologic pathology*, 35(5), 751-755.
- Seoane, J., Varela-Centelles, P. I., Ramírez, J. R., Cameselle-Teijeiro, J., & Romero, M. A. (2004). Artefacts in oral incisional biopsies in general dental practice: a pathology audit. *Oral diseases*, 10(2), 113–117. <https://doi.org/10.1111/j.1354-523x.2003.00983.x>
- Shackelford, C., Long, G., Wolf, J., Okerberg, C., & Herbert, R. (2002). Qualitative and quantitative analysis of nonneoplastic lesions in toxicology studies. *Toxicologic pathology*, 30(1), 93–96. <https://doi.org/10.1080/01926230252824761>
- Shahinozzaman, M., Ishii, T., Halim, M. A., Hossain, M. A., Islam, M. T., & Tawata, S. (2019). Cytotoxic and anti-inflammatory resorcinol and alkylbenzoquinone derivatives from the leaves of *Ardisia sieboldii*. *Zeitschrift für Naturforschung C*, 74(11-12), 303-311.
- Shott, S. (2011). Designing studies that answer questions. *Journal of the American Veterinary Medical Association*, 238(1), 55-58.
- Sikandar, A., Cheema, A. H., Younus, M., Aslam, A., Zaman, M. A., & Rehman, T. (2012). Histopathological and serological studies on paratuberculosis in cattle and buffaloes. *Pak. Vet. J*, 32(4), 547-551.
- Sizova, E., Glushchenko, N., Miroshnikov, S., & Skalny, A. (2011). Influence of Cu10x copper nanoparticles intramuscular injection on mineral composition of rat spleen. *Journal of trace elements in medicine and biology : organ of the Society for Minerals and Trace Elements (GMS)*, 25 Suppl 1, S84–S89. <https://doi.org/10.1016/j.jtemb.2010.10.012>
- Slaoui, M., & Fiette, L. (2011). Histopathology procedures: from tissue sampling to histopathological evaluation. In *Drug safety evaluation* (pp. 69-82). Humana Press.
- Smith, H. R. (2020, Feb 07). *Rheumatoid Arthritis (RA)*. Retrieved from <https://emedicine.medscape.com/article/331715-overview>

- Society of Toxicologic Pathology. (2021). Standardized System of Nomenclature and Diagnostic Criteria (SSNDC) Guide. Retrieved from <https://www.toxpath.org/ssndc.asp>
- Soldatow, V. Y., Lecluyse, E. L., Griffith, L. G., & Rusyn, I. (2013). *In vitro* models for liver toxicity testing. *Toxicology research*, 2(1), 23–39. <https://doi.org/10.1039/C2TX20051A>
- Spies, C. M., Bijlsma, J. W., Burmester, G.-R., & Buttgerit, F. (2010). *Pharmacology of glucocorticoids in rheumatoid arthritis*. *Current Opinion in Pharmacology*, 10(3), 302–307. doi:10.1016/j.coph.2010.02.001
- Stevens S. S. (1946). On the Theory of Scales of Measurement. *Science (New York, N.Y.)*, 103(2684), 677–680. <https://doi.org/10.1126/science.103.2684.677>
- Stramer, B. M., Mori, R., & Martin, P. (2007). The inflammation–fibrosis link? A Jekyll and Hyde role for blood cells during wound repair. *Journal of Investigative Dermatology*, 127(5), 1009-1017.
- Taqi, S. A., Sami, S. A., Sami, L. B., & Zaki, S. A. (2018). A review of artifacts in histopathology. *Journal of oral and maxillofacial pathology : JOMFP*, 22(2), 279. [https://doi.org/10.4103/jomfp.JOMFP\\_125\\_15](https://doi.org/10.4103/jomfp.JOMFP_125_15)
- Tchetverikov, I., Kraan, M. C., van El, B., Hanemaaijer, R., DeGroot, J., & Huizinga, T. W. (2008). Leflunomide and methotrexate reduce levels of activated matrix metalloproteinases in complexes with alpha2 macroglobulin in serum of rheumatoid arthritis patients. *Annals of the rheumatic diseases*, 67(1), 128–130. <https://doi.org/10.1136/ard>.
- Teh, J. K., Tey, N. P., & Ng, S. T. (2014). Ethnic and gender differentials in non-communicable diseases and self-rated health in Malaysia. *PloS one*, 9(3), e91328. <https://doi.org/10.1371/journal.pone.0091328>
- Temperate Plants Database. (2021, January 30). *Ardisia crispa*. Retrieved from <http://temperate.theferns.info/plant/Ardisia+crispa>
- The Royal College of Pathologists. (2020). Histopathology. Retrieved from <https://www.rcpath.org/discover-pathology/news/fact-sheets/histopathology.html>
- Thoolen, B., Maronpot, R. R., Harada, T., Nyska, A., Rousseaux, C., Nolte, T., Malarkey, D. E., Kaufmann, W., Küttler, K., Deschl, U., Nakae, D., Gregson, R., Vinlove, M. P., Brix, A. E., Singh, B., Belpoggi, F., & Ward, J. M. (2010). Proliferative and nonproliferative lesions of the rat and mouse hepatobiliary system. *Toxicologic pathology*, 38(7 Suppl), 5S–81S. <https://doi.org/10.1177/0192623310386499>

- Van Linthout, S., Miteva, K., & Tschöpe, C. (2014). Crosstalk between fibroblasts and inflammatory cells. *Cardiovascular research*, *102*(2), 258-269.
- Vercruyse, V., & Van Hoe, L. (2017). Eosinophilic Liver Disease Mimicking Hepatic Metastases. *Journal of the Belgian Society of Radiology*, *101*(1), 18. <https://doi.org/10.5334/jbr-btr.1235>
- Weinblatt, M. E., Keystone, E. C., Furst, D. E., Moreland, L. W., Weisman, M. H., Birbara, C. A., Teoh, L. A., Fischkoff, S. A., & Chartash, E. K. (2003). Adalimumab, a fully human anti-tumor necrosis factor alpha monoclonal antibody, for the treatment of rheumatoid arthritis in patients taking concomitant methotrexate: the ARMADA trial. *Arthritis and rheumatism*, *48*(1), 35-45. <https://doi.org/10.1002/art.10697>
- William M.K. Trochim. (2020). Level of Measurement. Retrieved from <https://conjointly.com/kb/levels-of-measurement/>
- Yeong, L. T., Hamid, R. A., Yazan, L. S., & Khaza'ai, H. (2013). Isolation of a quinone-rich fraction from *Ardisia crispa* roots and its attenuating effects on murine skin tumorigenesis. *Asian Pacific Journal of Cancer Prevention*, *14*(4), 2301-2305.
- Yeong, L. T., Hamid, R. A., Yazan, L. S., Khaza'ai, H., & Mohtarrudin, N. (2015). Low dose triterpene-quinone fraction from *Ardisia crispa* root precludes chemical-induced mouse skin tumor promotion. *BMC complementary and alternative medicine*, *15*(1), 1-11.
- Youssef, J., Novosad, S. A., & Winthrop, K. L. (2016). Infection Risk and Safety of Corticosteroid Use. *Rheumatic diseases clinics of North America*, *42*(1), 157-x. <https://doi.org/10.1016/j.rdc.2015.08.004>
- Zaiontz, C. (2014). Assumption for Statistical Tests. Retrieved from <https://www.real-statistics.com/descriptive-statistics/assumptions-statistical-test/>
- Zeisberg, M., & Kalluri, R. (2015). Physiology of the Renal Interstitium. *Clinical journal of the American Society of Nephrology : CJASN*, *10*(10), 1831-1840. <https://doi.org/10.2215/CJN.00640114>

## APPENDICES A



PEJABAT TIMBALAN NAIB CANSOLOR (PENYELIDIKAN DAN INOVASI)  
OFFICE OF THE DEPUTY VICE CHANCELLOR (RESEARCH AND INNOVATION)

### INSTITUTIONAL ANIMAL CARE AND USE COMMITTEE

Date: 11 March 2016  
Ref.: UPM/IACUC/AUP- R092/2015  
Project Title: Elucidation of Mechanism of Anti-Arthritic Action of Benzoquinone Isolated From *Ardisia crisper* Root, In Sprague Dawley Rats  
Principal Investigator: Prof. Madya Dr. Roslida binti Abdul Hamid @ Abdul Razak  
Associates: Prof. Madya Dr. Cheah Yoke Kqueen  
Student: Joan Anak Blin  
Committee Decision: The committee has reviewed and approved the proposed animal utilization protocol  
AUP No.: R092/2015  
Project Classification: Chronic  
Category of Invasiveness: C  
Source of Animals: A Sapphire Enterprise, 22 Jalan Indah 2/8, Taman Universiti Indah, 43300 Seri Kembangan, Selangor.  
Number of Animals Approved: 54 Rats  
Accommodation: Animal House, Faculty Medicine and Health Science  
Duration: 1 April 2016 – 31 March 2017

(PROF. DR. MOHD HAIR BEJO)  
Chairman  
Institutional Animal Care and Use Committee  
Universiti Putra Malaysia

✉ Pejabat Timbalan Naib Canselor (Penyelidikan dan Inovasi), Universiti Putra Malaysia, 43400 UPM Serdang, Selangor Darul Ehsan, Malaysia  
Pejabat Timbalan Naib Canselor (P&I) ☎ 603-8947 1293 📠 603-8945 1646, Pejabat Pentadbiran TNCPI ☎ 603-8947 1608 📠 603-8945 1673,  
Pejabat Pengarah, Pusat Pengurusan Penyelidikan (RMC) ☎ 603-8947 1601 📠 603-8945 1596, Pejabat Pengarah, Putra Science Park (PSP)  
☎ 603-8947 1291 📠 603-8946 4121 🌐 <http://www.tncpi.upm.edu.my>

## APPENDICES B

Table: Raw data of liver evaluation (Note: normal (0) = 0; mild (1) = 1%-30%; moderate (2) = 31%-70% and severe (3) = >70%)

Treatment (mg/kg)	Mouse	Parameter		
		Inflammation	Necrosis	Fibrosis
Vehicle control	1	0	0	0
	2	1	0	0
	3	0	0	0
	4	0	0	0
	5	1	0	0
Arthritic control	1	0	0	0
	2	0	0	0
	3	1	0	0
	4	0	0	0
	5	1	0	0
3	1	1	0	0
	2	0	0	0
	3	1	0	0
	4	0	0	0
	5	0	0	0

10	1	1	0	0
	2	1	0	0
	3	0	0	0
	4	1	0	0
	5	0	0	0
30	1	0	0	0
	2	1	0	0
	3	1	0	0
	4	0	0	0
	5	0	0	0

Table: Raw data of kidney evaluation (Note: normal (0) = 0; mild (1) = 1%-30%; moderate (2) = 31%-70% and severe (3) = >70%)

Treatment (mg/kg)	Mouse	Parameter		
		Inflammation	Necrosis	Hydropic degeneration
Vehicle control	1	0	0	0
	2	0	0	0
	3	0	0	0
	4	0	0	0
	5	0	0	0
Arthritic control	1	0	0	0
	2	0	0	0
	3	0	0	0
	4	0	0	0
	5	0	0	0
3	1	0	0	0
	2	0	0	0
	3	0	0	0
	4	1	0	0
	5	0	0	0
10	1	0	0	0
	2	0	0	0
	3	0	0	0
	4	0	0	0
	5	0	0	0

30	1	0	0	0
	2	1	0	0
	3	0	0	0
	4	0	0	0
	5	0	0	0



© COPYRIGHT UPM

Table: Raw data of spleen evaluation (Note: normal (0) = 0; mild (1) = 1%-30%; moderate (2) = 31%-70% and severe (3) = >70%)

Treatment (mg/kg)	Mouse	Parameter			
		Inflammation	Necrosis	Lymphoid necrosis	Red pulp expansion
Vehicle control	1	0	0	0	0
	2	0	0	0	0
	3	0	0	0	0
	4	0	0	0	0
	5	0	0	0	0
Arthritic control	1	0	0	0	0
	2	0	0	0	0
	3	0	0	0	0
	4	0	0	0	0
	5	0	0	0	0
3	1	0	0	0	0
	2	0	0	0	0
	3	0	0	0	0
	4	0	0	0	0
	5	0	0	0	0

10	1	0	0	0	0
	2	0	0	0	0
	3	0	0	0	0
	4	0	0	0	0
	5	0	0	0	0
30	1	0	0	0	0
	2	0	0	0	0
	3	0	0	0	0
	4	0	0	0	0
	5	0	0	0	0